Review article

POCUS use in Acute Hospital at Home – working through clinical presentations and addressing management questions

A Broad, T Knight, S Kiani, N Rajaiah, S Clare & D Lasserson

Abstract

Point of care ultrasound (POCUS) is increasing in use and popularity as the technology advances and understanding deepens. For many specialities such as Acute Internal Medicine and Emergency Medicine, POCUS is now mandated in the curriculum. The benefits of POCUS have been identified in multiple settings however currently there is little literature focusing on POCUS in the acute community setting as seen in Hospital at Home (HaH) and there is no formal framework for POCUS in HaH. As a result, the development and safety of this modality is at potential risk. Through adaptation of established protocols and accreditation pathways this could easily be addressed benefiting the patients care foremost, the clinician and the National Health Service as a whole.

Keywords

Point of Care Ultrasound, Hospital at Home, Acute Community Care

Introduction

Point of care ultrasound (POCUS) has steadily grown in use and popularity in Hospital as probes have become more portable and the understanding of the benefits of POCUS deepen as education improves. The recent change in the Acute Internal Medicine curriculum to include mandatory training for POCUS is evidence of the change in attitude to POCUS from special skill to core skill for clinical practice.[1] POCUS also has many uses within community settings either in pre-hospital medicine or within primary care/family medicine. Within the primary care setting however POCUS tends to be used for non-acute services and there is very little literature looking at use of POCUS in acute community settings such as 'Hospital at Home' where services deliver hospital level care outside of the acute hospital environment.[2] In the few studies that have been carried out, when ultrasound has been used by those with limited training in a protocol driven manner, accuracy has been up to 95% when compared to clinical assessment, standard ultrasound or other imaging with high efficacy in improving patient care.[2]

Hospital at Home (HaH) is a care model where hospital level assessment and treatment are given in the home or care home. Compared with traditional community-based services, HaH delivers interventions for higher acuity conditions and can include intravenous antibiotics, fluids and diuretics all in the place that patients call home.[3] This model works particularly well for selected older and frail patients in whom hospital admission poses a much higher risk. Evidence from a large, randomised trial showed that managing acute illness in older adults living with frailty outside hospital is both clinically and cost effective.[4, 5]

Point of care diagnostics are increasingly becoming part of HaH including POCUS.[6] Given the on-going pressures on the front door services and lack of acute care beds these innovative ways to treat acute patients in the community help provide additional capacity beyond the inpatient bed base. Successful treatment outside hospital reduces the risks associated with hospital admission for a vulnerable population including hospital-acquired infection, functional de-conditioning, falls and delirium which can outweigh the benefits of admission. Where admission is required, POCUS can ensure a patient is admitted directly to the appropriate specialty, bypassing the Emergency Department completely.[7]

For 'front door' physicians including Emergency Medicine, Acute Medicine and Intensivists there are standardised, robust protocols and accreditation

Amy Broad[1]

Thomas Knight[1,2]

Sharjeel Kiani[1]

Nithyananda Rajaiah[1]

Sarbjit Clare[1]

Daniel Lasserson[1,3,4]

[1] Department of Acute Medicine, Sandwell and West Birmingham NHS Trust
[2] Birmingham Acute Care Research, University of Birmingham
[3] Warwick Applied Health, Warwick Medical School, University of Warwick
[4] Acute Hospital at Home, Department of Geratology, Oxford University Hospitals NHS Foundation Trust

Correspondence
Amy Broad
Email: amy.broad2@nhs.net

© 2024 Rila Publications Ltd.

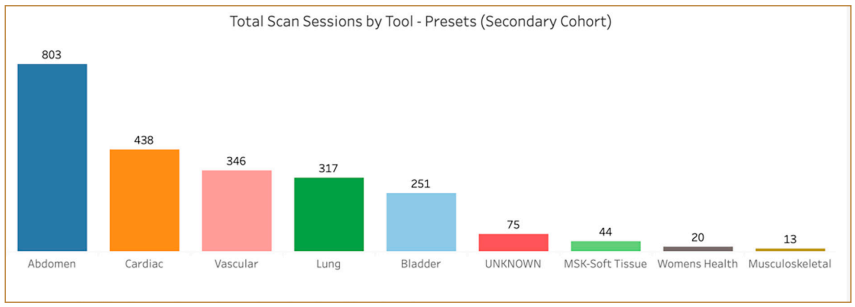

Figure 1.1. Oxford University Hospital NHS Foundation Trust (OUH) HaH scans by type over past 3 years

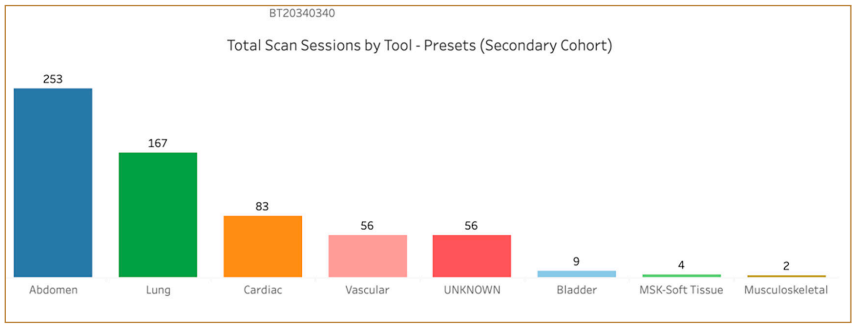

Figure 1.2. Sandwell and West Birmingham NHS Trust (SWB) HaH scans by type over past 3 years

pathways that demonstrate how POCUS can and should be used in each speciality. Examples of this are the Focussed Acute Medical Ultrasound Society (FAMUS) and Focused Ultrasound for Intensive Care (FUSIC) accreditation pathways which have been produced to reflect the common presentations that are seen in each speciality and adjusted accordingly to ensure POCUS is used appropriately and most effectively.[8, 9] Instead of a one size fits all approach POCUS use is adapted to the specific need.

Whilst there are emerging use cases for POCUS in HaH from early adopters who are applying hospitalist approaches to diagnostics in the home, there is currently no established clinical heuristic or set of algorithms for POCUS in acute internal medicine outside of the hospital. This paper aims to examine the multiple presentations in which POCUS can be used in HaH to help aid diagnosis, treatment and monitoring.

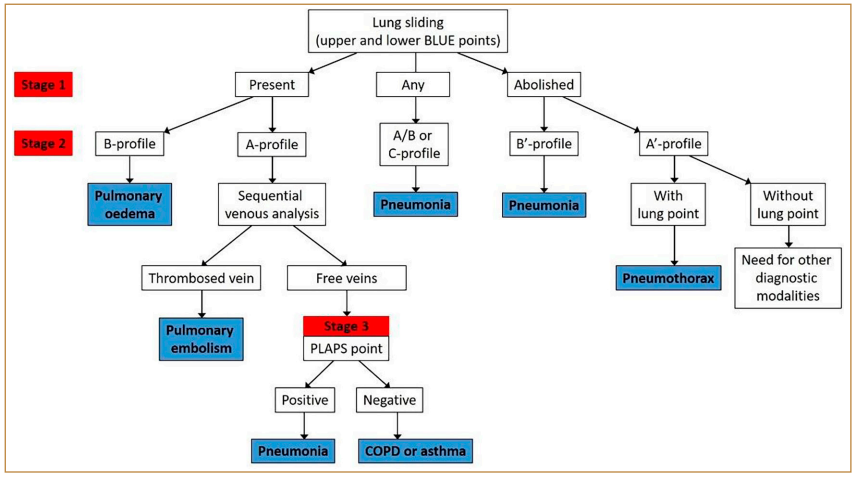

Figure 2.1. The BLUE Protocol. Adapted from Lichenstein and Mezière, 2008.

Overview of Butterfy iQ+ presets in two HaH services

Figures 1.1 and 1.2 display the ways ultrasound is being utilised in two POCUS enabled HaH services, with abdomen, lung, vascular and cardiac settings being the commonest in both services. These settings cover the common clinical presentations and the common clinical management questions outlined below.

Common clinical questions in Hospital at Home

1. What is the cause of breathlessness?
2. What's the most likely cause of this patients collapse?
3. What is the cause of abdominal swelling?
4. What may have contributed to this patient's functional decline?
5. What is driving this patients' leg swelling?

1. What is the cause of breathlessness?

In the case of breathlessness, POCUS can differentiate between pulmonary and cardiac causes. It can distinguish between common pathologies and is known to be more sensitive at identifying effusions, pulmonary oedema and consolidation when compared to chest x-ray.[10] This highlights its superiority in diagnostic capability when compared to more traditional imaging modalities. A normal ultrasound scan can indicate a possible pulmonary embolism (PE) when combined with a positive vascular ultrasound looking for a deep-vein-thrombosis (DVT).

The BLUE protocol (Figure 2.1) created by Lichenstein et al in 2008[11] provides an algorithm for assessing acute breathlessness with 90.5% diagnostic accuracy and is incorporated in most accreditation pathways for POCUS and could easily be adapted for use in HaH.

For investigation of cardiac causes left ventricular (LV) and right ventricular (RV) function can be assessed using focused bedside echocardiography (ECHO) as well as identifying the presence of a pericardial effusion all of which could be contributing to the patients' symptoms. The internal jugular vein can also be evaluated more closely if there is clinical evidence of raised jugular venous pressure.

2. What's the most likely cause of this patients collapse?

In the case of collapse, POCUS can be used to assess the heart looking for evidence of hypovolaemia, LV or RV function as well as for evidence of right heart strain which could indicate the presence of a PE. Furthermore, identifying the presence of a DVT can also help in supporting a clinical diagnosis of PE.

© 2024 Rila Publications Ltd.

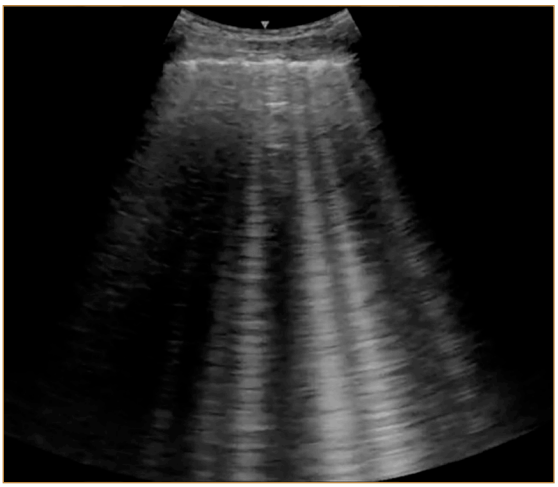

Figure 2.2. Evidence of B Lines on lung ultrasound - Vertical Lines from Pleural line indicating one cause as pulmonary oedema

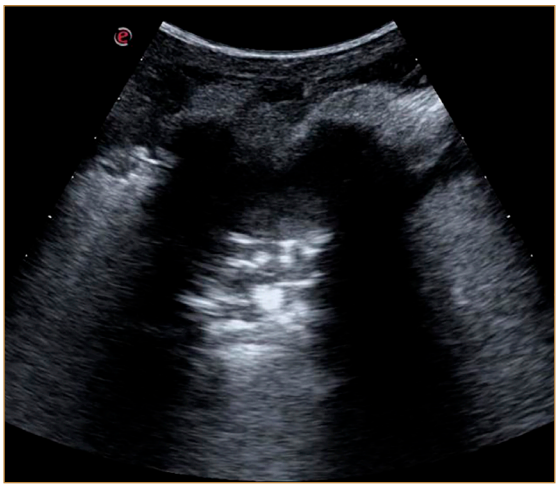

Figure 2.3. Evidence of consolidation on lung ultrasound

3. What is the cause of abdominal swelling?

The presence of ascites can help to explain abdominal swelling and can be visualised on ultrasound as a homogenous, anechoic collection. Small bowel obstruction can also be identified. In these cases, ultrasound has been shown to be superior to abdominal x-ray (AXR) in diagnosis with a specificity of 97% and sensitivity of 90%.[12]

4. What may have contributed to this patient's functional decline?

Due to the *generalised* nature of acute functional decline in the frail patient, this clinical presentation presents a considerable diagnostic challenge. However, alongside clinical assessment and point of care blood testing in hospital at home, the addition of POCUS can elucidate some of the causes. POCUS can assess for a source of infection (e.g. pneumonia), help determine fluid status, identify decompensated heart failure, rule in upper or lower urinary tract obstruction as well as venous thromboembolism.

5. What is driving this patients' leg swelling?

Leg swelling is a common presentation in the cohort of patients seen by HaH. Common causes of leg swelling can also be assessed via ultrasound and highlights the power of this modality in helping to guide diagnosis and subsequent management in the community setting. As previously mentioned, POCUS can be used to identify a DVT, as well as differentiate between subcutaneous oedema and lipodermatosclerosis. Bedside ECHO can identify evidence of heart failure enabling prompt, appropriate management of the patient in their own home.

Common management questions in Hospital at Home

Alongside diagnoses made during initial assessment, there are common clinical questions which arise in treating patients seen in HaH where POCUS can provide answers:

1. Does this patient need intravenous (IV) fluid?
2. Does this patient need escalated diuretic therapy?
3. Why does this patient have an acute kidney injury (AKI)?



Figure 3.1. Evidence of severe LVSD and dilated LV

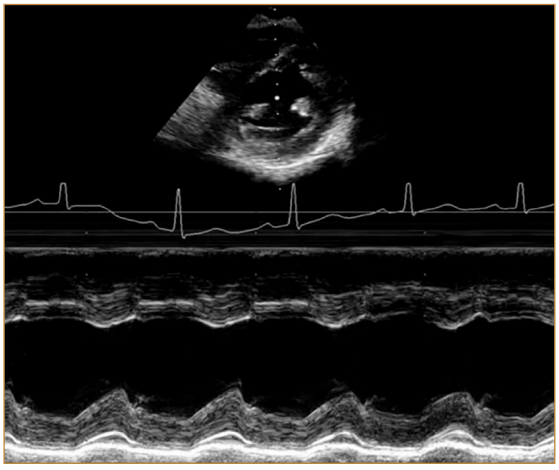

Figure 3.2. Evidence of normal LV function using m-mode on parasternal short axis view

© 2024 Rila Publications Ltd.

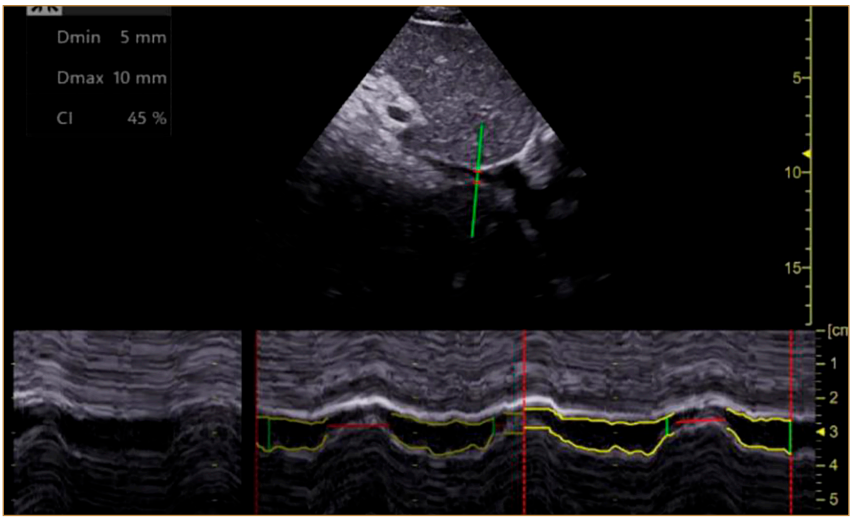

Figure 4.1. IVC showing respiratory variation. Note the IVC is small measuring at 1cm suggesting hypovolaemia

1. Does this patient need IV fluid?

When assessing a patient's fluid status key questions need to be answered relevant to any potential prescription of parenteral fluid: Is there evidence of hypovolaemia? (Figure 4.1) Is there evidence of severely impaired LV function? Is there evidence of fluid overload? Is the patient fluid tolerant? Is the patient fluid responsive? Assessing fluid responsiveness in a spontaneously breathing patient via bedside ECHO is widely debated[13] but bedside ECHO can be used to indicate if a patient is hypovolaemic and to assess LV and RV function to contribute to an overall assessment of whether IV fluids are indicated to support recovery from acute illness. Evidence of >50% collapsibility of the inferior vena cava (IVC) with a diameter <1.5cm can suggest IV fluids will be well tolerated and a hyperdynamic left ventricle or "kissing papilla"[12] indicates hypovolaemia. In contrast, if the patient is found to have a severely impaired LV with dilated IVC and evidence of pulmonary oedema on lung ultrasound this would indicate that IV fluid is likely to cause more harm due to fluid overload.



Figure 5.1. Evidence of severe hydronephrosis on abdominal ultrasound

2. Does this patient need escalated diuretic therapy?

The presence of hypervolaemia can be identified using POCUS of the lung and abdomen. In the lungs, bilateral pleural effusions and/or multiple B-lines bilaterally (which are consistent with bilateral pulmonary oedema) suggest that more effective diuresis is required. Similarly, the finding of ascites on abdominal POCUS indicates that greater diuretic action is required, either by dose increase or additional agents for sequential nephron blockade in order to achieve normovolaemia.

In this context, point of care ECHO can indicate the underlying cardiac cause and provide guidance on correct prognostic medications to optimise outcomes. An LV with impaired function, often associated with dilatation would suggest the patient is fluid overloaded due to reduced ejection fraction heart failure and early introduction of prognostic measures improves long term outcomes. Patients with a syndrome of heart failure and a normal LV ejection fraction often associated with reduced RV function or RV dilatation would suggest heart failure with preserved ejection fraction (HFpEF). Whilst a more limited range of prognostic medications are available for patients with HFpEF, early identification of correct longer-term management will improve outcomes. In addition, cloud-based POCUS imaging systems can facilitate ECHO reviews by cardiologists to support the HaH team's medical decision making, as well as identify patients who might benefit from a formal departmental ECHO.

3. Why does this patient have an acute kidney injury (AKI)?

After initial detection of AKI, further assessment is required to identify the cause to guide management, with AKI aetiology classically grouped as pre-renal, renal or post-renal. As already described, fluid status can be accurately assessed with POCUS helping to indicate if the AKI is pre-renal in nature (i.e. due to reduced blood volume or reduced effective circulating volume). Similarly abdominal ultrasound can be used to rule out post-renal causes by detecting the presence of hydronephrosis (Figure 5.1) as well as assess if the bladder is overly distended. This can give direction as to the patients' next steps in their journey: administration of IV fluids vs insertion of a catheter vs direct admission to urology if specialist input is required to relieve upper renal tract obstruction.

These common presentations and clinical questions will aid proposed training competencies specifically

© 2024 Rila Publications Ltd.

seen in HaH and help guide algorithms when using POCUS for clinical management. With the addition of ultrasound, clinicians can be empowered in their diagnoses to ensure prompt treatment helping to improve the patient's acute care journey.

POCUS and HaH – future strategies

Looking forward, it is evident that ultrasound can offer so much to the cohort of patients that are seen by HaH. To allow this to thrive however, standardised, robust protocols and accreditation pathways as seen in other specialities are required. Protocol-driven scanning even with limited training, with oversight from an expert, has been shown to be effective emphasising a model that could be adopted by the multi-disciplinary-team (MDT) allowing many more team members to utilise this skill. Having access to an expert however has been found to be problematic given the geographic variability in ultrasound use as seen in Acute Medicine[14]. With the improvement in cloud-based storage systems of images, users can now receive expert remote review and supervision of their practice whilst their own expertise grows; helping to address this problem. This also relieves pressure on those with more experience in ultrasound and allows more clinicians to experience the benefits of ultrasound in their assessments. From the data we have collected from both centres (Figure 1.1 and 1.2) the most utilised ultrasound modality is abdomen with cardiac and lung in second place for each centre. This indicates the modalities that need to be targeted first in creating protocols and algorithms for use in HaH. It is also important to highlight that current protocols such as the BLUE protocol (figure 2.1) are founded on evidence collected from intensive care patients who have very different physiology compared to patients seen in Hospital at Home. HaH patients tend to have higher frailty and more chronic co-morbidities. This would need to be addressed and adapted for patients seen in HaH as more data is collected from this specific cohort. Development of service frameworks for HaH is required to help it evolve and ensure safety as this care model grows.

Funding

This work is supported by the National Institute for Health Research (NIHR) Applied Research Collaboration (ARC) West Midlands, the NIHR HealtTech Research Centre (HRC) for Community Healthcare and the NIHR Oxford Biomedical Research Centre (BRC). The views expressed are those of the authors and not necessarily those of the NHS, the NIHR or the Department of Health and Social Care.

Conflict of Interest

none

References

1. Joint Royal Colleges of Physicians Training Board. Curriculum for Acute Internal Medicine [Internet]. 2022 [cited 2024 Jun 27]. Available from: https://www.thefederation.uk/sites/default/files/AIM%202022%20curriculum%20FINAL%20July%202022_0.pdf
2. Shaddock L, Smith T. Potential for use of portable ultrasound devices in rural and remote settings in Australia and other developed countries: A systematic review. *J Multidiscip Healthc*. 2022 Mar 29; **15**:605-625. Available from: https://pubmed.ncbi.nlm.nih.gov/35378744/ doi: 10.2147/JMDH.S359084
3. Hospital At Home. What is Hospital at Home? [Internet]. 2022 [2024 Jun 27]. Available from: https://www.hospitalathome.org.uk/whatis
4. Sheppard S, Butler C, Cradduck-Bamford A, Ellis G, Gray A, Hemsley A, *et al.* Is comprehensive geriatric assessment admission avoidance hospital at home an alternative to hospital admission for older persons? : A randomized trial. *Ann Intern Med*. 2021 Jul; **174**(7):889-898. Available from: https://pubmed.ncbi.nlm.nih.gov/33872045/ doi: 10.7326/M20-5688
5. Singh S, Gray A, Shepperd S, Stott D, Ellis G, Hemsley A, *et al.* Is comprehensive geriatric assessment hospital at home a cost-effective alternative to hospital admission for older people? *Age Ageing*. 2022 Jan 6; **51**(**1**). Available from: https://pubmed.ncbi.nlm.nih.gov/34969074/ doi: 10.1093/ageing/afab220
6. Knight T, Lasserson D. Hospital at home for acute medical illness: The 21st century acute medical unit for a changing population. *J Intern Med*. 2022 Apr; **291**(**4**):438-457. Available from: https://pubmed.ncbi.nlm.nih.gov/34816527/ doi: 10.1111/joim.13394
7. Rajaiah N, Kainth HK, Knight T, Clare S. EPICENTRE - Delivery of high quality acute medical care without transfer to hospital. *Acute Med*. 2021; **20**(**3**):235.
8. The Society of Acute Medicine. FAMUS – How to accredit [Internet]. [cited 2024 Jun 27]. Available from: https://www.acutemedicine.org.uk/famus/how-to-accredit/
9. The Intensive Care Society. FUSIC [Internet]. 2024 [cited 2024 Jun 27] Available from: https://ics.ac.uk/learning/fusic.html
10. Lichtenstein D, Goldstein I, Mourgeon E, Cluzel P, Grenier P, Rouby J-J. Comparative diagnostic performances of auscultation, chest radiography, and lung ultrasonography in acute respiratory distress syndrome. *Anesthesiology*. 2004 Jan; **100**(**1**):9-15. Available from: https://pubmed.ncbi.nlm.nih.gov/14695718/ doi: 10.1097/00000542-200401000-00006
11. Lichenstein D, Mezière G. Relevance of lung ultrasound in the diagnosis of acute respiratory failure: the BLUE protocol. *Chest*. 2008 Jul; **134**(**1**):117-25. Available from: https://pubmed.ncbi.nlm.nih.gov/18403664/ doi: 10.1378/chest.07-2800
12. Clare S, Duncan C. Ultrasound for the generalist: A guide to point of care imaging. 1st edition. Cambridge: Cambridge University Press; 2022.
13. Millington S. Ultrasound assessment of the inferior vena cava for fluid responsiveness: easy, fun, but unlikely to be helpful. *Can J Anaesth*. 2019 Jun; **66**(**6**):633-638. Available from: https://pubmed.ncbi.nlm.nih.gov/30919234/ doi: 10.1007/s12630-019-01357-0
14. Aggarwal S, Shanmugam R, Knight T, Atkin C, Clare S, Smallwood N, *et al.* Geographic variation in point of care ultrasound provision: results from a national audit. *Ultrasound J*. 2023 Mar 21;**15**(**1**):16. Available from: https://pubmed.ncbi.nlm.nih.gov/36943576/ doi: 10.1186/s13089-023-00314-9.

© 2024 Rila Publications Ltd.