Acute Medicine V9 N2_V3_RM_Acute Med V9 N2.qxd 12/06/2010 11:29 AM Page 73

Case Report

A Successful Case of Repeat Thrombolysis in Acute Prosthetic Valve Thrombosis

F S Naleem, M A Patel, S Basavarajaiah & R Aggarwal

Key Learning Points
- Acute prosthetic valve thrombosis may present with acute heart failure or cardiogenic shock and carries a high mortality
- Early identification through echocardiographic imaging is essential to guide therapy
- Thrombolysis may be superior to surgical thrombectomy and valve replacement in patients with New York Heart Association functional class III-IV cardiac failure
- A second course of thrombolysis should be considered when the first course has resulted in incomplete resolution of the clot with persistent symptoms

Abstract
Acute heart failure is an important presentation in the Acute Medical Unit. We describe a case of successful repeat thrombolysis in an elderly woman presenting as an emergency with severe pulmonary oedema, due to acute prosthetic mitral valve thrombosis. The diagnostic imaging and therapeutic modalities available are also described. This case highlights the need for acute physicians to consider prosthetic valve thrombosis in the differential for patients with metallic heart valves who present with acute heart failure or cardiogenic shock.

Keywords
Prosthetic valve thrombosis, thrombolysis.

Case history
A 74 year old woman was admitted to hospital via the emergency department, having presented with a one week history of progressively worsening shortness of breath. Her exercise tolerance had markedly deteriorated over just one week such that she was unable to climb stairs or mobilise more than a few yards. She had profound symptoms of orthopnea and paroxysmal nocturnal dyspnoea.

She gave a history of hypertension and rheumatic heart disease and had undergone surgery for insertion of metallic mitral and aortic valve prostheses (CarboMedics) in 2004. She was subsequently followed up in the cardiology out-patient clinic with annual trans-thoracic echocardiography. She was in permanent atrial fibrillation and had taken warfarin since surgery. She was a non-smoker and consumed no alcohol.

During her last consultation, one month prior to her presentation, she had been asymptomatic and a trans-thoracic echocardiogram had demonstrated good left ventricular (LV) systolic function (ejection fraction 55-60%), with normal functioning of both aortic and mitral valve prostheses. There were subsequently no new additions to her regular medications and she denied any use of over the counter medications at that time.

She was noted to have a raised jugular venous pressure, bilateral small pleural effusions and gross pulmonary oedema. She was in atrial fibrillation with a fast ventricular response, though maintaining a stable blood pressure. Her electrocardiogram demonstrated atrial fibrillation with left bundle branch block, both of which had been pre-existing since her cardiac surgery. Blood tests were unremarkable, apart from a sub-therapeutic INR of 2.0, which had previously been maintained between 3.5-4.5.

She was treated with intravenous furosemide and was admitted to the coronary care unit. Clinically she was considered to be in New York Heart Association (NYHA) Class IV heart failure at this point.

A trans-thoracic echocardiogram (TTE) performed at the time of admission showed good left ventricular systolic funssction. However there was major dysfunction of the mitral valve prosthesis. There was a significant gradient across the mitral valve, consistent with severe mitral stenosis (MS) **(Panel A of Figure 1).** Additionally, there was evidence of moderate mitral regurgitation (MR).

Subsequent trans-oesophageal echocardiogram (TOE) revealed marked reduction in the mobility of both the hemi-discs due to thrombus, giving rise to severe MS and moderate MR. Extensive thrombus was also noted in the left atrial appendage with spontaneous echo contrast. **(Panel B of Figure 1)** The aortic valve prosthesis was normal.

These findings were consistent with acute obstruction of the mitral valve prosthesis as a result of thrombus formation, presumably due to sub-therapeutic anticoagulation.

The case was discussed with the cardiothoracic surgeons who had undertaken her previous valve surgery. Their view was that the risk of surgery to replace her valve was unacceptably high, due to the large thrombotic burden and the patient's clinical

Shairana Naleem
MBBS, MRCP

Muhammad Abdulmajid Patel
MB ChB BSc

Sandeep Basavarajaiah
MRCP

Rajesh Aggarwal
MD, FRCP
Basildon & Thurrock University Hospital

Correspondence:
Dr. Shairana Naleem
Acute Medicine/Education SpR
2nd Floor Willow Lodge
Medical Education Centre
Whipps Cross University Hospital
Leytonstone
London, E11 1NR
Email: shairana.naleem@googlemail.com

© 2010 Rila Publications Ltd.

Acute Medicine V9 N2_V3_RM_Acute Med V9 N2.qxd 12/06/2010 11:29 AM Page 74

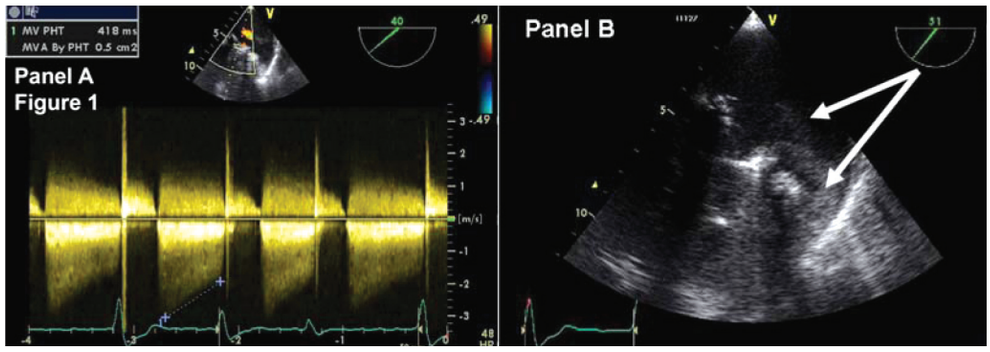

Figure 1. (Panel A:: Pressure half-time across the prosthetic mitral valve via TOE exhibiting measurements consistent with severe mitral stenosis. **(Panel B):** TOE images demonstrating thrombus in left atrial appendage and over the prosthetic mitral valve with spontaneous echo contrast (shown by the arrows)

status. Thrombolysis was therefore recommended as an initial approach.

Conventional low dose tissue plasminogen activator (TpA) was administered in accordance with the standard weight based regimen charts used for acute myocardial infarction, followed by intravenous heparin, whilst warfarin was omitted for one day. 100mg of alteplase was reconstituted in 100ml of normal saline and 9ml was administered over 2 minutes, followed by 45ml over 1 hour and subsequently 36ml over 2 hours. Warfarin was restarted the following day, after completion of thrombolysis. Her condition improved slightly, although she remained symptomatic with ongoing evidence of heart failure (NYHA Class III), having been previously asymptomatic. Repeat TOE showed reduction in the thrombotic burden, but residual thrombus remained in the mitral valve and left atrial appendage **(Panel C of Figure 2).** Diastolic flow across the mitral valve prosthesis was consistent with moderate MS. In view of this and following extensive discussions with the patient and haematologists, it was agreed to proceed to a second course of thrombolysis. This was administered one week after the first dose, utilising the same conventional low dose TpA protocol, followed by intravenous heparin. On this occasion however, warfarin was continued within the therapeutic range.

Within two days of her second course of thrombolysis, the patient had exhibited remarkable improvement in her symptoms with increased exercise tolerance. Repeat TOE demonstrated good mobility of the valve leaflet with no residual thrombus in the valve or left atrium. **(Panel D of Figure 2)** She was successfully discharged with no residual evidence of heart failure and remains well. No cause for her drop in INR was identified, but more frequent monitoring was recommended.

Discussion

Acute thrombotic occlusion of prosthetic valves is an uncommon but potentially life threatening complication with a reported incidence of 0.5 – 8%.[1,2] It results in valve obstruction and/or insufficiency which produces a variety of clinical manifestations ranging from shortness of breath to cardiogenic shock. This case highlights the importance of considering the diagnosis when patients with prosthetic valve replacements present with acute heart failure, particularly in the context of sub-therapeutic INR. Urgent TTE identified the thrombus which was confirmed by TOE, enabling treatment to be given.

The incidence of thromboembolic events is related to the type of valve and location. Where both aortic and mitral valves have been replaced, the reported incidence is between 0.5% to 6% per patient-year.[3] The incidence after lone aortic valve replacement is lower than after mitral valve replacement.[4,5] The peak incidence of thromboembolism is during the first three months after

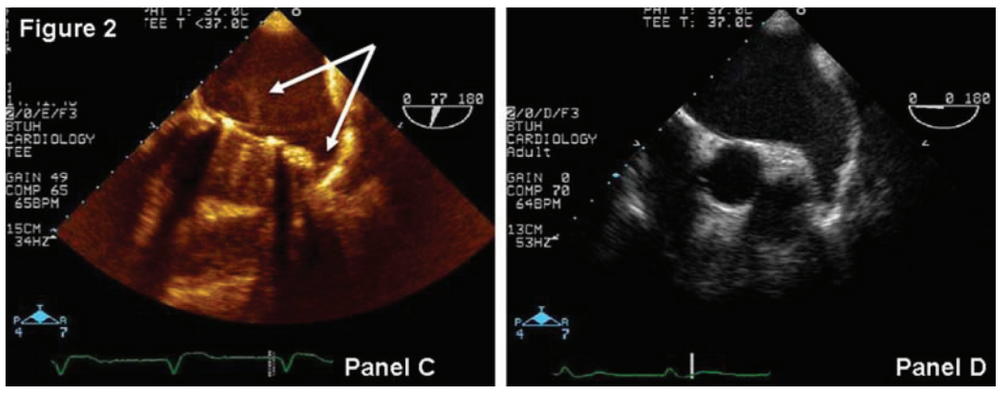

Figure 2. (Panel C): TOE images following first dose of thrombolysis demonstrating relative improvement in the thrombus burden, but residual thrombus still seen in the left atrial appendage and spontaneous echo contrast (shown by the arrows). **(Panel D):** TOE images following second dose of thrombolysis demonstrating absence of thrombus and spontaneous echo contrast in the left atrial appendage and left atrium respectively.

© 2010 Rila Publications Ltd.

Acute Medicine V9 N2_V3_RM_Acute Med V9 N2.qxd 12/06/2010 11:29 AM Page 75

surgery and can reach 13% in the first year for any valve position.[6,7,8] Though inadequate anticoagulant therapy remains the main cause of this complication, surgical technique and pannus formation may also contribute.[9]

An eighteen year study evaluating the Starr-Edwards ball-valve prosthesis observed thrombotic stenosis rates of 0.1% per patient year and 0.4% per patient year for the aortic and mitral valves, respectively.[10] Another study following 440 patients receiving a St Jude mechanical valve in the mitral position for nineteen years demonstrated a 0.2% per patient year rate of valve thrombosis.[11]

Cumulative review of the literature suggests that after implantation of new generation prosthetic mechanical mitral valves, patients should receive warfarin to a target INR of 2.5-3.5. However, for patients with older types of valve the target INR should be 3.5-4.5. Most importantly, warfarin therapy should be administered to maintain stable INR values ensuring the lowest possible variation in the intensity of anticoagulation.[12]

Traditionally, the ideal treatment for valve thrombosis has been surgical thrombectomy and valve replacement; however this carries a high mortality, especially in patients who are in NYHA functional Class III and IV.

Thrombolysis has been used as an alternative to surgery, with success rates reaching 85%.[13,14] Repeated treatment following incomplete resolution of symptoms has been found to be effective in previous case series. Ozkan et al. found that clot resolution improved from 53% to 88% after a second treatment.[12] Another study achieved a 60% success rate of clot resolution following repeat treatment where the first treatment had failed.[15]

A variety of thrombolytic agents, doses and infusion protocols have been employed throughout the literature, and there is no consensus as to the ideal regimen. In this case, the conventional infusion protocol of TpA, as used for myocardial infarction (MI), was adopted. Rapid thrombolytic infusion, especially in the presence of large thrombus, may increase the risk of embolization.[16] This suggests that accelerated regimens should be avoided.

The lowest complication rates following thrombolysis have been achieved in patients with non-obstructive PVT. The use of TOE allows distinction to be made between obstructive and non-obstructive PVT by the presence or absence of occluder motion limitation. Non-obstructive thrombi of > 5 mm length have been treated with higher success rates and lower complication rates by thrombolysis than by anticoagulant treatment. Thrombolysis has been recommended as the first-line treatment for obstructive PVT, independent of NYHA class and thrombus size in the absence of contraindications. Initial anticoagulant therapy is recommended only for small, non-obstructive PVT if anticoagulation had been sub-therapeutic; otherwise, thrombolysis is the treatment of choice if there are no contraindications.[17]

Warfarin therapy with an elevated INR is often considered to be a relative contraindication to thrombolysis in the context of acute MI. There are no established guidelines on an upper limit of INR when considering thrombolysis of PVT. It is generally considered inadvisable to undertake thrombolysis when the INR is >3. Close liaison with the haematology team is essential in all cases where thrombolysis is being considered for patients taking warfarin.

References

1. Edmunds LH, Jr. Thromboembolic complications of current cardiac valvular prostheses. *Ann Thorac Surg* 1982; **34**: 96–106.
2. Kontos GJ, Jr., Schaff HV, Orszulak TA, *et al*. Thrombotic obstruction of disc valves: clinical recognition and surgical management. *Ann Thorac Surg* 1989; **48**: 60–5.
3. Vongpatanasin W, Hillis D, Lange RA. Prosthetic heart valves. *N Engl J Med* 1996; **335**: 407–416.
4. Chesebro JH, Fuster V, Optimal Antithrombotic Therapy for Mechanical Prosthetic Heart Valves. *Circulation* 1996; **94**: 2055–2056.
5. Stein PD, Alpert JS, Copeland J, *et al*. Antithrombotic therapy in patients with mechanical and biologic prosthetic heart valves. *Chest*. 1995; **108(suppl)**:371S–379S.
6. Chesebro JH, Adams PC, Fuster V. Antithrombotic therapy in patients with valvular heart disease and prosthetic heart valves. *J Am Coll Cardiol*. 1986; **8**: 41B–56B.
7. Heras M, Chesebro JH, Fuster V, *et al*. High risk of thromboemboli early after bioprosthetic cardiac valve replacement. *J Am Coll Cardiol*. 1995; **25**: 1111–1119.
8. Roudaut R, Labbe T, Lorient-Roudaut MF, *et al*. Mechanical cardiac valve thrombosis: is fibrinolysis justified? *Circulation* 1992; **86(5 Suppl)**: 118–119.
9. Barbetseas J, Nagueh SF, Pitsavos C, *et al*. Differentiating thrombus from pannus formation in obstructed mechanical prosthetic valves: an evaluation of clinical, transthoracic and transesophageal echocardiographic parameters. *J Am Coll Cardiol* 1998; **32**: 1410–1417.
10. Q. Macmanus, M. T. Metzdorff, G. L. Grunkemeier and A. Starr. Thrombotic and embolic complications with silastic ball prosthetic valves. European Heart Journal 1984 5(Supplement D):59-63; doi:10.1093/eurheartj/5.suppl_D.59.
11. AU Remadi JP; Baron O; Roussel C; Bizouarn P; *et al*. Isolated mitral valve replacement with St. Jude medical prosthesis: long-term results: a follow-up of 19 years. *Circulation* 2001 Mar 20; **103(11)**: 1542–5.
12. Bayliss A, Faber P, Dunning J, Ronald A., What is the optimal level of anticoagulation in adult patients receiving warfarin following implantation of a mechanical prosthetic mitral valve? *Interact Cardiovasc Thorac Surg*. 2007 Jun; **6(3)**: 3906. Epub 2007 Feb 9.
13. Lengyel M, Fuster V, Keltai M, *et al*. Guidelines for management of left-sided prosthetic valve thrombosis: a role for thrombolytic therapy. Consensus Conference on Prosthetic Valve Thrombosis. *J Am Coll Cardiol*. 1997; **30(6)**: 1521–6.
14. Bonow RO, Carabello B, de Leon AC, *et al*. ACC/AHA Guidelines for the Management of Patients With Valvular Heart Disease. Executive Summary. A report of the American College of Cardiology/American Heart Association Task Force on Practice Guidelines (Committee on Management of Patients with Valvular Heart Disease). *J Heart Valve Dis*. 1998; **7(6)**: 672–707.
15. Ozkan M, Kaymaz C, Kirma C, *et al*. Intravenous thrombolytic treatment of mechanical prosthetic valve thrombosis: a study using serial transesophageal echocardiography. *J Am Coll Cardiol*. 2000; **35(7)**: 1881–9.
16. Shapira Y, Vaturi M, Hasdai D, Battler A, Sagie A.The safety and efficacy of repeated courses of tissue-type plasminogen activator in patients with stuck mitral valves who did not fully respond to the initial thrombolytic course. *J Thromb Haemost*. 2003; **1(4)**: 725–8.
17. Lengyel M, Horstkotte D, Völler H, Mistiaen WP; Working Group Infection, Thrombosis, Embolism and Bleeding of the Society for Heart Valve Disease. Recommendations for the management of prosthetic valve thrombosis. *J Heart Valve Dis*. 2005 Sep; **14(5)**: 567–75; 2008 **9(4)**: 413–414.

© 2010 Rila Publications Ltd.