Case Report

Thrombotic thrombocytopenia following ChAdOx1 nCov-19 vaccination

A Jafri★, A Prieto★, HDE Gashau & JD Bartlett
★ authors contributed equally

Abstract
Serious thromboembolic events with concurrent thrombocytopenia, sometimes accompanied by bleeding, have occurred very rarely following administration of the ChAdOx1 nCoV-19 vaccine. We report the case of a 59-year-old male with an unremarkable medical history who presented to the emergency department with increasing breathlessness five days after receiving the first dose of ChAdOx1 nCov-19. The patient's blood results showed mild thrombocytopenia and a very high D-dimer, and a pulmonary embolism was confirmed through a CT pulmonary angiogram, which led to a provisional diagnosis of vaccine-induced immune thrombotic thrombocytopenia. The condition was then treated with immunoglobulin and intravenous argatroban in line with the guidance from the Expert Haematology Panel focussed on Vaccine-induced Thrombosis and Thrombocytopenia before conversion to apixaban.

Keywords
AstraZeneca, Covid-19, Vaccine, Thrombosis, Thrombocytopenia

Learning Points
1. Urgent treatment for VITT should be promptly initiated once a provisional diagnosis has been established (i.e., confirmed or suspected thrombosis 5-28 days after vaccination with platelets <150x10^9/L and D-dimer >4000mcg/L), and then confirmed or ruled out with further investigations.
2. Management of VITT includes IVIG, non-heparin anticoagulation, minimization of platelet transfusion and fibrinogen replacement if needed to maintain levels above 1.5g/L.
3. The choice of anticoagulation depends on clinical status and bleeding risk. Consider a DOAC as first line for patients with low bleeding risk and argatroban in patients with platelets <30x10^9/L.
4. Using aPTT for argatroban monitoring in coagulopathies such as HIT or VITT provides poor correlation with drug levels and therefore a thrombin inhibitor assay (e.g., Hemoclot®) may be preferred.

Background
The coronavirus disease 2019 (Covid-19) pandemic caused by severe acute respiratory syndrome coronavirus 2 (SARS-CoV-2) has been associated with a large morbidity and mortality which stimulated the development of several highly effective vaccines at an unprecedented rate. No safety concerns apart from some anaphylactic reactions were reported in the initial clinical trials, and the risk of serious adverse effects remain very low after the administration of more than a billion doses.[1,2]

Thromboembolic events with concurrent thrombocytopenia, sometimes accompanied by bleeding, have occurred very rarely following administration of the ChAdOx1 nCoV-19 vaccine (AstraZeneca), the majority occurring in patients below 50 years old and within 5 to 28 days following vaccination.[2] The condition has been referred to as vaccine-induced thrombosis and thrombocytopenia (VITT) or thrombosis with thrombocytopenia syndrome (TTS) and has a similar presentation to heparin-induced thrombocytopenia (HIT) but without a previous exposure to heparin. Similar events have been associated with the prior administration of the COVID-19 vaccine manufactured by Johnson & Johnson/Janssen.[3,4] The thrombosis is rapidly progressive, and there is a high preponderance of thromboses at unusual sites — specifically, cerebral venous sinus thrombosis or thrombosis in the portal, splanchnic, or hepatic veins. Deep venous thrombi, pulmonary emboli (PE), or acute arterial thromboses have also been reported.[2]

Case Presentation
A 59-year-old male, who had been administered the first dose of the ChAdOx1 nCov-19 vaccine five days prior, presented to the emergency department with worsening breathlessness. His symptoms were initially occurring on exertion but had progressed to occurring at rest on the day of presentation.

Adnan Jafri[1]
MuDr
Senior Clinical Fellow in Acute Medicine

Antonio Prieto[1]
MPharm
Clinical Pharmacist

Hyeriju David Emmanuel Gashau[1]
MuDr
Clinical Fellow in Respiratory Medicine

James Daniel Bartlett[1]
MBBS, BSc, FRCP
Lead Consultant for Acute Medicine

[1] Hereford County Hospital

Correspondence:
Adnan Jafri,
11 Ferndale Street,
Grangetown,
Cardiff,
CF11 7AZ

© 2021 Rila Publications Ltd.

The patient weighed 120kg but had no significant past medical history, was a non-smoker and was independent with activities of daily living.

On admission he was dyspnoeic at rest with ongoing discomfort on the left side but had no haemoptysis. On examination he had a respiratory rate of 20 breaths/min, oxygen saturations of 97% on ambient air with a heart rate of 114 beats/min, a blood pressure of 178/98 mmHg and a temperature of 36.0°C. On auscultation he had a clear chest and normal heart sounds. There was no calf tenderness or swelling. The patient's Pulmonary Embolism Severity Index (PESI) score was 89 which indicates an intermediate risk.

Investigations

SARS-CoV-2 reverse-transcriptase–polymerase-chain-reaction assay of a nasopharyngeal swab was negative. Blood results showed a raised D-Dimer (6505mcg/L) and initial troponin (38ng/L) with a mildly low platelet count (121x10^9/L). SARS-CoV-2 antibodies were not detected.

Although there was thrombocytopenia, the platelet count was not below 100x10^9/L and so a blood film was not performed in accordance with local protocol. The white blood cell count, C reactive protein and clotting profile were all within normal range. Fibrinogen levels were normal at 3.2g/L.

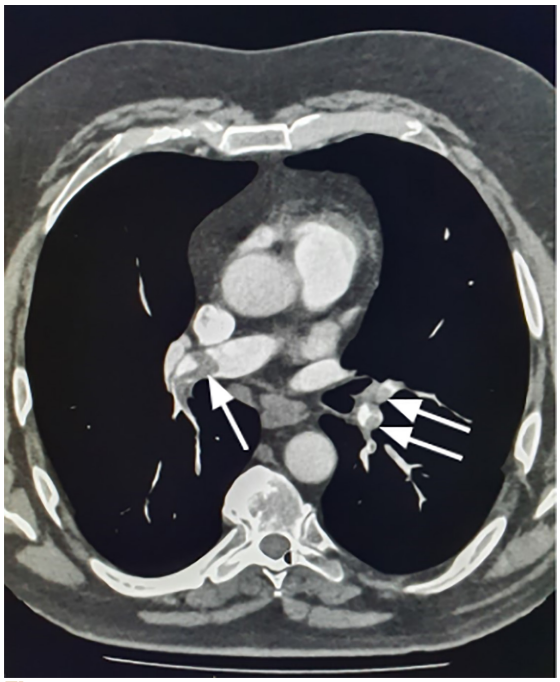

Figure 1. CTPA showing multiple pulmonary emboli (depicted by the white arrows) obstructing the left and right main branches of the pulmonary artery.

The lack of increased oxygen requirement meant no arterial blood gas was taken. The ECG on admission showed sinus tachycardia and the chest X-ray was unremarkable. A CT pulmonary angiogram was performed which confirmed a thrombus of 3cm in the distal right pulmonary artery extending to the right upper and lower lobe pulmonary arteries. There was no evidence of heart strain or pleural effusion (Figure 1). A CT intracranial venogram excluded any further thrombosis. Anti-Platelet factor 4 (PF4) assay by enzyme-linked immunosorbent assay (ELISA) returned after a few days as negative.

Differential Diagnosis

Due to the rapid progression of breathlessness with a significantly raised D-dimer, a PE was the most likely diagnosis. The recent history of vaccination suggested VITT as the possible cause.

Other differentials such as cardiac cause, community acquired pneumonia, pneumothorax or connective tissue disorder were considered. The patient did not have a fever, productive cough, worsening chest pain, syncope or clinical examination findings to correlate with these diagnoses along with a normal chest X-ray, ECG, white cell count and C reactive protein. The troponin rise was attributed to heart strain which gave an indication of the potential severity of the PE.

Treatment

There were no signs of shock, hypotension or cardiac dysfunction on presentation and therefore thrombolysis with alteplase was not required. The patient initially received therapeutic enoxaparin for a suspected PE. Once the PE and the timing of the vaccination were confirmed, and the thrombocytopenia and raised D-dimer were considered; a decision was made to commence treatment for VITT in line with the guidelines from the expert Hematomology panel focused on VITT.[5] The patient was transferred to the level 2 unit for intensive monitoring of clotting profile and platelet count and was commenced on 1g per kg of adjusted body weight of intravenous immunoglobulin (IVIG) divided over two days. Once the Clauss fibrinogen level was confirmed to be greater than 1.5g/L, the patient was commenced on anticoagulation - intravenous argatroban was infused at an initial rate of 2micrograms/kg/min and subsequently adjusted to maintain an activated partial thromboplastin time (aPTT) within 1.5 to 3.0 times the initial baseline value.

© 2021 Rila Publications Ltd.

Outcome

After initial treatment with IVIG and argatroban, the patient remained well and was observed for signs of recurrence. The platelet count recovered to 248x10^9/L within forty-eight hours, the clotting profile remained stable, and there was a reduction in D-dimer levels. The patient was switched to the direct oral anticoagulant (DOAC) apixaban and was discharged with Haematology follow-up arranged in six months' time. Given the negative anti-PF4 results, a decision on the length of treatment will be made dependent on the patient's Vienna prediction model score.

Discussion

VITT is an adverse reaction to the ChAdOx1 nCoV-19 vaccine, and it has similarly been described for the COVID-19 vaccine manufactured by Johnson & Johnson.[3,4] The clinical features of VITT are similar to those seen in HIT but without previous exposure to heparin. The exact incidence is unknown, although it seems to be very rare with an estimated incidence of 1 in 26,000 for ChAdOx1 nCoV-19.[6] The majority of the reported events occurred in females below 60 years old, although it is unclear whether it generally affects women more or not.[4] All of the patients reported with VITT presented with an unremarkable medical history and within 5 to 28 days after vaccination.[2,6,7] This case highlights the importance of recognising VITT, the parameters which aid its diagnosis and how to manage the patient using IVIG therapy and specific anticoagulation.

VITT is associated with a high mortality and is characterized by the presence of thrombocytopenia and thrombosis, often in unusual sites like the cerebral sinus veins or splanchnic veins.[6] Platelet counts in the reported cases ranged from 11 to 113×10^9/L, although several societies currently define VITT with values of <150x10^9/L.[5,8,10] Early mechanistic evaluations have identified anti-PF4 antibodies able to activate platelets similar to those found in HIT, which can be detected using a HIT ELISA test, but not reliably with other HIT laboratory tests.[9] Additionally, testing typically reveals low to normal fibrinogen and very raised D-Dimer levels above the range typically expected in venous thromboembolism.

This patient without comorbidities presented with a PE, a high D-dimer (>4000mcg/L) and mild thrombocytopenia 5 days after receiving the first dose of ChAdOx1 nCoV-19 vaccine. Usually, a patient with a PE diagnosis showing haemodynamic stability, lack of oxygen requirement and low bleeding risk would have been started on a DOAC and discharged immediately with an outpatient follow-up. However, there was sufficient evidence to provide a provisional diagnosis for VITT whilst anti-PF4 levels were analysed, in line with expert consensus from various national and international societies that have published position papers on the diagnosis and treatment of VITT,[5,8,10] which recommend that specific treatment should not be delayed in the event of a likely diagnosis whilst waiting for anti-PF4 results. ELISA is the recommended screening test and a positive anti-PF4 result is confirmatory. There have also been false-negative results reported[9] and therefore the negative result obtained for this patient does not completely exclude the diagnosis of VITT. The increase of platelet levels after the administration IVIG in the case presented has also been reported in patients with VITT.[11]

VITT is a newly described syndrome, and all treatment recommendations are based on extrapolation from similarities to HIT and to non–heparin-dependent autoimmune thrombotic thrombocytopenias, analysis of the clinical features in reported cases, and predictions based on laboratory investigations of pathophysiology.[8] Recommendations for the management of VITT include using IVIG (irrespective of the degree pf thrombocytopenia[5]) to interrupt antibody-induced platelet activation. Corticosteroids have also been added in some cases, although whether they are beneficial is unknown. Fibrinogen replacement has been recommended if needed to maintain levels above 1.5g/L. The minimisation of platelet infusions and the use of non-heparin anticoagulation is also recommended. [5,8,10]

It is unknown whether heparin exacerbates VITT but the similarities with HIT suggest avoidance of unfractionated or low-molecular-weight heparin is warranted. There are reports of patients that experienced clinical deterioration, including death, following initial treatment with low-molecular-weight heparin, although whether this contributed to the outcomes is unknown.[11] No consensus has been reached yet regarding the use of anticoagulation in patients with secondary cerebral bleed who do not require surgical procedures.[5]

This patient was initially started on argatroban after discussion with Haematology and in line with the Expert Haematology Panel on VITT.[5] The choice of non-heparin anticoagulant should be based on the patient's clinical status and the anticipated need for stopping anticoagulation as per the patient's bleeding risk and the likelihood of a potential surgical intervention.[5] A DOAC may be used before other options due to their safety profile, convenience and demonstrated clinical efficacy in

© 2021 Rila Publications Ltd.

treating HIT.[12] This probably would have been the optimal choice in regard to this patient. The Expert Haematology Panel on VITT recommends the use of low dose fondaparinux or alternatively a short-acting parenteral direct thrombin inhibitor such as argatroban when platelets fall below $30x10^9$/L. Argatroban has a half-life of 40 to 50 minutes and may be reversed rapidly upon discontinuation if required for bleeding, but it is associated with a higher cost and bleeding risk, and drug levels do not correlate well with aPTT in cases of underlying coagulopathy.[13] Therefore, use of a thrombin inhibitor assay such as Hemoclot® may be more reliable when using argatroban in VITT,[5] and prompt switch to fondaparinux or a DOAC should be undertaken as soon as the bleeding risk is considered to have been reduced. Fondaparinux may be used whilst taking into account that very rare cases of cross-reactivity and exacerbation of HIT have been reported.[12]

In conclusion, this case report stresses the importance of correlating the timing after receiving the ChAdOx1 nCoV-19 vaccination with a high D-dimer and thrombocytopenia in patients with suspected or confirmed thromboembolism to offer urgent treatment with immunoglobulin and anticoagulation.

References

1. World Health Organization (WHO); WHO Coronavirus (COVID-19) Dashboard [online]. Geneva: WHO; [updated 10/05/21; accessed 10/05/21]. Available from: https://covid19.who.int/
2. Cines DB, Bussel JB; SARS-CoV-2 Vaccine-Induced Immune Thrombotic Thrombocytopenia [published online ahead of print, 16/04/2021]. *N Engl J Med*. 2021.
3. Muir KL, Kallam A, Koepsell SA, *et al*. Thrombotic Thrombocytopenia after Ad26.COV2.S Vaccination. *N Engl J Med*. 2021; **384:** 1964-5.
4. Barnes GD, Cuker A, Piazza G, *et al*. Vaccine-induced Thrombotic Thrombocytopenia (VITT) and COVID-19 Vaccines: What Cardiovascular Clinicians Need to Know [online]. Washington, DC: *American College of Cardiology* [updated 06/06/21, cited 12/06/21]. Available from: https://www.acc.org/
5. Pavord S, Lester W, Makris M, *et al*. Guidance produced by the Expert Haematology Panel focussed on Vaccine induced Thrombosis and Thrombocytopenia [online]. London: *British Society for Haematology* [updated 20/04/2021; cited 13/05/2021]. Available from: https://b-s-h.org.uk/
6. Schultz NH, Sørvoll IH, Michelsen AE, *et al*. Thrombosis and Thrombocytopenia after ChAdOx1 nCoV-19 Vaccination [published online ahead of print, 09/04/2021]. *N Engl J Med*. 2021.
7. Muir KL, Kallam A, Koepsell SA, *et al*. Thrombotic Thrombocytopenia after Ad26.COV2.S Vaccination. *N Engl J Med*. 2021; **384:** 1965-6.
8. Bussel BJ, Connors JM, Cines DB, *et al*. Thrombosis with Thrombocytopenia Syndrome (also termed Vaccine-induced Thrombotic Thrombocytopenia) [online]. Washington, DC: *American Society of Hematology*; [updated 20/04/2021; cited 13/05/2021]. Available from: https://www.hematology.org/
9. Scully M, Singh D, Lown R, *et al*. Pathologic antibodies to platelet factor 4 after ChAdOx1 nCoV-19 vaccination [published online ahead of print, 16/04/2021]. *N Engl J Med*. 2021.
10. International Society on Thrombosis and Haemostasis (ISTH); ISTH Interim Guidance for the Diagnosis and Treatment on Vaccine-Induced Immune Thrombotic Thrombocytopenia [online]. Carrboro, NC: *ISTH* 2021; [updated 20/04/2021; accessed 12/5/21]. Available from: https://www.isth.org/
11. Greinacher A, Thiele T, Warkentin TE, *et al*. Thrombotic Thrombocytopenia after ChAdOx1 nCov-19 Vaccination. *N Engl J Med*. 2021; [published online ahead of print, 09/04/2021].
12. Manji F, Warkentin TE, Sheppard JI, *et al*. Fondaparinux cross-reactivity in heparin-induced thrombocytopenia successfully treated with high-dose intravenous immunoglobulin and rivaroxaban. Platelets 2020; **31:** 124-127.
13. Guy S, Kitchen S, Maclean R *et al*. Limitation of the activated partial thromboplastin time as a monitoring method of the direct thrombin inhibitor argatroban. *Int J Lab Hematol*. 2015; **37:** 834-43.

© 2021 Rila Publications Ltd.