Case Reports

Endogenous endophthalmitis and liver abscesses

S Koay, S Jain, I Cropley, H Petrushkin & H Beynon

Key Learning Points
- Endogenous endophthalmitis is a serious intraocular infection resulting from haematogenous spread of bacteria from a distant primary source.
- It is often associated with patients with an underlying medical condition, or those with risk factors for immunosuppression.
- Prompt diagnosis and administration of antibiotics is important to optimise visual outcomes.
- Acute medical teams should be aware of this potentially blinding condition, and include it in the differential diagnosis for painless loss of vision.

Abstract
We present a case of endogenous endophthalmitis secondary to liver abscesses, in a patient with no previous medical comorbidities or risk factors for immunosuppression. The patient presented with acute painless loss of vision and feeling generally unwell. Investigations revealed Streptococcus anginosus-constellatus bacteraemia, and evidence of diverticular disease that likely predisposed to the liver abscesses. Due to prompt diagnosis and administration of antibiotics, the patient had a good visual outcome. This case highlights the importance of being aware of endogenous endophthalmitis, as early diagnosis and prompt administration of antibiotics will optimise visual outcomes.

Keywords
Endogenous endophthalmitis, liver abscesses, diverticular disease, loss of vision.

Case Report
Case History
A 52 year old man presented to the Acute Medical Unit with a one day history of sudden onset painless left sided loss of vision. He reported feeling unwell in preceding two weeks, with anorexia and sweats. He also mentioned a single episode of minimal rectal bleeding two days prior. He was otherwise fit and well, with no risk factors for immunosuppresion, no recent surgery, dental work, or foreign travel.

On examination, he was pyrexial at 39°C but remained haemodynamically stable. Clinical examination was normal, apart from a red left eye with visual acuity limited to counting fingers (CF) in that eye. Of note there were no murmurs or signs of infective endocarditis. Slit lamp examination by the ophthalmology team showed cells+++, keratic precipitates+++ and a 1mm hypopyon in the left anterior chamber. A yellow haemorrhagic lesion was seen in the superior temporal quadrant of the left retina(Figure 1). There were also two cotton wool spots seen in the right retina. Blood tests showed a white cell count of 20.57 x 10^9/L (neutrophils 17.3) and C-reactive protein of 245mg/L. Renal and liver function tests were normal, and a HIV test was negative.

Blood cultures were performed, following which intravenous amoxicillin and gentamicin, cyclopentolate 0.5%, and dexamethasone eye drops were commenced for suspected endogenous endophthalmitis.

Blood cultures and a subsequent anterior chamber sample grew *Streptococcus anginosus-constellatus,* which was sensitive to penicillin.

CT scanning demonstrated lesions in the liver compatible with liver abscesses(Figure 2). A subsequent colonoscopy showed evidence of diverticular disease, which was thought to have predisposed to the liver abscesses.

The patient was discharged after completing a three week course of intravenous amoxicillin and gentamicin, and continued to take a further three week course of oral amoxicillin at home. Upon discharge, his visual acuity had improved from CF to 6/18 in the left eye.

Discussion
Endogenous endophthalmitis is a rare but potentially blinding intraocular infection that results from haematogenous spread of bacteria from a distant primary source.

It is often associated with an underlying medical condition (which causes a relative immunosuppression), recent surgery, or dental manipulation.[1] Recognised associations include diabetes mellitus, malignancy, HIV infection, cardiac disease, and intravenous drug usage.

S Koay
MBBS
FY2 Acute Medicine,
Royal Free Hospital,
London

S Jain
FRCOphth
Consultant
Ophthalmologist,
Royal Free Hospital,
London

I Cropley
FCRP
Consultant in Infectious Diseases,
Royal Free Hospital,
London

H Petrushkin
MBBS
Specialist Registrar in Ophthalmology,
Royal Free Hospital,
London

H Beynon
FRCP
Consultant Physician,
Royal Free Hospital,
London

Correspondence:
S Koay
Royal Free Hospital,
Pond Street,
London NW3 2QG
Email: s.koay@nhs.net

© 2012 Rila Publications Ltd.

Endogenous endophthalmitis and liver abscesses

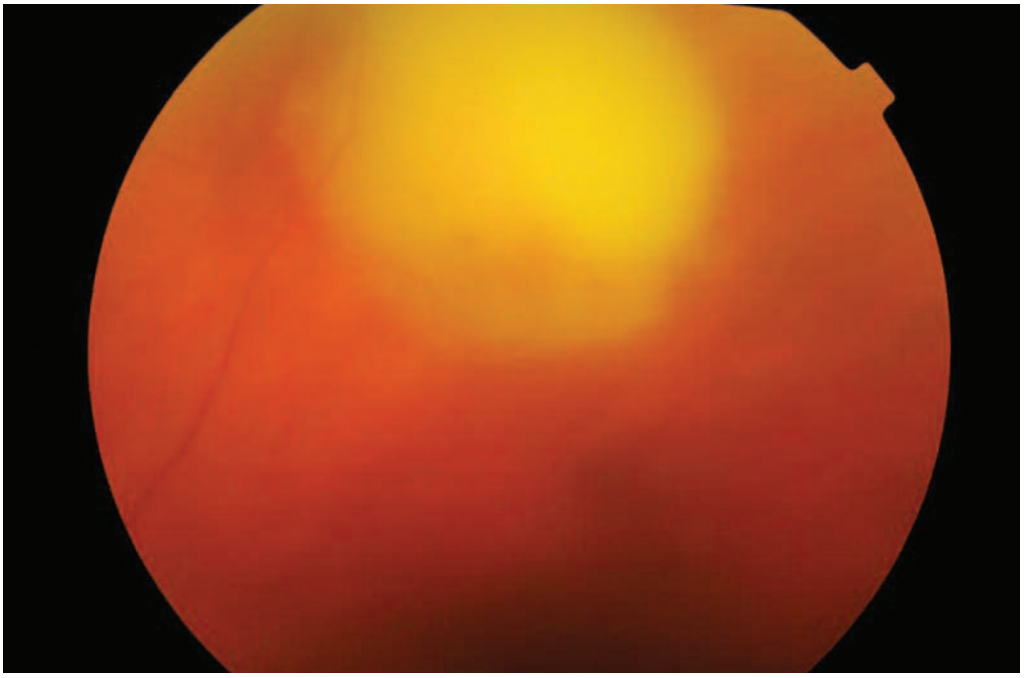

Figure 1. Fundal photograph of patient's left eye, showing a yellow haemorrhagic lesion in the superior temporal quadrant of the left retina.

Patients may present with visual loss or blurring of vision, ocular pain, discharge or a red eye. They may also report systemic symptoms such as lethargy, fever, anorexia and weight loss. It is important to note that our patient presented with painless loss of vision, which is more commonly due to central retinal artery or vein occlusion, vitreous haemorrhage, retinal detachment, and non-arteritic anterior ischaemic optic neuropathy.

Streptococcus milleri group (which include *Streptococcus anginosus-constellatus*) are commensals found in the mouth, oropharynx, gastrointestinal tract, and genitourinary tract.[2] They are one of the commonest causes of liver abscesses in the United Kingdom,[3] and can be associated with suppurative metastatic complications.[4] However, they are a rare cause of bacterial endogenous endophthalmitis, which is most

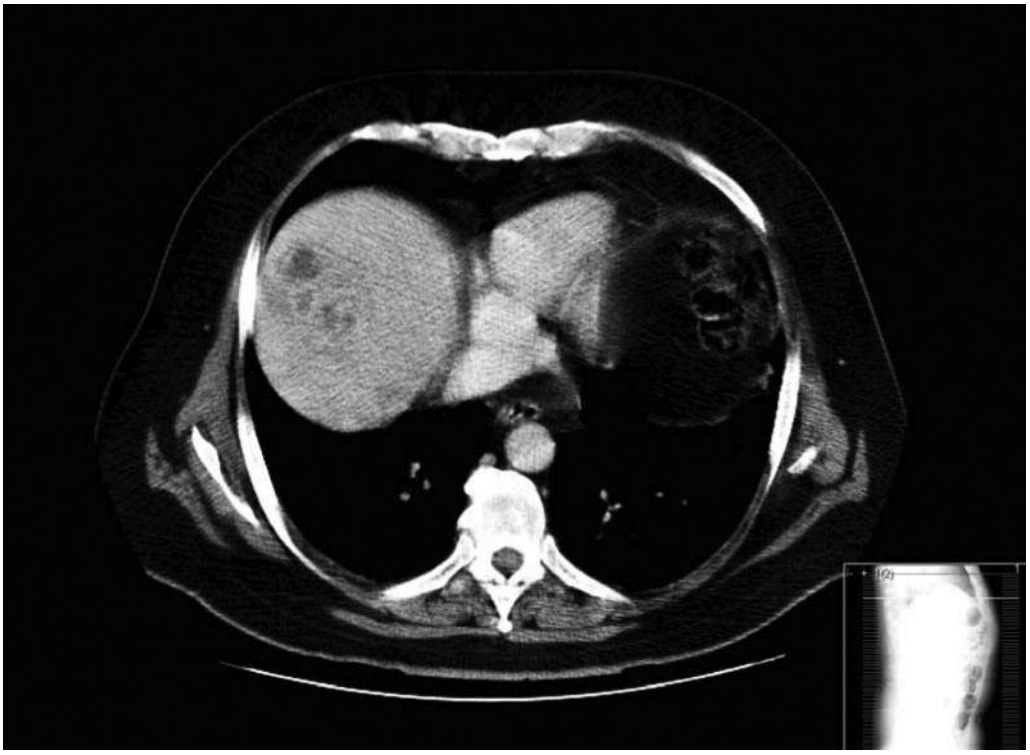

Figure 2. CT scan demonstrating several low attenuating poorly defined areas in the liver, in keeping with liver abscesses.

© 2012 Rila Publications Ltd.

commonly caused by Gram negative organisms (particularly *Klebsiella spp*.).[5]

Prompt administration of antibiotics is important in endogenous endophthalmitis, as it helps to optimize visual outcomes. In most cases, the diagnosis is based on history and examination findings, and treatement is initiated empirically whilst awaiting results of intraocular and blood cultures.[1] There is no clear consensus or guidelines regarding the optimal route of administration of antibiotics. As many topical, subconjunctival and systemic antibiotics do not reach therapeutic levels within the vitreous,[6] it has been suggested that intravitreal injection of antibiotics will deliver rapid therapeutic levels of intraocular antibiotic.[5] However, administration of intravitreal antibiotics does not necessarily significantly improve visual prognosis.[5,7] It has also been suggested that intravenous antibiotics may be all that is necessary to treat the intraocular infection, if a specific organism is cultured from blood.[8] Intraocular antibiotics and steroids can then be considered if the inflammatory response worsens.[8] In the case described above, the decision was made to not administer intravitreal antibiotics, as the patient was responding well to intravenous antibiotics, evidenced by his improving visual acuity.

Visual prognosis is often poor, with 26%-44% of patients being left blind.[5,9] Poor prognostic factors include delay in diagnosis;[9] use of inappropriate antibiotics;[10] diffuse infection of the vitreous and retina, or panophthalmitis;[9] infection with virulent organisms;[7] and gram negative infection.[5,7,9] There is also an appreciable mortality rate of 5%, as a direct result of extraocular infection.[5]

The importance of a prompt diagnosis in ensuring a favourable visual prognosis emphasises the need for acute physicians to be aware of this condition; the possibility of endogenous endophthalmitis should be included in the differential diagnoses for any patient presenting with systemic upset and painless loss of vision. Early referral to the ophthalmology team and discussion with microbiology regarding appropriate choice of antibiotics is essential if this condition is suspected.

References

1. Connell PP, O'Neill EC, Fabinyi D, *et al*. Endogenous endophthalmitis: 10-year experience at a tertiary referral centre. *Eye* 2011; **25**: 66–72.
2. Piscitelli SC, Shwed J, Schreckenberger P, *et al*. Streptococcus milleri group: renewed interest in an elusive pathogen. *Eur J Clin Microbiol Infect Dis* 1992; **11**: 491–8.
3. Mohsen AH, Green ST, Read RD, *et al*. Liver abscess in adults: ten years experience in a UK centre. *QJM* 2002; **95(12)**: 797–802.
4. Gossling J. Occurrence and pathogenicity of the Streptococcus milleri group. *Clin Infect Dis.* 1988; **10(2)**: 257–85.
5. Jackson TL, Eykyn SJ, Graham EM, *et al*. Endogenous bacterial endophthalmitis: 17-year prospective series and review of 267 reported cases. *Surg Ophthalmol* 2003; **48(4)**: 403–23.
6. Barza M, Kane A, Baum J. Intraocular penetration of gentamicin after subconjunctival and retrobulbar injection. *Am J Ophthalmol* 1978; **85**: 541–7.
7. Wong JS, Chan TK, Lee HM, *et al*. Endogenous bacterial endophthalmitis: an East Asian experience and a reappraisal of a severe ocular affliction. *Ophthalmology* 2000; **107(8)**: 1483–91.
8. Brod RD, Flynn HW Jr. Endophthalmitis: current approaches to diagnosis and therapy. *Curr Opin Infect Dis* 1993; **6**: 628–37.
9. Greenwald MJ, Wohl LG, Sell CH. Metastatic bacterial endophthalmitis: a contemporary reappraisal. *Surv Ophthalmol* 1986; **31(2)**: 81–101.
10. Wang LS, Lee FY, Cheng DL, *et al*. Klebsiella pneumoniae bacteremia: analysis of 100 episodes. *J Formos Med Assoc* 1990; **89(9)**: 756–63.

© 2012 Rila Publications Ltd.