Case Report

Weak legs

P Timmons, A Williamson, V Gibbs & A Torgersen

Keywords
Myositis, Drug Reaction, Muscle Weakness, Myopathy, Case Report

Case History

A 48 year old lady presented with a 7-week history of progressive generalised myalgia and muscle weakness resulting in recurrent falls. Her past medical history included bipolar affective disorder and a previous stroke. Her medications included clopidogrel 75mg, atorvastatin 80mg, and quetiapine 400mg twice daily.

On examination, she had widespread muscle tenderness, particularly of the proximal muscles of her arms and legs. Power was graded as 4 out of 5 in her arms and legs. There was no evidence of any rash.

Initial blood tests revealed an AST of 486 and ALT of 276. CK was raised at 8,775 and LDH was 1,121. MR imaging of her pelvis and thighs was undertaken (see Figure 1 and Figure 2 STIR images – *short tau inversion recovery MRI modality*).

Questions

What does the MRI show?

What are the next steps in investigation and management?

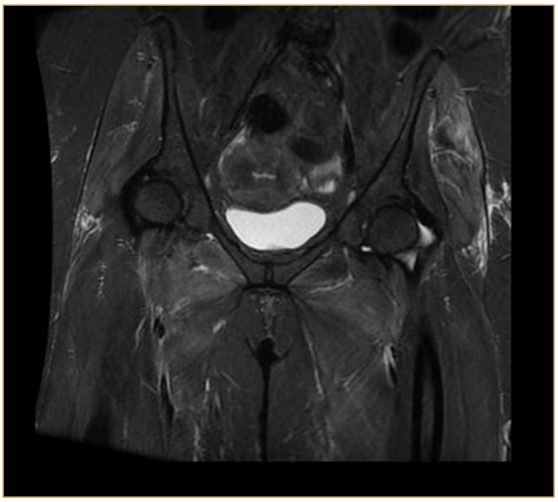

Figure 1.

Answers

Question 1

MRI is the imaging modality of choice for identifying abnormalities in skeletal muscles.[1-2] In myositis, it allows for early diagnosis, assessment of severity, and identify suitable sites for muscle biopsy.[2]

These findings are consistent with a diagnosis of myositis.

MRI is highly sensitive at detecting features of myositis but lacks specificity in identifying the underlying diagnosis. The classical findings of myositis on MRI include high signal intensity on T2-weighted or STIR images consistent with oedema. There may also be increased size of muscles and significant subcutaneous oedema with perifascial thickening and fluid.[2] T1-weigted images can demonstrate fatty replacement which indicates chronicity and damage.[3]

Question 2

We should consider the differential diagnosis for myalgia in the context of a raised creatine kinase

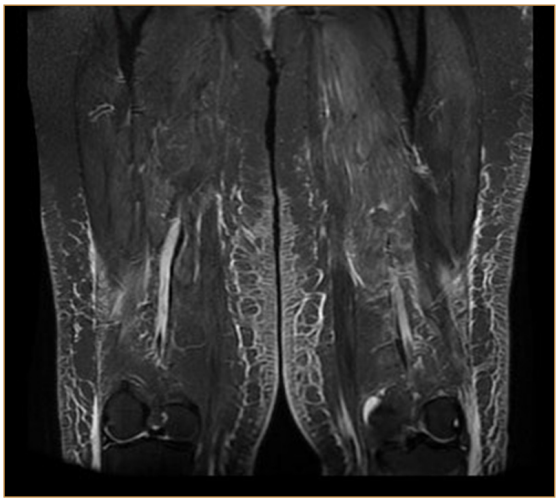

Figure 2.

Patrick Timmons
MRCP, MBChB, Bsc (Med Sci)
CDF in Acute Internal Medicine
Forth Valley Royal Hospital, Larbert

Adam Williamson
MRCP, MBChB
ST7 in Acute and General Internal Medicine,
Forth Valley Royal Hospital, Larbert

Victoria Gibbs
FRCR, MBBs, BSc
Consultant Radiologist
Forth Valley Royal Hospital, Larbert

Antonia Torgersen
Consultant Neuropathologist
NHS Lothian
Edinburgh

Correspondence
Patrick Timmons
CDF in Acute Internal Medicine
Forth Valley Royal Hospital, Larbert
Email: patrick.timmons2@nhs.scot

© 2022 Rila Publications Ltd.

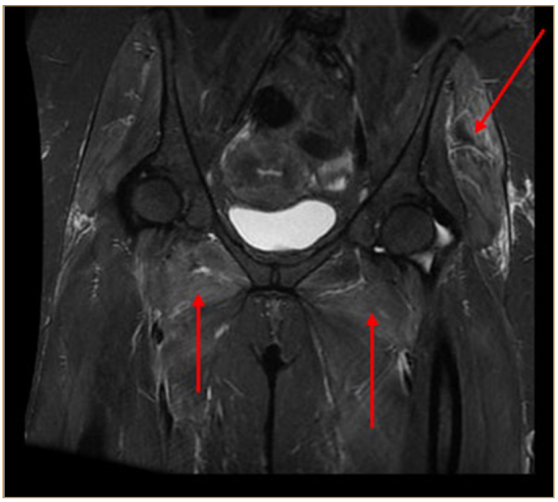

Figure 3. Diffuse patchy high signal and swelling of the adductors and partially imaged gluteal muscles (red arrows).

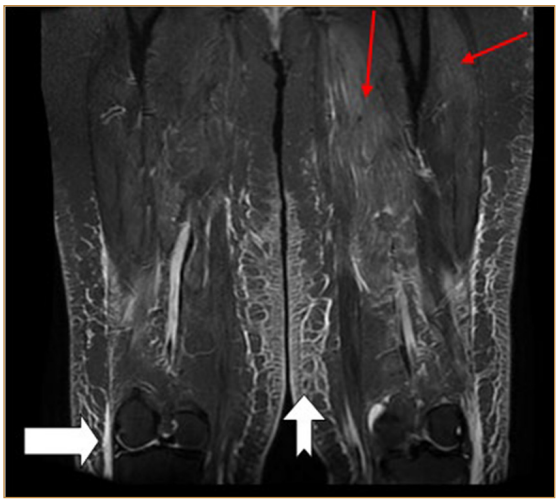

Figure 4. Patchy high STIR signal and swelling within the adductors and vastus lateralis muscle (red arrows). Fluid tracks superficial to the iliotibial bands (white arrow) with overlying marked oedema within the subcutaneous fat of the thighs (notched white arrow)

(CK). These diagnoses are distinct from myalgia in the context of a normal CK (e.g. hyperthyroidism).

History and examination should be used to direct further investigations which may be required for your patient. Particular attention should be paid to drug history. Statins are a well known potential cause of drug-induced myopathy and should be discontinued.[8]

Further investigations may include a CT imaging to look for an underlying malignancy, and autoantibody testing. Anti-nuclear antibodies (ANA) are associated with idiopathic inflammatory myopathies but many myositis associated antibodies are cytoplasmic. Thus, ENA and myositis immunoblot for myositis-specific antibodies (which include anti-Jo-1, anti-Mi-2, anti-SRP, anti-Ku, MDA5-ab, TIF-gamma-ab, MDA5-ab, SAE-1-ab, among others) should be sent.[6,9-12]

A muscle biopsy is required for a definitive diagnosis.[6-7,12]

If the diagnosis is an inflammatory myopathy, treatments may include corticosteroids, immunosuppressive agents (such as methotrexate, azathioprine) or immunoglobulins. Rituximab and cyclophosphamide are reserved for more severe disease.[6,9-12]

Patient Outcome

Atorvastatin was discontinued. Quetiapine was replaced with olanzapine following Psychiatry advice. Due to concerns about an inflammatory myopathy, 40mg Prednisolone was commenced. A CT-chest/abdomen/pelvis was performed to investigate for underlying malignancy; no malignancy was seen. Serological testing for anti-nuclear antibodies, ENA, and myositis specific antibodies were negative. Thyroid function tests were normal.

A muscle biopsy was performed (Figures 5 and 6). This demonstrated the presence vacuolated, necrotic fibres, most consistent with a necrotising myopathy.

Figure 5 staining demonstrates regenerating fibres. There was an absence of significant inflammation (which may have pointed towards a diagnosis of an inflammatory myopathy). There was no evidence of mitochondrial abnormalities within the biopsy.

Further features that may be supportive of a necrotising myopathy, but not seen on our biopsy,

Table 1. outlining causes of myalgia with raised CK[4-8]

Causes of myalgia with raised CK
Inflammatory myopathies Paraneoplastic Idiopathic (e.g. Polymyositis, Dermatomyositis, Inclusion body myositis, overlap myositis)
Infectious myositis Viral (e.g. influenza, HIV) Bacterial (e.g. Staphylococcus aureus, streptococci) Parasitic (e.g. toxoplasma, cysticerci) Fungal
Drug and toxin-related myopathies E.g. statins, glucocorticoids, alcohol, chloroquine
Endocrine related myopathies Hypothyroidism Hypoparathyroidism Primary hyperaldosteronism
Metabolic myopathies Inherited Acquired (e.g. vitamin D deficiency)

© 2022 Rila Publications Ltd.

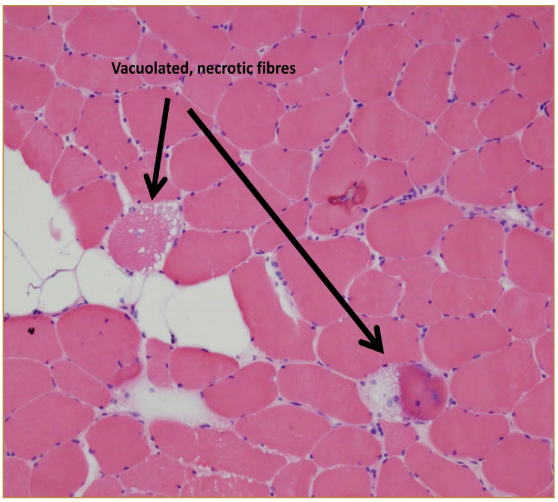

Figure 5.

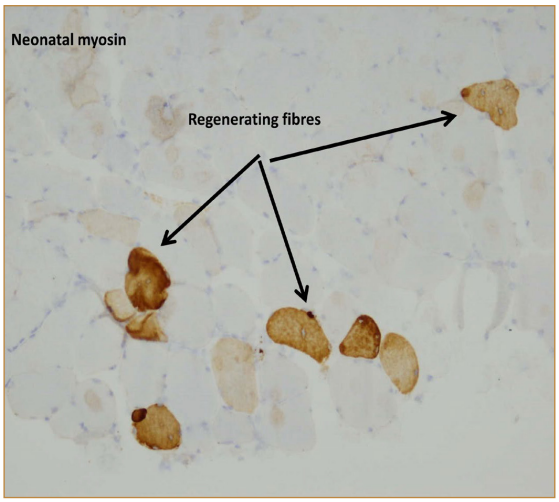

Figure 6.

include macrophagocytosis, absence of widespread MHC-1 upregulation, and atrophic fibres.[8,13]

Necrotizing myopathy may be immune mediated or drug induced. Drug-induced necrotising myopathies are most commonly seen with HMG-CoA reductase inhibitors (statins), alcohol, and fibrates. Management should focus on the withdrawal of the offending agent. There also case reports of quetiapine-induced myopathy; we stopped this for our patient.[14-17]

Immune-mediated necrotising myopathy is an autoimmune condition and auto-antibodies should be checked if there is clinical suspicion.[13]

Our patient went on to fully recover with a tapering course of prednisolone and withdrawal of atorvastatin and quetiapine.

Declaration of competing interests

Nothing to declare

© 2022 Rila Publications Ltd.

References

1. Costa AF, Di Primio GA, Schweitzer ME. Magnetic resonance imaging of muscle disease: A pattern-based approach, *Muscle & Nerve*, 2012, Vol **46 (4)**: 465-481. URL: https://onlinelibrary.wiley.com/doi/full/10.1002/mus.23370?casa_token=VfJG3hhu-4sAAAAA%3ApPYwf5F9EXM-_bW8Jbvhzl F6IwM7XeiexkKzsxgSA_mHpzp1zagDXJ3T01CdTl0QyaPxfziEk66Gjg
2. Smitaman E, Flores DV, Gomez CM, Pathria MN. MR Imaging of Atraumatic Muscle Disorders, *RadioGraphs*, 2018, vol **38(2)**: 500-522. URL: https://pubs.rsna.org/doi/10.1148/rg.2017170112?url_ver=Z39.88-2003&rfr_id=ori%3Arid%3Acrossref.org&rfr_dat=cr_pub++0pubmed&#
3. Thomas X, Milisenda JC, Garcia-Diez AI. Whole-body MRI and pathological findings in adult patients with myopathies, *Skeletal Radiology*, 2018, vol. **48(5)**: 653-676. URL: https://link.springer.com/article/10.1007/s00256-018-3107-1
4. Chawla J. Stepwise Approach to Myopathy in Systemic Disease, *Frontiers in Neurology*, 2011 Vol. **2**: 49. URL: https://www.ncbi.nlm.nih.gov/pmc/articles/PMC3153853/
5. Suresh E, Wimalaratna S. Proximal myopathy: diagnostic approach and initial management, *Postgraduate Medical Journal*, 2013, Vol. **89**: 470-477. URL: https://pmj.bmj.com/content/89/1054/470
6. Schmidt J. Current Classification and Management of Inflammatory Myopathies, *Journal of Neuromuscular Diseases*, 2018, Vol. **5(2)**: 109-129. URL: https://www.ncbi.nlm.nih.gov/pmc/articles/PMC6004913/
7. Lundberg IE, Visser M, Werth VP. Classification of myositis, *Nature Review Rheumatology*, 2018, vol **14**: 269-278. URL: https://www.nature.com/articles/nrrheum.2018.41
8. Valiyil R, Christopher-Stine L. Drug-related Myopathies of Which the Clinician Should Be Aware, *Current Rheumatology Reports*, 2010, Vol **12**: 213-220. URL: https://www.ncbi.nlm.nih.gov/pmc/articles/PMC3092639/#
9. Cordeiro AC, Isenberg DA. Treatment of inflammatory myopathies, *Postgraduate Medical Journal*, 2006, vol **82(969)**: 417-424. URL: https://www.ncbi.nlm.nih.gov/pmc/articles/PMC2563757/
10. Wiendl H. Idiopathic inflammatory myopathies: Current and future therapeutic options, *Neurotherapeutics*, 2008, vol **5(4)**: 548-55. URL: https://www.ncbi.nlm.nih.gov/pmc/articles/PMC4514694/
11. Amato AA, Griggs RC. Treatment of idiopathic inflammatory myopathies, *Current Opinion in Neurology,* 2003, vol **16(5)**: 565-575. URL: https://pubmed.ncbi.nlm.nih.gov/14501840/
12. Souayah N. Idiopathic Inflammatory Myopathies, *BMJ Best* Practice, 2018
13. Pinal-Fernandez I, Casal-Dominguez M, Mammen AL. immune-Mediated Necrotizing Myopathy, *Current Rheumatology Reports*, 2018, Vol **20(4)**: 21. URL: https://www.ncbi.nlm.nih.gov/pmc/articles/PMC6019613/#
14. Stephani C, Trenkwalder C. Rhabdomyolysis after low-dose queiatpine in a patient with Parkinson's disease with drug-induced psychosis: A case Report, *Movement Disorders,* 2010, vol **25(6)**: 790-791. URL: https://movementdisorders.onlinelibrary.wiley.com/doi/full/10.1002/mds.23015
15. Fountoulakis KN, Lacovides A, Kaprinis SG. Diffuse muscle pain with quetiapine, *The British Journal of Psychiatry*, 2018, vol **182(1)**: 81. URL: https://www.cambridge.org/core/journals/the-british-journal-of-psychiatry/article/diffuse-muscle-pain-with-quetiapine/929F617326163F41CBBB0EEE13D8E34F
16. Ceri M, Unverdi S, Altay M, Duranay M. Low-Dose Quetiapine-Induced Severe Rhabdomyolysis, *Renal Failure*, 2011, Vol **33(4)**: 463-464. URL: https://www.tandfonline.com/doi/full/10.3109/0886022X.2011.568141
17. Velasco-Montes J, Orinuela-Gonzalez I, Sanjuan-Lopez AZ. Rhabdomyolysis secondary to quetiapine, *ActasEspañolas de Psiquiatría*, 2012, vol **40(2)**: 97-99. URL: https://pubmed.ncbi.nlm.nih.gov/22508075/

© 2022 Rila Publications Ltd.