Case Report

Stroke due to Thromboembolism from Congenital Aneurysm of Ventricular Septum

S Sharma, A Thomas, A Baghomian & N Waterfield

Learning points
1. Always consider a cardiac source of emboli in young patients presenting with ischaemic stroke.
2. A history suggestive of involvement of multiple arterial territories should increase suspicion of a cardiac source.
3. Trans thoracic echocardiography may be normal in the presence of aneurysm of the inter-ventricular septum.
4. Trans thoracic echo can be normal in the presence of inter atrial septal aneurysm or defect, aortic atheroma as well therefore comment 3 provides incomplete knowledge. It is either avoided or the rest of the conditions should be added.
5. Trans-Oesophageal Echocardiography should be considered if the suspicion of a cardiac source of emboli is high.
6. Anticoagulation and, where possible, surgical correction of the abnormality are the treatments of choice following cerebral embolism from a cardiac source.

Abstract
We describe the case of a 46-year-old female who presented with recurrent episodes of cerebrovascular events. She had an unremarkable family history and no risk factors for stroke, apart from smoking. A transthoracic echocardiogram with 'bubble' contrast was normal. However transoesophageal echocardiography demonstrated an aneurysm of the membranous part of the ventricular septum, representing the likely source of thrombo-embolisation. This case highlights the need for a systematic and rigorous approach to the investigation of young patients with stroke.

Keyword
Stroke; Ventricular septum; Thromboembolism; Transoesophageal echocardiogram; Anticoagulation

Case History
A 46-year-old woman first presented with an episode of transient loss of power in her right arm and leg lasting for about 30 min. A diagnosis of Transient Ischemic Attack was made. CT scan of her brain did not reveal any abnormality. She was commenced on aspirin and advised smoking cessation.

A month later the patient presented with unsteadiness of feet and transient visual disturbances. MR brain scan showed occipital and bilateral cerebellar infarctions. A transthoracic echocardiogram was normal. MR angiography of her carotid and vertebral arteries demonstrated no dissection. Thrombophilia and vasculitic screens were normal. MR angiography of her carotid and vertebral arteries didn't demonstrate any evidence of dissection. The patient's symptoms resolved in a few days, and simvastatin and dipyridamole were added to her treatment regimen.

© 2007 Rila Publications Ltd.

Five months following this, the patient presented with sudden-onset vertigo, unsteady gait, diplopia (due to lateral rectus palsy), and a homonymous quadrantanopia, all indicating a posterior circulation event. She also developed painful terminal digital infarcts of the lateral 3 fingers of her right hand around the same time, examination revealed absent radial pulse and ischaemic appearance of the hand.

Anticoagulation was promptly commenced. Doppler ultrasound of the right upper limb showed complete occlusion of the radial, and partial occlusion of the ulnar artery. A repeat transthoracic echocardiogram - this time with air-bubble contrast- was normal. She went on to have a transoesophageal echocardiogram, which clearly showed an aneurysm of the inter-ventricular septum in the region of the peri-membranous portion (see Figures 1 and 2). This was almost certainly the result of delayed closure of a peri-membranous VSD.

Although no thrombus was evident within the aneurysm at the time of the study-which was performed 5 days after the start of anticoagulation-it was thought highly likely that this was the source of the multiple embolic events. The patient's symptoms resolved almost completely within a few days.

She was referred for repair of the aneurysm. 5 months since reparative operation-which involved excision of the excess septal tissue and tricuspid valvuloplasty-the patient remains asymptomatic without anticoagulation.

Discussion
Although stroke is predominantly a disease of elderly, twelve percent of first stroke occur in patients under the age of 45 years. A cardiac source of emboli is found in 20–30% of young stroke patients.[1,2] Suspicion of

Shashank Sharma
MRCP, Senior S H O
Royal Gwent Hospital
Cardiff Road
Newport
NP20 2UB

Ajit Thomas
MRCP, Consultant Physician in Acute Medicine, Glan Clwyd Hospital

Aram Baghomian
MRCP, Consultant Physician & Clinical Lead in Acute Medicine, Glan Clwyd Hospital

Nick Waterfield
FRCP, Associate Specialist in Cardiology, Glan Clwyd Hospital

Correspondence:
Shashank Sharma
Royal Gwent Hospital
Cardiff Road
Newport
NP20 2UB.
Email: shasha22@Rediffmail.com
Tel: 01275 392830
Fax: 01633 215729
Mobile: 07912857934

Stroke due to Thromboembolism from Congenital Aneurysm of Ventricular Septum

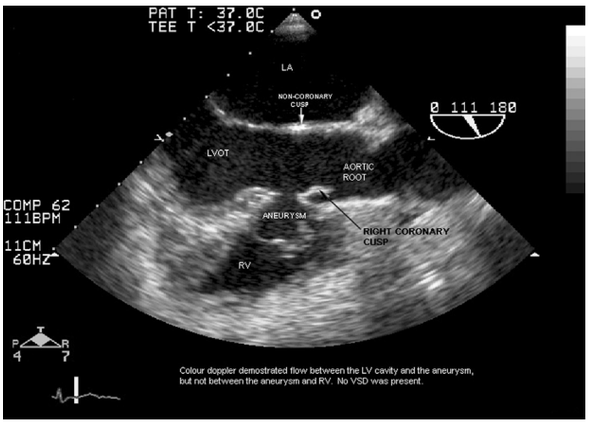

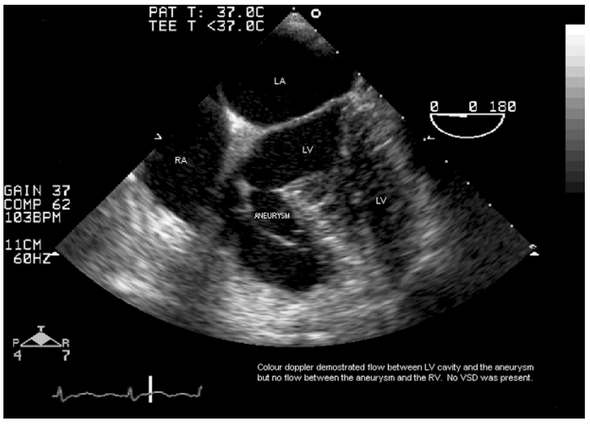

Figure 1 & 2. Stroke due to Thromboembolism from Congenital Aneurysm of Ventricular Septum.

a cardiac source of emboli is increased by a history of palpitations, Marfanoid habitus, peripheral stigmata of infective endocarditis and involvement of multiple arterial territories (as in the case highlighted above).

Initial investigations following stroke should always include a 12 lead ECG and chest radiography. If a cardiac source of emboli is suspected a Trans-thoracic echocardiograph (TTE) with a bubble contrast (5–10 ml of agitated saline or water) should also be considered. Trans-oesophageal echocardiogram (TOE) should be performed when there is a strong clinical suspicion and TTE fails to demonstrate abnormality or is technically unsatisfactory. Dynamic manoeuvres (e.g. Valsalva manoeuvre during TTE and coughing during TOE), will optimise the sensitivity of the procedures.[3] TOE is modality of choice for imaging inter-atrial septum, atria and aortic root.

Cardiac causes for stroke in young patients include prosthetic heart valves, rheumatic valve disease, bacterial endocarditis, dilated cardiomyopathy, ischemic dyskinetic septum, atrial septal aneurysm, patent foramen ovale and mitral valve disease.[4] Both patent foramen ovale and mitral valve prolapse occur frequently in the normal young adult population (in up to 30% and 20% respectively). These abnormalities are four times as common in young patients presenting with stroke, compared to age and sex matched controls. Mitral valve prolapse is more likely to be the cause if there is significant (>2 mm) prolapse of one or both leaflets and if there is accompanying myxomatous degeneration.[5]

Ventricular septal aneurysms usually arise from the membranous part of the septum. An aneurysm that is not associated with Ventricular septal defect (VSD), is more likely to be a source of thromboembolism.[6] Aneurysms can be complicated by rupture, outflow tract obstruction, endocarditis or recurrent thromboembolism. Periodic check up with echocardiography is recommended in patients with aneurysm of the membranous interventricular septum, with or without a small ventricular septal defect, as presence of thrombus may justify anti-coagulation or corrective surgery.

The identification of a cardiac lesion requires appropriate medical or surgical management. The risk of recurrence of thrombo-embolic phenomenon is high after the initial event. Warfarin should be instituted for secondary prevention. If the infarction is small it can be instituted soon after the event. Larger infarcts carry a higher risk of haemorrhagic transformation. Anticoagulants should not be started until brain imaging has excluded haemorrhage and usually not until 14 days have passed from the onset of an ischaemic stroke.[7]

References

1. Bogousslavsky J, Pierre P. Ischemic stroke in patients under age 45. *Neurol Clin* 1992; **10**: 113–124.
2. Adams HP Jr, Buttler MJ, Biller J *et al*. Non haemorrhagic cerebral infarction in young adults. *Arch Neurol* 1986; **43**: 793–6.
3. J Trevelyan, RP Steeds. Comparison of transthoracic echocardiography with harmonic imaging with transoesophageal echocardiography for the diagnosis of patent foramen ovale. *Postgraduate Medical Journal* 2006; **82**: 613–614.
4. Jose Salazar, Andres Gutierrez, Eduardo Cay *et al*. Cerebral embolism and thrombus in a membranous interventricular septal aneurysm. *Ann Thorac Surg*, 2003; **76**: 286–7.
5. Gates PC, Barnett HJM, Silver MD. Cardiogenic stroke, in Barnett HJM, Mohr JP, Stein BM, et al (eds): Stroke: Pathophysiology, Diagnosis, and Management, chapter 54. New York, Churchill Livingstone, 1986: 1085–109.
6. Adams Jr HP, Kappelle LJ, Biller J *et al*. Ischemic stroke in young adults. Experience in 329 patients enrolled in the Iowa Registry of stroke in young adults. *Arch Neurol* 1995; **52**: 491–5.
7. Royal College of Physicians. National clinical guidelines for stroke, 2nd edition. Prepared by the Intercollegiate Stroke Working Party. London: RCP, 2004.

© 2007 Rila Publications Ltd.

Acute Medicine_V7_N1.indd 44 9/4/2008 11:38:12 PM