Picture Quiz - Answers

Persistent dysphagia and drowisness following collapse in an alcohol-dependent patient

R Bodington, A Werpachowska & S Faruqi

Keywords
Osmotic demyelination syndrome (ODS), central pontine myelinolysis (CPM), hyponatraemia, alcohol related disease.

Key points

- ODS should be considered in alcoholic or chronically malnourished patients with persistent neurological deficit following normal CT brain.
- Careful monitoring of serum sodium during correction in at risk patients is vital, aiming for correction no faster than 8-10 mmol/L per 24 hrs.
- The presentation, course and prognosis of ODS is highly variable, but many will make a full neurological recovery

Answers

1. What abnormality is shown on the MRI scan?

This T2 weighted MRI scan demonstrates a hyperintense trident shaped lesion extending from the pontomedullary junction to the midbrain with peripheral sparing (figure 2 – abnormality indicated by white arrows).

2. What is the likely diagnosis?

This scan demonstrates the typical appearance of central pontine myelinolysis (CPM). A T1 weighted MRI would demonstrate a hypointense lesion that does not enhance with contrast.

3. What is the cause of this problem and how should the patient be managed?

Central pontine myelolysis is caused by rapid osmotic shifts, in particular rapid correction of hyponatraemia.Our patient's sodium was 111mmol/l at the time of admission and was corrected rapidly following the administration of 3 litres 0.9% saline. His admission presentation may have resulted from a seizure due to the low sodium and alcohol, exacerbated by the effects of aspiration pneumonia. The delay in his recovery, particularly his impaired swallow reflex, led to further investigations being undertaken resulting in the diagnosis of CPM.

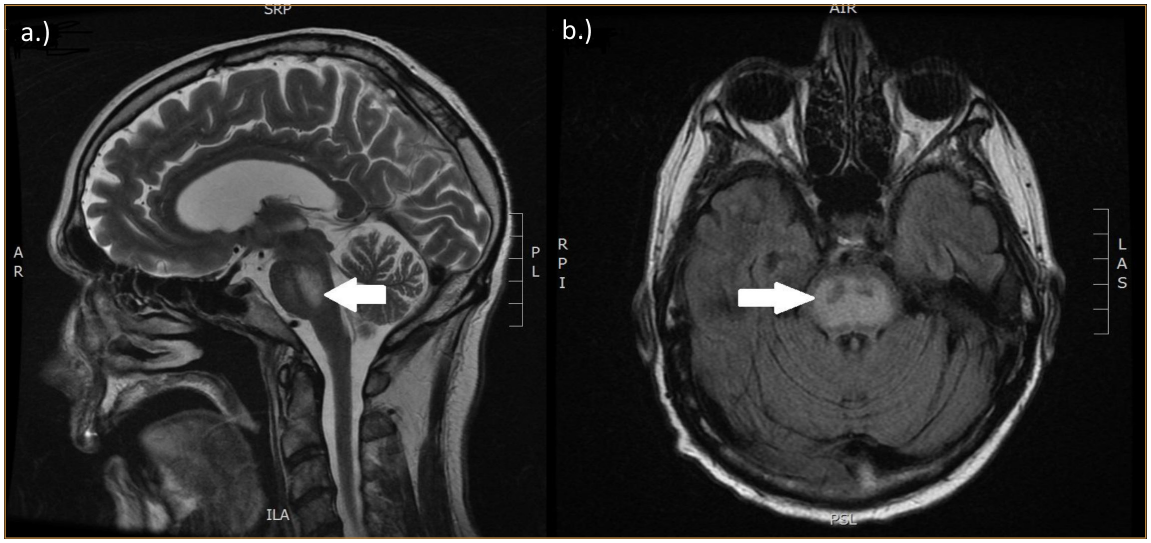

Figure 2. a) Sagittal (midline) and **b)** axial (at the level of the middle cerebral peduncle) T2 weighted MRI images of our patient. Note the classical CPM appearance of a hyperintense trident shaped lesion extending from the pontomedullary junction to the midbrain with peripheral sparing (white arrows).

Richard Bodington
MBBS (Hons)*

Anna Werpachowska
MRCP**

Paul Maliakal
FRCR (Consultant Neuroradiologist)‡

Shoaib Faruqi
MD**

* University Hospitals Coventry and Warwickshire NHS Trust, Department of Renal Medicine, Coventry, United Kingdom
** Hull and East Yorkshire Hospitals NHS Trust, Department of Respiratory Medicine, Hull, United Kingdom
‡ Hull and East Yorkshire Hospitals NHS Trust, Department of Radiology, Hull, United Kingdom

Correspondence:
Richard Bodington
University Hospital Coventry, Clifford Bridge Road, Coventry, West Midlands CV2 2DX
Email: r.bodington@nhs.net

© 2016 Rila Publications Ltd.

Table 1. Presenting symptoms of CPM

Classical presentations	Less common presentations
severe tetraparesis bulbar or pseudobulbar palsy coma locked-in state	dysarthria dysphagia opthalmoplegia

Malnutrition and deranged liver function are recognised risk factors for CPM and make this patient particularly prone to myelinolysis.[1] Rapid correction of hyponatraemia remains the most prevalent aetiology. The pathophysiology is considered due to the movement of free water out of the brain cells, causing a breakdown of the blood-brain barrier, damage of the oligodendrocytes and osmotic demyelination via a mechanism which is not yet clearly understood.[2] The pons is more prone to myelinolysis than any other part of the brain.[3] There have also been case reports of CPM development in patients with hypernatremia, slow correction of hyponatraemia, hypokalaemia, hypoglycaemia and syndrome of inappropriate antidiuretic hormone secretion (SiADH).[4,5,6]

The term osmotic demyelination syndrome (ODS) may be used to describe myelinolysis that occurs in extrapontine sites (extrapontine myelinolysis- EPM).[1,2,6] The clinical presentation of the ODS may vary according to the site and extent of demyelination.Signs and symptoms may be subtle and a high degree of suspicion is needed to make the diagnosis; indeed a significant proportion of ODS may be asymptomatic and present as an incidental finding on MRI or post-mortem.[7-9]ODS generally follows a biphasic course; a non-localising encephalopathy due to hyponatraemia is often followed by a period of relative improvement before more significant manifestations appear.[10-11] CPM classically presents with one, or a combination of, severe tetraparesis, bulbar or pseudobulbar palsy, coma or a locked-in state (Table 1).[10,11] Cognitive dysfunction is also common and may be due to extra-pontine myelinolysis in the frontal subcortical region not seen on MRI. The ODS itself also evolves through various stages; for example initial spastic tetraparesis may evolve into an akinetic rigid state and then into dystonia.[10]

The diagnosis of ODS is usually made by MRI scanning, as in this case, where a T2 weighted MRI scan typically demonstrates a hyperintense trident shaped lesion extending from the pontomedullary junction to the midbrain with peripheral sparing (figure 2). There is no specific treatment for ODS. Supportive measures, prevention of complications and subsequent rehabilitation form the key to a good recovery.[10,11] Methylprednisolone has been used with some success in small non-randomised studies as has the rescue re-introduction of hyponatraemia [12,13]. Primary prevention is vital in this condition with the focus not so much on the absolute sodium level but on the avoidance of hyerosmolarity and rapid osmotic shifts, particularly in high risk patients.[10,14] Hyponatremia should be corrected at a rate of no more than 8-10 mmol/L of sodium per day.[15] Fluid challenge with normal saline if the difference between hypovolemic and euvolemic hyponatraemia is not clear is a perfectly valid approach. However it is very important that serum sodium is diligently monitored, and junior doctors in a busy acute medical unit should be aware of this possible complication. In our case the

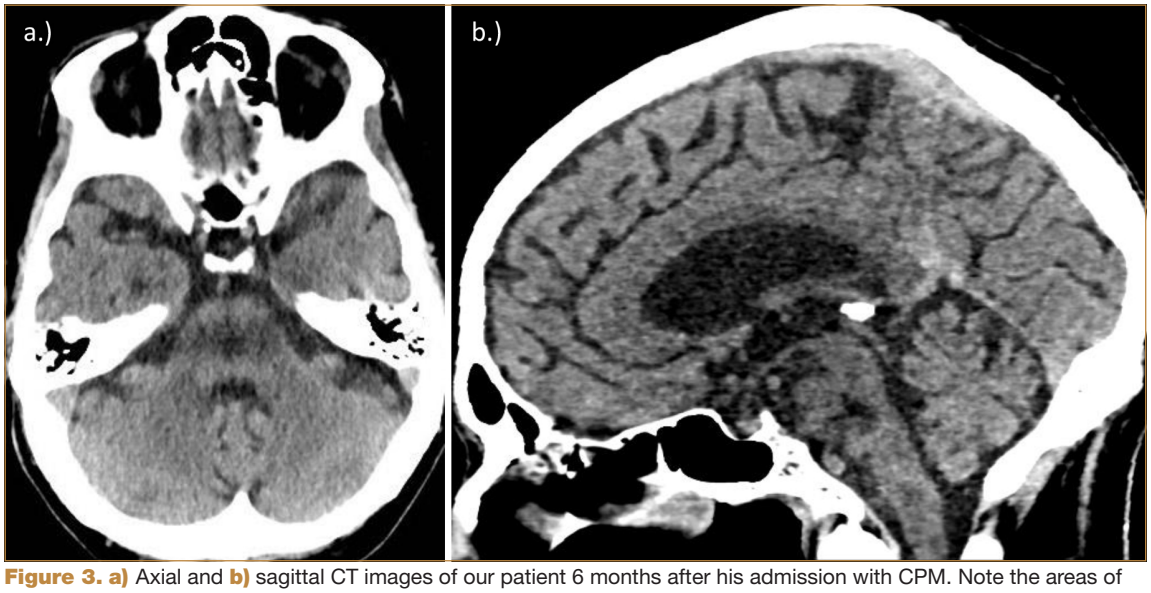

Figure 3. a) Axial and **b)** sagittal CT images of our patient 6 months after his admission with CPM. Note the areas of hypoattenuation in the pons consistent with the changes of chronic CPM.

© 2016 Rila Publications Ltd.

serum sodium was corrected from 111 mmol/L to 132 mmol/L in 42 hours. This appears to give a rate of correction only slightly over the recommended upper limit of correction of 10 mmol/L per 24 hrs. However the serum sodium was not measured on the day after admission but only after 42 hrs and therefore we cannot know the speed of correction in the first 24 hrs. If the rate of sodium correction had been monitored more closely, ideally 12 hours after the first set, action could have been taken regarding the choice of intravenous fluid and the precipitation of CPM may have been avoided.

The prognosis of patients with CPM is much less gloomy than had been previously thought when the majority of cases were diagnosed on post mortem examination. In one case series, 6% of patients died, usually as a result of secondary complications . Of the survivors 28-39% made a full recovery and 16-34% regained independence for activities of daily living. The initial severity of the illness and the resolution of the lesion on imaging had no impact on prognosis [16]. Poorer prognosis was seen in chronic alcoholism and other comorbidities as were seizures and altered consciousness at presentation.[10.16]

Outcome

From the neurological perspective our patient improved completely over a period of five weeks. The nasogastric tube was removed after 25 days and he was eating normally at the time of discharge, at which time serum electrolytes were also normal.

Retrospective review of his blood tests over the previous two years revealed that his serum sodium had been variable with several low recordings at 120 mmol/L noted at the time of previous admissions to hospital. He was admitted six months later with a further alcohol-related collapse at which time serum sodium of 122 mmol/L was noted; again this normalised on discharge. A CT brain scan at this time demonstrated pontine changes consistent with chronic CPM (figure 3) although neurological examination at that time was normal.

References

1. Saša A Živković. Neurologic complications after liver transplantation, World J Hepatol. 2013 August 27; **5(8)**: 409–416
2. Norenberg MD. Central pontine myelinolysis: historical and mechanistic considerations. *Metab Brain Dis.* 2010; **25**:97–106
3. Heckmann JG, and Dinkel HP. Recovery of locked-in syndrome in central pontine myelinolysis. *Am J Case Rep.* 2013; **14**: 219–220.
4. Adrogue HJ, Madias NE. Hypernatremia. N Engl J Med. 2000; **342**:1493–1499.
5. Koul PA, Khan UH, Jan RA, Shah S, Qadri AB, Wani B, Ashraf M, Ahmad F, and Bazaz SR, Osmotic demyelination syndrome following slow correction of hyponatremia: Possible role of hypokalemia, *Indian J Crit Care Med.* 2013 Jul-Aug; **17(4)**: 231–233.
6. Brown WD. Osmotic demyelination disorders: Central pontine and extrapontine myelinolysis, *Curr Opin Neurol.*, 2000; 13:691–7.
7. Buis CI, Wijdicks EF. Serial magnetic resonance imaging of central pontine myelinolysis. *Liver Transpl.* 2002; **8**:643–645
8. Lampl C, Yazdi K "Central pontine myelinolysis". *Eur. Neurol.*2002; **47 (1)**: 3–10.
9. Strube MU, Steck AJ, Fuhr P. Asymptomatic central pontine myelinolysis. *Neurology*. 1999; **53**:914
10. de Souza A, Movement disorders and the osmotic demyelination syndrome, *Parkinsonism Relat. Disord.* 2013 Aug;**19(8)**:709-16.
11. Kallakatta RN, Radhakrishnan A, Fayaz RK, Unnikrishnan JP, Kesavadas C, Sarma SP. Clinical and functional outcome and factors predicting prognosis in osmotic demyelination syndrome (central pontine and/or extrapontine myelinolysis) in 25 patients. *J Neurol Neurosurg Psychiatry* 2011; **82**:326e31.
12. Nishino K, Yasuda T, Kowada M. A case of central pontine myelinolysis with neurological recovery after administration of glucocorticoid. *No To Shinkei* 1991; **43**:483-8.
13. Oya S, Tsutsumi K, Ueki K, Kirino T. Reinduction of hyponatremia to treat central pontine myelinolysis. *Neurology* 2001; **57**:1931-2.
14. Musana AK, Yale SH. Central pontine myelinolysis: case series and review. *WMJ*, 2005;**104**:56-60.
15. de la Cour KD. Central pontine myelinolysis,*Ugesk Laeger.* 2013 Sep 23;**175(39)**:2247-2250.
16. Martin RJ. Central pontine and extrapontine myelinolysis: the osmotic demyelination syndromes. *J Neurol Neurosurg Psychiatry* 2004; **75**:iii22e8.

© 2016 Rila Publications Ltd.