Picture Quiz - Answers

Abnormal cardiac conduction in a septic patient: incidental finding or cause for concern?

Jackson M & Balasubramaniam K

Keywords
Aortic valve (AV) endocarditis; aortic root abscess; atrioventricular block

Key points

- Aortic valve endocarditis should be considered in septic patients with evidence of significant cardiac conduction disease
- Careful monitoring for PR interval prolongation is vital to allow early detection of complications of AV endocarditis such as aortic root abscess.
- Urgent cardiac surgery is recommended for aortic root abscess; however, there is a high chance of permanent pacemaker implantation

Answers

Question 1: ECG interpretation

The initial ECG (figure 1A) demonstrates a regularly irregular rhythm at approximately 80bpm. There is a profound first-degree atrioventricular(AV) block with a PR interval of over 400ms. There is monomorphic ventricular ectopy in a right bundle branch pattern. The baseline QRS complexes are narrow.

The repeat ECG (figure 1B) has a rate of 56 bpm and demonstrates prolongation of the QRS complex (duration 146ms) in a left bundle branch morphology (QRS). There are only intermittent P waves visible even accounting for the wandering baseline. This may represent a junctional bradycardia or a ventricular escape rhythm.

The third ECG (figure 1C) demonstrates a prolonged episode of ventricular standstill.

Question 2: What is the likely diagnosis and how should this be managed?

The patient was commenced on an isoprenaline infusion and suffered no further episodes of ventricular standstill during transfer to the tertiary cardiothoracic centre. Transthoracic echocardiography then demonstrated torrential aortic regurgitation (AR) and appearances in keeping with an aortic root abscess and the patient was referred for urgent cardiothoracic surgery.

This was performed within 24 hours of initial presentation to hospital. Peri-operative transoesophageal echocardiography demonstrated almost complete detachment of the non-coronary cusp (figure 2A) with a resulting flail leaflet (figure 2B) and torrential AR (figure 2C). It also demonstrated severe mitral regurgitation, large (> 1cm) vegetations on both the aortic and mitral valves and a fistula between the left ventricular outflow tract and the right atrium. The patient underwent aortic root and

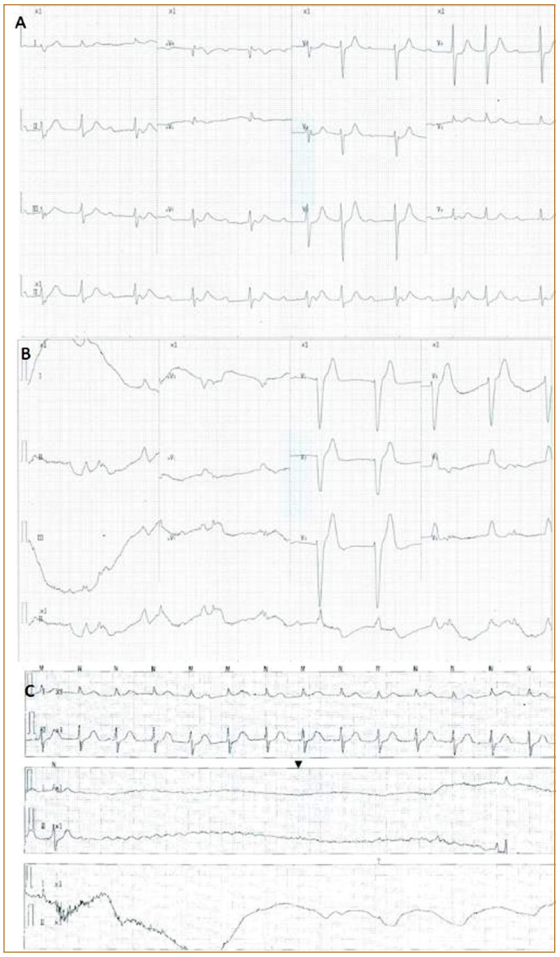

Figure 1. A – ECG performed in emergency department. **B –** Subsequent ECG performed on coronary care unit. **C –** Telemetry tracing showing ventricular standstill.

Jackson M
MBChB

Balasubramaniam K
MBBS PhD

The James Cook University Hospital, Middlesbrough, United Kingdom, TS4 3BW

Corresponding author
Matthew Jackson
The James Cook University Hospital
Marton Road
Middlesbrough
TS4 3BW
Email: matthew.jackson8@nhs.net / mwpjackson@gmail.com

© 2018 Rila Publications Ltd.

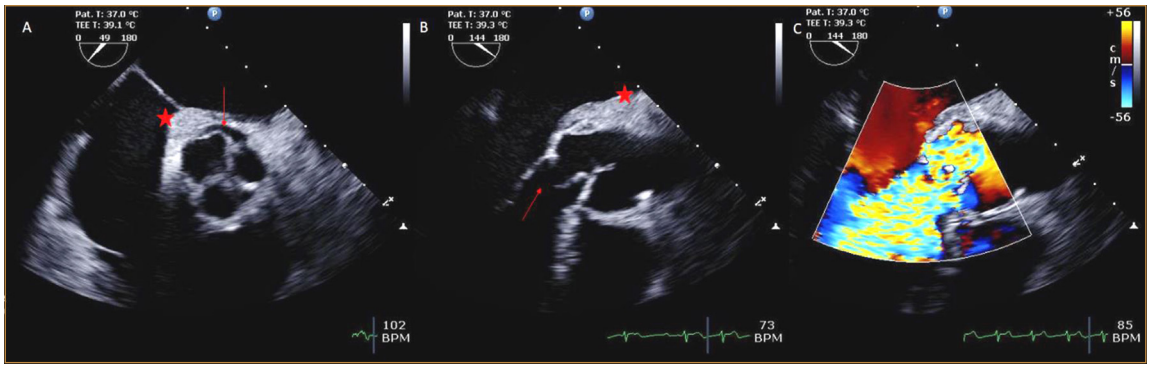

Figure 2. A - Transoesophageal echocardiography (TOE) showing detachment of non-coronary cusp (arrow) and aortic root abscess (star). **B –** TOE showing long-axis view of aortic valve with flail non-coronary cusp (arrow) and aortic root abscess (star). **C –** Same view with colour doppler demonstrating torrential aortic regurgitation

valve replacement, mitral valve repair and oversew of the fistula with a pericardial patch without immediate complication. Post-operatively, there was no underlying heart rhythm and on day 4, a dual chamber permanent pacemaker was implanted. Cultures subsequently grew Streptococcus Pneumoniae and a six-week course of benzylpenicillin was commenced.

Atrioventricular block is reported in up to 40% of patients with endocarditis, commonly involving the aortic valve either in isolation or with other valvular lesions, and is a sign of perivalvular extension of the infection.[1-4] In the aortic region, this abscess formation occurs most frequently in the mitral-aortic intervalvular fibrosa, in close proximity to the bundle of His.[5] In particular, the inferior aspect of noncoronary cusp (the cusp most affected in our patient), overlies the interventricular septum along which the bundle branches run. The presence of AV block alone has a specificity of 97% to detect aortic perivalvular extension;[4] if confirmed, current guidelines recommend early cardiac surgery during the initial hospitalisation before completion of a full therapeutic course of antibiotics.[6, 7]

The decision to proceed with early pacemaker implantation for persistent pacemaker dependence has to be balanced against the potential for infection. Pacemaker dependence rates after aortic valve surgery in a meta-analysis of 780 patients are reported between 32 and 70% up to 3 years after surgery.[8] They suggest patients with prolonged PR and QRS intervals, pre-operative LBBB and persistent complete heart block predict the need for long-term pacing; a long aortic cross-clamp time was associated with immediate post-operative pacemaker requirement but not long-term dependence. Our patient exhibited all these features and a permanent pacing system was therefore implanted early in the clinical course rather than waiting for recovery of intrinsic conduction.

Conclusion

The presence of profound and/or high-degree atrio-ventricular delay in the septic patient should raise clinical suspicion of aortic valve endocarditis. Even if not present on presentation, it can develop during the clinical course and regular ECG monitoring is recommended, triggering prompt investigation if detected especially in the presence of a typical microbiologic organisms. Urgent surgical intervention is the recommended treatment strategy for aortic root abscess with a high chance of requiring permanent pacing post-operatively.

Competing interest

No conflicts of interest or financial disclosures for either author.

References

1. Wang K, Gobel F, Gleason DF, Edwards JE. Complete Heart Block Complicating Bacterial Endocarditis. *Circulation.* 1972; **46**: 939 – 947
2. DiNubile MJ, Calderwood SB, Steinhaus DM, Karchmer AW. Cardiac Conduction Abnormalities Complicating Native Valve Active Infective Endocarditis. *Am J Cardiol.* 1986; **58**: 1213-7
3. Leung DY, Cranney GB, Hopkins AP, Walsh WF. Role Of Transoesophageal Echocardiography In The Diagnosis And Management Of Aortic Root Abscess. *Br Heart J.* 1994; **72**: 175 – 181
4. Graupner C, Vilacosta I, San Roman J *et al.* Periannular Extension Of Infection Endocarditis. *J Am Coll Cardiol.* 2002; **39**: 1204 – 1211
5. Forteza A, Centeno J, Ospina V *et al.* Outcomes In Aortic And Mitral Valve Replacement With Intervalvular Fibrous Body Reconstruction. *Ann Thorac Surg* 2015; **99**: 838-845
6. Habib G, Lancellotti P, Antunes MJ *et al* (ESC Scientific Document Group). *Eur H Journal.* 2015; **36**; 3075-3128
7. Nishimura RA, Otto CM, Bonow RO *et al.* 2017 AHA/ACC Focussed Update Of The 2014 AHA/ACC Guideline For The Management Of Patients With Valvular Heart Disease: A Report Of The American College Of Cardiology/American Heart Association Task Force On Clinical Practice Gudelies. *Circulation.* 2017;**135**: e1159 - e1195
8. Steyers III CM, Khera R, Bhave P. Pacemaker Dependence After Cardiac Surgery: A Systematic Review Of Current Evidence. *PLoS One.* 2015; **10**: e140340

© 2018 Rila Publications Ltd.