Case Reports

Actinomycosis masquerading as malignancy

D O'Riordan, A Zermansky, P Bishop & S C.O. Taggart

Abstract

We describe a patient who presented with neurological symptoms and radiological findings consistent with metastatic malignancy in several sites. However, no obvious primary site of tumour was identified and the patient later went on to develop clinical features of sepsis whilst using palliative dexamethasone therapy. A diagnosis of actinomycosis was eventually made on open lung biopsy and the patient recovered completely on penicillin V. This case serves to illustrate the need to obtain a formal tissue diagnosis whenever possible in all cases of suspected malignancy, in addition to exposing the weaknesses inherent in empiric diagnoses.

Keywords

Actinomycosis, cord compression, headache, pulmonary nodules

Key Points

- Beware inherent weaknesses of clinical and empiric diagnoses
- In difficult diagnoses of possible infection, consider specific stains or culture media.
- Actinomycosis can present in any system, including as an uncommon cause of cavitatory pulmonary nodules.
- Always consider confirming diagnoses histologically even with strong radiological features of metastases.

Dr Devaki O'Riordan[1]
MRCP, Specialist Registrar in Respiratory Medicine

Dr Adam Zermansky[1]
MRCP, Consultant Neurologist

Dr Paul Bishop[2]
FRCPath, Consultant Histopathologist

Dr Simon C.O. Taggart[1]
FRCP, Consultant Respiratory Physician

[1] Salford Royal Hospital, Stott Lane, Salford, Manchester, UK.
[2] University Hospital of South Manchester, Southmoor Road, Wythenshawe, Manchester, UK

Correspondence:
Dr Devaki O'Riordan, Dept of Respiratory Medicine, Salford Royal Hospital, Stott Lane, Salford, Manchester, UK M6 8HD
Email: devakignan@yahoo.co.uk

Case Report

A 56 year old woman presented to the Acute Medical Unit (AMU) with a 4 day history of temporal headache and diplopia. On examination, a right 6th nerve palsy and a non-tender palpable temporal artery were detected but there were no other abnormal neurological signs. Previously, the patient had been fit and well despite a 30 pack-year smoking history and worked as a furniture sales assistant.

Investigation confirmed an elevated ESR (59mm/hr) with normal full blood count, plain chest radiograph, brain computed tomogram scan (CT), vasculitic screen and lumbar puncture. A diagnosis of giant cell arteritis with atypical presentation was made and treatment with prednisolone 60mg daily commenced. The headache subsided within 24 hours and the patient was discharged on tapering doses of steroid.

Follow-up magnetic resonance imaging (MRI) brain scan to clarify the cause of the 6th nerve palsy revealed an abnormal marrow of the clivus (base of skull) with epidural enhancing soft tissue. Pathology considered included malignant metastases, myeloma or meningioma. Urine protein electrophoresis was normal. And although a mammogram revealed a small cyst in the left breast, fine needle aspiration revealed benign cells only.

A subsequent CT body scan showed multiple bilateral small lung nodules (approximately 3-8mm in diameter), some of which were cavitating (Figure 1).

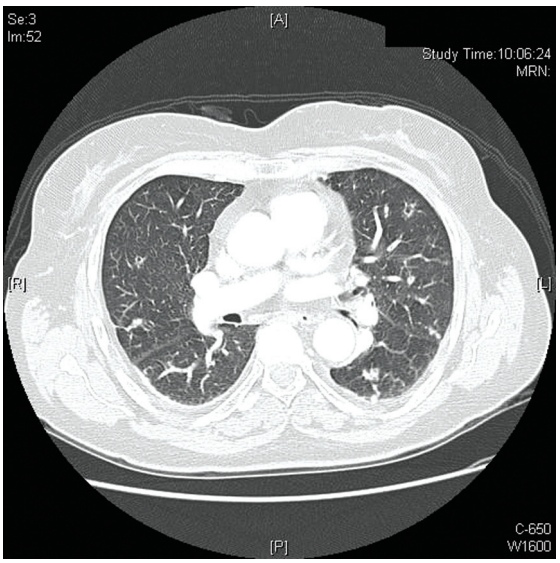

Figure 1. Thoracic CT showing multiple pulmonary nodules, some of which are cavitating.

Her case was discussed at a multidisciplinary meeting and it was felt that she would benefit from a histological diagnosis. However, a thoracotomy to further investigate these lesions was declined by the patient and with an empiric diagnosis of metastatic malignancy, a palliative treatment strategy with low dose dexamethasone to help improve her appetite, vitality and 6th nerve palsy was pursued, pending further outpatient review.

© 2012 Rila Publications Ltd.

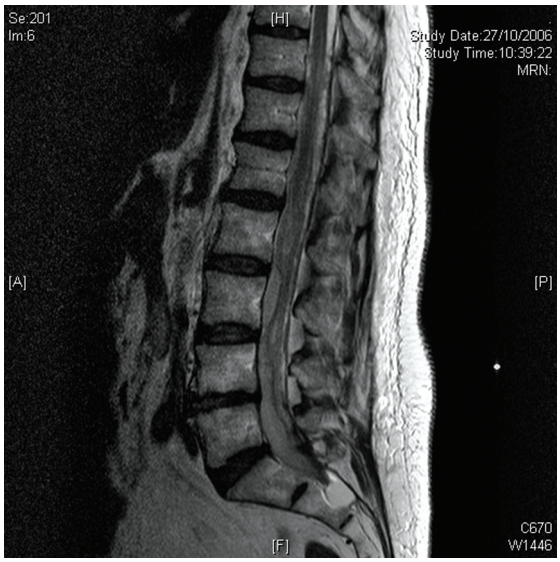

Figure 2. MRI of spine showing matting of nerve roots in cauda equina.

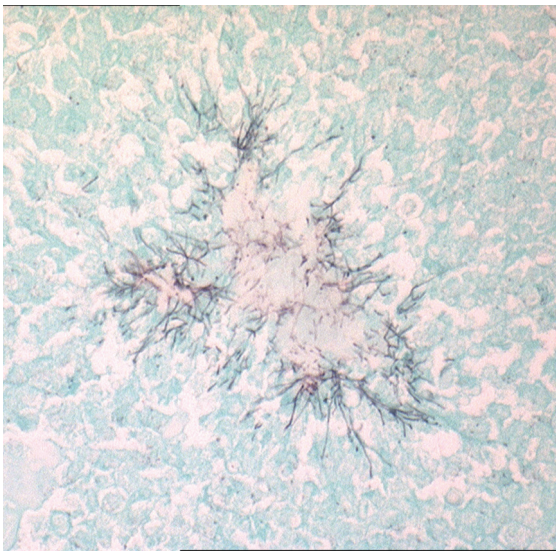

Figure 3. Grocott Stain section taken from open lung biopsy showing a colony of filamentous Actinomycetes organisms (objective x40).

Two months later, the patient represented to the AMU with acute back pain, burning sensations down the lateral aspects of both legs, dysuria and disorientation. On examination the patient was pyrexial at 38.7°C, with a clear chest and oxygen saturations of 94% on air. Glasgow Coma Score was 13, with no spinal tenderness, normal anal tone and sensation and brisk knee reflexes with no other lower limb neurological abnormality. Investigations demonstrated an ESR of 35mm/hr, white cell count 16 x10^9/L (neutrophils 14.6 x 10^9/L), CRP 166mg/L; other bloods tests including serum calcium were normal. Plain chest radiograph and urine culture showed no abnormalities. A repeat brain CT scan was normal and lumbar puncture was unsuccessful despite several attempts.

Treatment for sepsis of unknown cause with broad spectrum antibiotics (piperacillin with tazobactam) and antivirals (acyclovir) was commenced. A gram-positive micrococcus was isolated from the blood but believed to be a contaminant as it was present in only one bottle out of several blood culture samples. An MRI scan of the spine demonstrated matting of the cauda equina, consistent with malignancy (Figure 2). Pus was liberated from this area on surgical examination under general anaesthesia and simultaneous biopsy revealed chronic inflammation. No neoplastic cells or acid-fast bacilli were found but coagulase negative Staphylococci were cultured.

The antibiotics were switched to cefotaxime and metronidazole due to persistent symptoms of fever, leg pains and elevated CRP (82mg/L), with a concomitant reduction in her steroid dose. Further tests results included normal brucella serology, a negative (0mm) Mantoux test and a bronchoscopic lavage which yielded Enterobacter cloacae.

Finally, a left open lung biopsy was performed. Variable sized abscesses with cavitating areas and inflammatory cells amid colonies of filamentous actinomycetes-like organisms were revealed (Figure 3). These were positive on periodic acid-Schiff (PAS) staining and negative on Ziehl-Nielsen staining, consistent with Actinomycosis infection.

Treatment with Penicillin V 500mg qds was commenced with simultaneous corticosteroid withdrawal. Complete resolution of symptoms were reported within 3 months. A repeat CT chest scan and MRI scan of the spine were normal, 3 months after completing 12 months antibiotic treatment.

Discussion

Actinomyces are branching filamentous gram-positive anaerobic bacteria, which require enriched media in which to grow in vitro. Human actinomycosis is primarily caused by *A. israelii* and can cause multisystem disease, particularly with craniofacial, abdominal, central nervous system, thoracic and pelvic involvement. Rarely, it also invades bone, meninges and brain, by contiguous spread along connective tissue planes. Actinomyces are commensals of the digestive and vaginal tracts, and disease occurs by direct invasion of tissues (often where mucosal barriers have been damaged), aspiration or haematogenous spread, hence presenting as chronic abscesses, fistulae or soft tissue masses, developing over weeks to months. It is often described in association with poor dental hygiene, but this was not case with this patient.

Actinomycosis is an uncommon infection with worldwide distribution and is more common in middle age and in males. It does not have a predilection for immunocompromised individuals[1]

© 2012 Rila Publications Ltd.

and it is impossible to comment on whether the use of steroids in the case described contributed to the progression of infection. This patient was HIV-negative. As a furniture sales assistant, this patient spent time assembling and unpacking pine and oak. Interestingly Actinomyces are also wood-inhabiting microorganisms which contribute to wood decay,[2] although there is no evidence that working with wood predisposes humans to this infection.

In this condition, the challenge is to consider the diagnosis early enough to avoid unnecessary invasive procedures and to reduce morbidity and mortality.[3] This patient's diagnosis was delayed both because a diagnosis of malignancy was assumed to be correct, and because actinomyocosis was not considered specifically as a differential diagnosis. Requesting culture on enriched media for extended periods in 6-10% ambient carbon dioxide[4] may have helped to make the diagnosis earlier, and it is possible that the gram positive cocci grown from blood cultures were in fact Actinomyces.

As in most cases of this condition, diagnosis was eventually made on histopathological features. It is difficult to distinguish Actinomyces from Nocardia species on PAS and gram stains, but they differ on haematoxylin & eosin staining, with Actinomyces filaments characteristically looking basophilic with terminal eosinophilic clubs.[5] In addition, Actinomyces are not acid fast, though Nocardia are partially so.

Actinomycosis tends to present as mass lesions at the site of infection and is often mistaken for malignancy.[6,7] Pus is characteristically yellow or brown with typical green-yellow "sulphur" granules.[8] However, there was no description noted of the nature of the pus seen at surgery in this case.

Spinal cord compression is a feature in less than 5% of actinomycosis infections.[9] Back pain is the most consistent feature here and neurological dysfunction can progress variably over hours to months, whilst delay in diagnosis can result in irreversible damage. This patient's lumbar puncture was difficult due to the mass lesion in that area, but CSF would normally show an elevated protein level and later a decreased glucose level in actinomycosis infection.[10]

Actinomycosis is not commonly featured on lists of differential diagnoses for causes of cavitating pulmonary nodules, which was another contributing factor to the delay in diagnosis in this case. We propose that it should be widely acknowledged as a differential diagnosis of malignant metastases, including pulmonary secondaries.

This condition is treated with prolonged antibiotics, the first choice being penicillin,[3] with or without surgical debridement. For penicillin allergic patients, tetracyclines, clindamycin, erythromycin and cephalosporins have all been used successfully to treat it.[11]

This case highlights the need to question diagnoses when they do not fit together well, and the need for physicians to be more aware of actinomycosis, a curable condition, as a mimick of malignancy.

References

1. Dominguez DC, Anthony SJ. Actinomyces and Nocradia infections in immunocompromised and nonimuunocompromised patients. *J Natl Med Assoc* 1999; **91:** 35-9.
2. Greaves H. The bacterial factor in wood decay. *Wood Science and Technology* 1971; **5:** 6-16.
3. Smego Jr R, Foglia G. Actinomycosis. *Clin Infect Dis* 1998; **26:** 1255-61.
4. Oostman O, Smego Jr R. Craniofacial actinomycosis: diagnosis and management. *Curr Infect Dis Reports* 2005; **7:** 17-174.
5. Russo TA. Agents of actinomycosis. In: Mandell GL, Bennett JE, Dolin R, eds. Principles and practice of infectious diseases. 7th ed. *Elsevier Churchill Livingstone*, 2010: 3209-19.
6. Acevedo F, Baudrand R, Letelier L, Gaete P. Actinomycosis: a great pretender. Case reports of unusual presentations and a review of the literature. *Int J Infect Dis* 2008; **12:** 358-362.
7. Lohani S, Chadwick P, Armstrong G, BR O'Driscoll, Taggart SCO. Endobronchial mimics of lung cancer. *Journal of Bronchology* 2005; **12(1):** 56-58.
8. Tastepe AI, Ulasan NG, Liman ST *et al*. Thoracic actinomycosis. *Eur J Cardiothoracic Surg* 1998; **14(6):** 578-83.
9. Espina MA, Lopez-Menendez C, Ruiz-Martinez R *et al*. Pulmonary actinomycosis with thoracic soft tissue mass: a rare onset form. *Eur J Radiol* 2001; **37:** 195-9.
10. Xu GP, Xu ZD Gao BL *et al*. Cervical actinomycosis with spinal cord compression. *Chemotherapy* 2008; **54:** 63-66.
11. Martin MV. Antibiotic treatment of cervicofacial actinomycosis for patients allergic to penicillin: a clinical and in vitro study. *Br J Oral Maxillofac Surg* 1985; **23:** 428-34.

© 2012 Rila Publications Ltd.