*Case Report*

# Ventricular tachycardia and raised troponin: "What if it's a pheochromocytoma"? Some lessons from a crisis

J Lazari, N Jolapara & C Whelan

## Abstract

A 63-year-old female with cardiovascular risk factors presented with tremor, sweating, lower back discomfort, nausea and dyspnoea. Electrocardiogram showed sinus tachycardia with lateral ST-depression. High-sensitivity troponin-T was dynamically elevated (72ng/L to 112ng/L on one-hour repeat). Overnight, there was an episode of ventricular tachycardia with further troponin rise to 364ng/L. Coronary angiogram demonstrated non-obstructive coronary artery disease. Post-procedure, the patient developed a hypertensive crisis with pulmonary oedema (invasive blood pressure 350/140mmHg). This was managed with intravenous phentolamine. Ondansetron and metoclopramide were given for intractable vomiting. A pheochromocytoma was subsequently confirmed and surgically excised. Our experience in this case generated several important learning points that we hope may be of benefit to others who encounter suspected pheochromocytomas on the acute medical take.

## Keywords

Pheochromocytoma, hypertensive crisis, arrhythmia, myocardial injury, acute coronary syndrome

## Key points

- Invasive procedures, including coronary angiography, can trigger a hyperadrenergic crisis in those with a pheochromocytoma.
- Suggested treatment of a pheochromocytoma hypertensive emergency is with IV phentolamine.
- Metoclopramide is contraindicated in those with a pheochromocytoma.
- Consider an admission for continuous cardiac monitoring in those presenting acutely with a suspected pheochromocytoma in whom you suspect arrhythmia.
- A persistent tachycardia should raise concern that a patient with a suspected pheochromocytoma is in a hyperadrenergic state.

## Case Report

A 63-year-old female presented via ambulance to the Heart Attack Centre of a London (UK) hospital. The history was of a gradual onset in feeling "shaky all over", with some lower back discomfort, intermittent headache, nausea, sweating and dyspnoea. There was no chest pain. Previous medical history included renal artery stenosis (diagnosed at age 18 and treated with a left spleno-renal artery bypass) and subsequently well controlled systemic arterial hypertension. There was a family history of vascular disease with both parents having had a stroke or myocardial infarction before the ages of 60. Initial examination was unremarkable, and vital signs were as follows: heart rate 112 beats per minute (bpm), blood pressure 126/70mmHg, oxygen saturations 95% (on room air) and temperature 37.3°C. Electrocardiogram (ECG) demonstrated sinus tachycardia with lateral ST-depression. A focused bedside echocardiogram showed good left ventricular systolic function with left ventricular hypertrophy, no regional wall motion abnormalities and visually moderate aortic regurgitation. The impression was therefore that this did not represent an acute coronary syndrome, and so the patient was referred to the acute medical team.

Given the history of lower back pain and aortic regurgitation on echocardiogram, a computed tomography (CT) aortogram was performed. This ruled out aortic dissection but did identify a 6.6cm thick walled lesion arising from left adrenal gland with fluid density and no clear arterial phase enhancement (Figure 1). Notable blood results are in Table 1. In view of the dynamically elevated troponin-T, the cardiology team re-reviewed the patient, and suggested a diagnosis of arrhythmia with myocardial injury accounting for the troponin rise, with a possible pheochromocytoma being the trigger. Whilst awaiting plasma metanephrine levels, the patient was initiated on doxazosin 4mg once daily.

**Jonathan Lazari**
BSc MBBS MRCP

**Nikita Jolapara**
BSc MD

**Carol Whelan**
BSc MBChB MD MRCP

Royal Free Hospital, London, UK

**Correspondence**
Jonathan Lazari
Royal Free Hospital, London, UK, NW3 2QG.
Email: j.lazari@doctors.net.uk

© 2021 Rila Publications Ltd.

# *Ventricular tachycardia and raised troponin: "What if it's a pheochromocytoma"? Some lessons from a crisis*

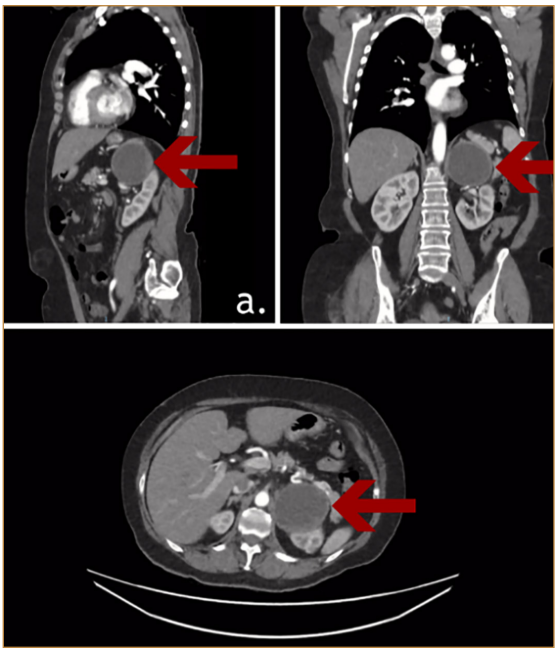


**Figure 1.** Admission CT-aortogram with contrast demonstrating 6.6cm thick-walled lesion arising from the left adrenal gland. It has a fluid density and no arterial phase enhancement. The lesion is demonstrated in sagittal (a), coronal (b) and axial (c) slices

Overnight, an episode of ventricular tachycardia was captured on telemetry which lasted approximately one minute at a rate of 236bpm. High-sensitivity troponin-T was now 364ng/L. Given the ventricular arrhythmia and rising troponin in a patient with vascular risk factors, they were started on aspirin (300mg orally) and clopidogrel (300mg orally). Following a discussion between the cardiology and endocrinology team, the patient underwent a coronary angiogram via the right radial artery. This was uncomplicated and showed non-obstructive and mild coronary artery disease only.

Approximately one-hour post-procedure the patient developed tachyarrhythmias, tremor, nausea and vomiting. Telemetry and 12-lead ECG captured self-terminating runs of ventricular tachycardia (rate 218bpm), supra-ventricular tachycardia (rate 163bpm) and sinus tachycardia (rate 127bpm) (Figure 2). Non-invasive blood pressure was 158/76mmHg. Ondansetron (4mg intravenously) was given for the nausea, but the patient continued to vomit, and so

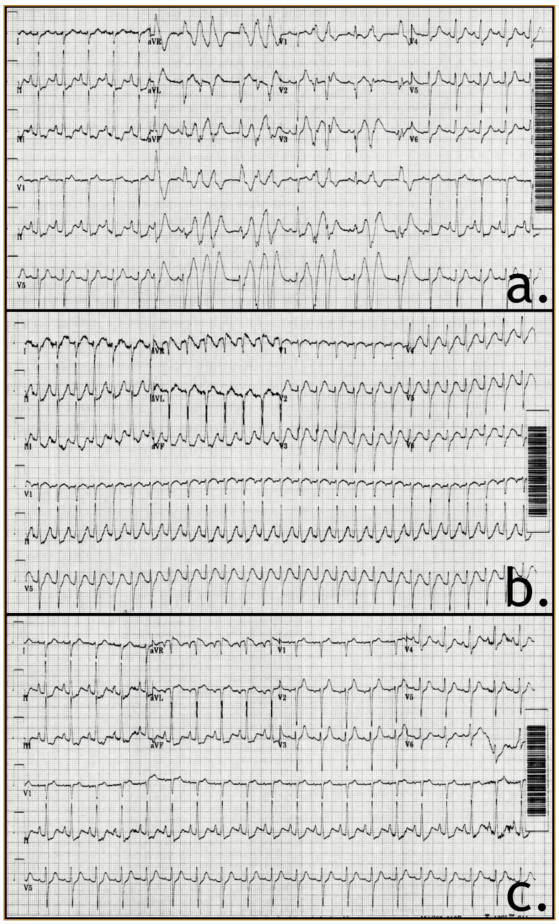


**Figure 2.** 12-lead ECGs from during the pheochromocytoma crisis. Demonstrates salvos of ventricular ectopics (a), supraventricular tachycardia (b) and sinus tachycardia with infero-lateral ST-depression (c)

intravenous metoclopramide (10mg) was additionally administered. Clinically, the patient was becoming more unwell, with an increasing oxygen requirement, bi-basal crackles on auscultation of the lung fields, and a rising venous lactate (from 4.4mMol/L to 7.0mMol/L). Given the acuity of this rise over less than an hour, it was felt this likely represented worsening end organ perfusion secondary severe hypertension being underappreciated via a non-invasive blood pressure cuff. However, other causes for a high lactate are always possible, and notably in this case would include catecholamine-mediated glycolysis (*i.e.* a type B1 lactic acidosis as opposed to a type A).[1] Invasive

**Table 1.** Notable blood results from admission (normal ranges in brackets).

| Venous pH | Venous lactate | Venous base excess | Haemoglobin | White cell count | Neutrophil count |
|---|---|---|---|---|---|
| 7.38 (7.32 – 7.43) | 4.1mMol/L (0.5 – 2.2) | -3.8mMol/L | 135g/L (115 - 165) | 16.6x$10^9$ (4 - 11) | 14.67 x$10^9$/L (2 - 7.5) |
| **Lymphocyte count** | **C-reactive protein** | **Sodium** | **Potassium** | **Creatinine** | **hsTroponin-T** |
| 0.9 x$10^9$/L (1 - 4) | 10mg/L (0 – 9.9) | 141mMol/L (135 - 145) | 3.7mMol/L (3.5 – 5.1) | 98µMol/L (66 - 112) | Admission: 72ng/L 1-hour: 112ng/L (<15) |

© 2021 Rila Publications Ltd.

# *Ventricular tachycardia and raised troponin: "What if it's a pheochromocytoma"? Some lessons from a crisis*

**Table 2.** Plasma and urine metanephrine results (normal ranges in brackets).

| Plasma adrenaline | Plasma noradrenaline | 24-hour urine metadrenaline output | 24-hour urine normetadrenaline output |
|---|---|---|---|
| 13.6nmol/L (0 – 0.8) | 17.49nmol/L (0 – 5) | 149.31 (0 – 12) | 20.18 (0 – 3.3) |

monitoring was therefore established via a left radial artery line. The patient's invasive blood pressure was 350/140mmHg. This, in conjunction with the clinical picture of pulmonary oedema, confirmed a diagnosis of hypertensive crisis. Intravenous phentolamine boluses (5mg) were given, with successful reductions in invasive blood pressure, before beginning a phentolamine infusion. Oral phenoxybenzamine (10mg) was concomitantly started. The patient was successfully weaned off the phentolamine infusion overnight, phenoxybenzamine was continued, and there was no further arrhythmia or hypertensive issues during the admission.

The diagnosis of pheochromocytoma was later confirmed biochemically with markedly elevated levels of plasma and urine metanephrines (Table 2). A metaiodobenzylguanidine (MIBG) scan showed increased uptake within the left adrenal mass with no evidence of metastatic disease (Figure 3). This was scheduled for later surgical resection after two weeks of alpha blockade. The operation was undertaken successfully without surgical complication. Post-operative recovery involved three days on the Intensive Care Unit, with a ventilator associated pneumonia during that time. Histopathology of the excised lesion confirmed a left adrenal haemorrhagic pseudocyst arising from within a pheochromocytoma.

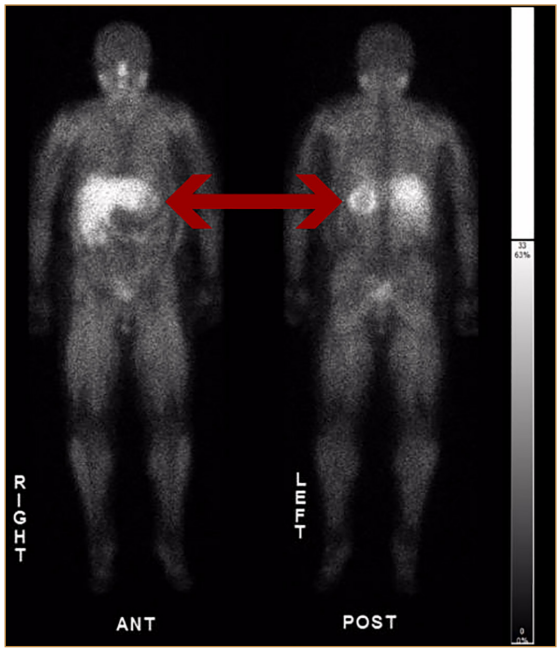


**Figure 3.** MIBG scan demonstrating increased isotope uptake in the lesion previously seen arising from the left adrenal gland. There is no evidence of metastatic disease

## Discussion

Pheochromocytomas are usually benign tumours, arising from the chromaffin cells in the adrenal medulla or a paraganglion.[2] The vast majority are hormonally active, secreting catecholamines.[2] The resulting hyperadrenergic state causes paroxysms of the classic triad of symptoms; tremor, headache and diaphoresis.[3] In patients with hypertension, other symptoms that should raise suspicion for a pheochromocytoma include labile or postural hypotension, palpitations, pallor and abdominal pain.[4]

They are rare, with an estimated annual incidence of 2 – 8 per million population,[3] although this is likely an underestimation based on post-mortem studies and increasing pre-symptomatic diagnosis rates.[2,5] It can present at any age, but most commonly does so between the ages of 40 and 60.[2,3] At least a third of cases occur as part of a familial syndrome (*e.g.* von Hippel-Lindau, multiple endocrine neoplasia 2, neurofibromatosis 1).[2]

Diagnosis is made from elevated levels of either plasma free metanephrines or urinary fractionated metanephrines.[2] Imaging with CT is suggested to both localise the tumour and also look for metastatic spread.[2]

Treatment is firstly medical, but in the absence of metastatic disease, cure can be achieved with surgical resection.[2] Prior to surgery, patients need to be adequately alpha-blocked, typically this is with phenoxybenzamine for 7-14 days.[2] Lifestyle advice to increase sodium and fluid intake is important pre-operatively to prevent hypotension after resection.[2] Beta-blockers are initially contraindicated as unopposed beta-blockade can trigger a hypertensive crisis, but can be commenced after adequate alpha-blockade.[2] Other medications implicated in adverse reactions in patients with pheochromocytoma include dopamine antagonists (*e.g.* metoclopramide, prochlorperazine), opioid analgesics, sympathomimetics (*e.g.* ephedrine), tricyclic antidepressants (*e.g.* amitriptyline) and corticosteroids.[2] Suggested treatment of a hypertensive crisis is with intravenous phentolamine boluses followed by infusion as required for maintenance of response.[6]

There have been a number of published case reports showing pheochromocytomas presenting

© 2021 Rila Publications Ltd.

with ECG changes and raised cardiac biomarkers mistakenly being investigated and treated as an acute coronary syndrome.[e.g. 7-9] In our above presented case, a differential of pheochromocytoma was raised quite early on and appropriate diagnostic tests performed and treatment initiated. However, as the admission evolved, diagnostic strategies had to change also. Whilst we waited for a very rare diagnosis (pheochromocytoma) to be ruled in or out, there was enough concern about a very common diagnosis (coronary heart disease), to need to investigate it further. We noted that in other case reports, coronary angiography was performed safely in patients with pheochromocytomas.[e.g. 7-9] This case report is therefore an important reminder that in those with a pheochromocytoma, invasive procedures such as coronary angiography can indeed trigger hyperadrenergic crises. As such, the indication and diagnostic benefits of invasive tests should always be weighed up against the potential risks of a crisis in those with a confirmed or suspected pheochromocytoma. We would suggest ensuring good alpha blockade, and ideally requesting an emergency plan from an endocrinology team, before considering invasive procedures, provided the clinical situation allows.

A second learning point from this case is that metoclopramide is contraindicated in those with a pheochromocytoma[2,10]. 5-$HT_4$ receptors which are present on pheochromocytomas are stimulated by metoclopramide, leading to an increase in catecholamine secretion.[9] Given the close temporal relationship between the coronary angiogram and the development of symptoms in our patient, it is reasonable to assume that it was the procedure that triggered the crisis. Nonetheless, we cannot exclude that the use of metoclopramide during the crisis could have worsened or prolonged the episode. Whilst this contraindication is established in the literature, a lack of awareness amongst ourselves and acute medical colleagues means we feel it important to highlight this learning point.

Whilst those with pheochromocytomas can often be managed pre-operatively as an outpatient, it can be important to consider urgent referral and assessment, and even inpatient admission. The National Institute of Health and Care Excellence (NICE) suggests same day assessment of patients with hypertension and a suspected diagnosis of a pheochromocytoma.[4] Our case highlights the importance of cardiac monitoring in those with suspected arrhythmia secondary to their tumour. Given the elevated cardiac biomarker, tachyarrhythmia was suspected early on and as such, the patient was admitted for cardiac monitoring. The patient was discharged once they had been adequately alpha blocked and been tachyarrhythmia free for more than twenty-four hours.

Lastly, in hindsight, we now know our patient had a raised cardiac biomarker in the absence of an acute coronary syndrome and obstructive coronary artery disease. This is a reminder that an isolated raised high-sensitivity troponin without ischaemic cardiac chest pain or ECG changes represents myocardial injury as opposed to a myocardial infarction.[11] Our patient's raised troponin was likely a combination of several factors, including tachyarrhythmia, severe hypertension with impaired end organ perfusion and vasoconstriction.

## Declaration of competing interests

Nothing to declare.

## References

1. Cohen RD & Woods HF. Lactic acidosis revisited. *Diabetes*; 1983 **32(2)**: 181-191.
2. Lenders JW, Duh QY, Eisenhofer G *et al.* Pheochromocytoma and paraganglioma: an endocrine society clinical practice guideline. *J Clin Endocrinol Metab.* 2014; **99(6)**: 1915-42.
3. Reisch N, Peczkowska M, Januszewicz A, Neumann HP. Pheochromocytoma: presentation, diagnosis and treatment. J Hypertens. 2006; **24(12)**: 2331-39.
4. National Institute of Health and Care Excellence (NICE). Hypertension in adults: diagnosis and management. *NICE Guideline* NG136; 2019.
5. Gruber LM, Hartman RP, Thompson GB *et al.* Pheochromocytoma characteristics and behavior differ depending on method of discovery. *J Clin Endocrinol Metab.* 2019; **104(5)**: 1386-93.
6. Whelton PK, Carey RM, Aronow WS *et al.* 2017 ACC/AHA/AAPA/ABC/ACPM/AGS/APhA/ASH/ASPC/NMA/PCNA guideline for the prevention, detection, evaluation, and management of high blood pressure in adults: executive summary: a Report of the American College of Cardiology/American Heart Association Task Force on Clinical Practice Guidelines. *Hypertension*. 2018; **71(6)**: 1269-324.
7. Menke-van der Houven van Oordt CW, Twickler TB, van Asperdt FG *et al.* Pheochromocytoma mimicking an acute myocardial infarction. *Neth Heart J.* 2007; **15(7-8)**: 248-51.
8. Lassnig E, Weber T, Auer J *et al.* Pheochromocytoma crisis presenting with shock and tako-tsubo-like cardiomyopathy. *Int J Cardiol.* 2009; **134(3)**: e138-40.
9. Lee TW, Lin KH, Chang CJ *et al.* Pheochromocytoma mimicking both acute coronary syndrome and sepsis: a case report. *Med Princ Pract.* 2013; **22(4)**: 405-7.
10. Guillemot J, Compagnon P, Cartier D *et al.* Metoclopramide stimulates catecholamine and granin derived peptide secretion from pheochromocytoma cells through activation of serotonin type 4 (5-HT4) receptors. *Endocr Relat Cancer.* 2009; **16(1)**: 281-90.
11. Thygesen K, Alpert JS, Jaffe AS *et al.* Fourth universal definition of myocardial infarction (2018). *European Heart Journal.* 2019; **40**: 237-269.

© 2021 Rila Publications Ltd.