Clinical Reviews

The Diagnostic Assessment of Suspected Pulmonary Embolism on the Acute Medical Take: An Evidence Based Guide

A Proudfoot & D Bell

Abstract

Pulmonary Embolism is a common cardiopulmonary illness with an age and sex adjusted incidence of around 117 cases per 100 000 person years. The clinical presentation is extremely heterogeneous and non specific. Risk factors for venous thromboembolism are well established. When combined with presenting features and investigations. a multimodality algorithm has led to significant changes in the diagnostic approach of suspected PE. While the best combination of tests for any individual patient remains the subject of controversy this article aims to rationalise the acute physician's approach to diagnosis and use of available investigations.

Keypoints

- Clinical probability using a validated score should be recorded in both the patient's notes and the radiology request form.
- Each Hospital should provide information on the sensitivity and specificity of its d-dimer assay.
- Chest x-ray, arterial blood gas and ECG information are not sensitive or specific but may provide prognostic information to identify high risk patients.
- CTPA has now become the principal diagnostic imaging modality to evaluate suspected PE.
- CTPA and transthoracic echo are reliable in the diagnosis of massive PE.
- Measurement of cardiac enzymes including troponins and BNP and transthoracic echo information may provide prognostic information relating to potential massive PE.
- Mulitmodality strategies using a combination of d-dimer, clinical probability scoring and CTPA reliably confirms / excludes PE and invariably permits a management decision.

Introduction

Pulmonary Embolism is relatively common, with an age and sex adjusted incidence of around 117 cases per 100 000 person years.[1] Incidence rises sharply after the age of 60 in both men and women. Mortality rates exceed 15% in the first 3 months after diagnosis.[2] In around 25% of cases the initial clinical manifestation is death.[1] In addition it is estimated that more than half of patients with pulmonary embolism remain undiagnosed. Despite this, public awareness of venous thromboembolism has lagged behind that of other common acute presentations such as acute coronary syndrome and stroke.

The clinical presentation is extremely heterogeneous and non specific.[3] Risk factors for venous thromboembolism are well established[4] and when combined with presenting features have led to improved clinical risk stratification. In addition, multimodal diagnostic approaches, including d-dimer assays and the increasing availability of CT-pulmonary angiography have driven significant changes in the management of suspected PE over the last 5 years.

This article aims to review the recent evidence regarding the presentation and investigation of pulmonary embolism, and suggest an evidence based algorithm for investigation of PE. The management controversies surrounding this frequently encountered differential diagnosis will also be discussed.

Pathophysiology

Pulmonary emboli generally arise from thrombi originating in the lower extremities; however, they may also originate in the pelvic, renal, or upper extremity veins. Most develop at sites of decreased flow, such as valve cusps or bifurcations. The ileofemoral veins are the source of most clinically recognized PE. Large emboli cause haemodynamic compromise due to both anatomical obstruction of blood flow and release of humoral factors such as serotonin, thrombin and histamine. The extent of the haemodynamic compromise depends on the size of the embolus, coexistent cardiopulmonary disease and the neurohormonal effects.[5]

The majority of pulmonary emboli are multiple, with the lower lobes being involved in the majority of cases.[6]

Several mechanisms explain the presence of arterial hypoxemia in the setting of acute PE. Ventilation / perfusion (V/Q) mismatch is the most common cause of impaired pulmonary oxygen transfer.[7] In addition total (physiological & anatomical) dead space is increased as a result of V/Q mismatch / shunt and the effects of low partial pressures of oxygen in venous blood in the context of right ventricular failure may contribute. Low

Dr Alastair Proudfoot
Specialist Registrar in Respiratory / General Medicine
Chelsea & Westminster Hospital
369 Fulham Road
London SW10 9NH
Email: agpshoes@yahoo.com

Prof. D Bell
Professor of Acute Medicine
Imperial College London

© Copyright 2007 Rila Publications Ltd.

cardiac output causes increased oxygen extraction, thereby decreasing the partial pressure of oxygen in venous blood to sub-normal level.

Diagnostic Assessment

Given the heterogeneity of clinical presentation and lack of routine diagnostic investigations, submassive PE is often a common differential diagnosis (massive PE will be discussed separately in this article). The symptoms, signs and abnormal routine investigations are of limited value in confirming PE.[8–14] The use of a validated probability scoring system[15] and d-dimer testing has allowed senior clinicians to make a more accurate assessment of clinical probability.

Risk Factors

Patients with PE usually have identifiable risk factors for the development of venous thrombosis at the time of presentation. Common risk factors include:[4]

Major Risk Factors(5–20x risk)
- Surgery
- Late Pregnancy
- Major Orthopaedic Trauma
- Immobility
- Hospital admission
- Previous thrombosis
- Varicose Veins

Minor Risk Factors (2–4x risk)
- Cardiovascular Disease
- Oral Contraception
- Hormone Replacement Therapy
- Obesity
- Travel (> 5–6hrs)
- Thrombophilia
- COPD

Malignancy is eventually detected in approximately 17 percent of patients who have recurrent idiopathic venous thromboembolism.[16–19] When PE complicates cancer, it is more likely to be the presenting feature of adenocarcinomas or haematological malignancy.

The majority of cancers associated with thromboembolic events are clinically evident and have been previously diagnosed at the time of the event. However, occult cancers can usually be detected by a combination of careful clinical assessment, routine blood tests, and chest radiography alone[18,20,21] without reverting to more invasive investigations.

A large Danish study suggests that occurrence of PE in the context of cancer is associated with a uniformly poor prognosis; 1 year survival of patients with occult cancer was only 12%.[22]

Clinical Manifestations

Autopsy series show that 65 to 90 percent of pulmonary emboli arise from the lower extremities. Despite this, the majority of patients have no leg symptoms at the time of diagnosis.[23,24] Among patients without pre-existing cardiopulmonary disease in PIOPED I,[25] the most common symptoms were dyspnoea (73%), pleuritic pain (66%), cough (37%) and haemoptysis (13%). The most common signs were tachypnoea (70 %), crepitations (51%), tachycardia (30%) and a fourth heart sound (24%). The syndrome of pleuritic pain or haemoptysis without cardiovascular collapse was the most commonly recognized syndrome (65%); Fever (>38.9ºC), occurred in 14% of patients with no other apparent source for an elevated temperature.[14]

Probability Scoring

In recent years, clinical probability assessment has become an important component of diagnosis of pulmonary embolism.[26–27]

PIOPED I found that PE is only present in 9% of those with low clinical probability; this has been confirmed in several large studies[15,28–30] with 2 exceptions[31–32] giving a negative predictive value of 89–96%. In all these studies, patients were assessed by a senior physician.

Clinical probability scores have been devised and the most extensively validated include the Wells score[33] and the Geneva score.[34] Both rules have demonstrated similar accuracy.[30] However, both have limitations. Recent publication of the Revised Geneva Score[35] has provided a favourable compromise; the score comprised 8 variables (Table 1). In the validation set, the prevalence of pulmonary embolism was 8% in the low-probability

Age older than 65	1 point
Previous DVT or PE	3 points
Surgery or Fracture Within 1 month	2 points
Active Malignant Condition	2 points
Unilateral Lower Limb Pain	3 points
Haemoptysis	2 points
HR 75 – 94	3 points
HR > 95	5 points
Pain on Lower-limb Deep Venous Palpation & Oedema	4 points

Table 1. Revised Geneva Score

Clinical symptoms of DVT (leg swelling, pain with palpation)	3.0
Other diagnosis less likely than pulmonary embolism	3.0
Heart rate >100	1.5
Immobilization (3 days) or surgery in the previous four weeks	1.5
Previous DVT/PE	1.5
Hemoptysis	1.0
Malignancy	1.0
Traditional clinical probability assessment	
High	>6.0
Moderate	2.0 to 6.0
Low	<2.0
Simplified clinical probability assessment	
PE likely	>4.0
PE unlikely	4.0

Table 2. Modified Wells criteria: clinical assessment for pulmonary embolism

© Copyright 2007 Rila Publications Ltd.

category (0 to 3 points), 28% in the intermediate-probability category (4 to 10 points), and 74% in the high-probability category (> or = 11 points). The recent Christopher Study[36] used a modified version of the Wells clinical decision rule (see Table 2) allowing patients to be categorized as "pulmonary embolism unlikely" and "pulmonary embolism likely" which may be more pragmatic in clinical practice, and used this to guide further investigation and management.

Baseline Investigations

ECG

Although the electrocardiogram is often abnormal (70% in some series), the findings are insensitive and non-specific.[37] The most common abnormalities are non-specific ST-segment and T-wave changes (49%). The classical S1Q3T3 pattern, atrial arrhythmias, complete right bundle branch block, and the presence of ST segment changes (elevation or depression) in the precordial leads may be associated with a poor prognosis, but the diagnostic value of these findings is limited.[38,39] ECG may therefore act merely as a tool for early risk stratification.

Chest x-ray

In PIOPED I, the most frequent radiographic abnormalities were atelectasis or a pulmonary parenchymal abnormality, either or both of which were observed in 69% of patients with and 58% of patients without pulmonary embolism. Pleural effusion was noted in 47% and 39% of patients with and without pulmonary embolism, respectively. Only 12% of the chest radiographs in patients with confirmed pulmonary emboli were interpreted as normal by experts.

Blood Gases

Arterial blood gas measurements do not appear to have a major role in excluding or establishing the diagnosis of pulmonary embolism.[12] Similarly, pulse oximetry is of limited diagnostic value. However, patients with room air pulse oximetry readings < 95% at the time of diagnosis appear to be at increased risk of complications, including respiratory failure, cardiogenic shock and death.[40]

D-Dimer assays

The assay for d-dimer is only useful as an exclusion test for pulmonary embolism when results are negative.[41–42] Positive results are highly non-specific.[41–42] Furthermore, d-dimer results have to be interpreted in relation to the clinical probability of PE and the knowledge that certain factors will cause elevation irrespective of the presence of venous thromboembolism: increasing age, the presence of known malignancy, recent hospitalisation, pregnancy, infection and peripheral vascular disease.

Furthermore, the assays are not a homogenous group, exhibiting different characteristics; they recognise different epitopes of d-dimer and use different technologies (latex, ELISA, immunotubidemetry). This has an impact on the performance of each individual assay.[43] The sensitivity of the D-dimer assay is also affected by embolus location. In a multicentre study the sensitivity for segmental or larger emboli was much greater than the sensitivity for subsegmental emboli (93% versus 50%).[44]

The 2003 BTS guidelines[4] suggest that a negative d-dimer reliably excludes PE in patients with low (SimpliRED, Vidas, MDA) or intermediate (Vidas, MDA) clinical probability; such patients do not therefore need imaging for PE.

Additional Investigations

Computed Tomographic Pulmonary Angiography (CTPA)

CTPA has now become the principal diagnostic imaging modality to evaluate suspected PE. CTPA is superior to isotope scanning,[45–49] is quick to perform, available out of hours and when negative often allows an alternative diagnosis to be made. Furthermore, newer multidetector CT scanners have increased the detection rate of subsegmental PE, virtually eliminating nondiagnostic studies.[50] Inter-observer agreement is good even with relatively inexperienced assessors.[51–54]

CTPA may also offer prognostic information. A recent study demonstrated the potential value of CTPA RV/LV ratio as an accurate predictor of in-hospital mortality related to PE.[55]

In the recent PIOPED II study[56], for patients with a low or intermediate clinical probability of PE (using the Well's score), normal findings on CTPA had a high negative predictive value for PE (96% for patients with a low probability and 89% for patients with an intermediate probability). However, the negative predictive value was only 60% in patients with a high probability before testing. Conversely, the positive predictive value of abnormal findings on CTPA was high (92% to 96%) in patients with an intermediate or high clinical probability but much lower (58%) in patients with a low likelihood of PE. Clinical assessment should therefore be included in the diagnostic workup of PE to allow for an adequate interpretation of test results.

These data, support the use of CTPA for suspected PE as a stand-alone imaging technique in most patients. However, clinicians should be wary of results that are discordant with their clinical judgment, especially in the patient with a high likelihood of pulmonary embolism and normal findings on CTPA.

The study also suggested that searching for deep venous thrombosis by adding CT Venography (CTV) of the proximal lower-limb veins to improve the accuracy of CTPA does not appear to improve the diagnostic yield enough to justify additional irradiation; there may be a future role for CTV, however, in high risk groups such as critical care patients.

Lower Limb Doppler USS

While leg ultrasound has a management role to play in those patients presenting with signs and symptoms of

© Copyright 2007 Rila Publications Ltd.

DVT & PE it has a limited accuracy in detecting asymptomatic proximal DVT. Studies have shown that proximal clot was found in only 23–52% of patients with confirmed PE[57,58] suggesting that while validated in DVT it is not currently safe to withhold anticoagulation in patients with a single negative ultrasound and suspected PE.

Serial lower extremity studies, however, may further reduce the need for angiography[59,60] but this is not practical in most health care settings. A further use of USS may be as an adjunctive investigation following CTPA; a large multicentre trial has shown that 7% of those patients without confirmed PE had proximal DVT only.[3] This may be useful in patients with equivocal or discordant lung imaging.

Transthoracic Echo

Transthoracic echo has a low sensitivity for diagnosing pulmonary embolism; 30% to 40% of patients with confirmed PE have abnormalities of right ventricular size or function or evidence of tricuspid regurgitation.[61–62] In massive PE[2,63–65] echo may be used as a bedside test to substantiate a presumptive diagnosis e.g. peri-arrest justifying the use of thrombolytic therapy.[5] However, CTPA will offer similar prognostic information while confirming the presence or absence of clot.

V/Q scanning

Until recently, isotope scanning was the most frequently used test in the diagnosis of PE.

PIOPED[25] found that a normal perfusion lung scan virtually excluded the diagnosis of pulmonary embolism. In addition a high probability lung scan indicated a high likelihood of emboli, particularly in patients with a high pretest probability of pulmonary emboli (95%).

Troponins / Brain Natiuretic Peptide(BNP)

Troponins are released as a result of microinfarction due to RV pressure overload, while BNP is secreted from cardiac myocytes in response to RV shear stress[66] Although neither are diagnostic, elevated cardiac biomarkers correlate with the presence of RV dysfunction, a powerful independent predictor of prolonged hypotension and early in-hospital mortality.[66–69] A recent study suggested that a troponin T of > 0.07 is the most significant predictor of mortality.[70]

Pulmonary Angiography

Pulmonary angiography is often considered the 'gold standard' investigation for the diagnosis of pulmonary embolism. However this procedure has now largely been replaced by CTPA given the invasive nature of the test and consequent risks (up to 2% mortality and 5% morbidity). Furthermore pulmonary angiography requires considerable radiological expertise which limits its availability.

Magnetic Resonance Angiography (MRA)

The use of magnetic resonance imaging for the diagnosis of PE has been limited by respiratory and cardiac motion artefacts, suboptimal resolution, complicated blood flow patterns, and magnetic susceptibility effects from the adjacent air-containing lung.[71] While sensitivity for subsegmental clot is poor,[72–73] technologic advances offer promise for an expanded role of MRA (and simultaneous MR Venography of lower limbs) in the future.

Multimodality Strategies

An integrated diagnostic approach is clearly essential. A recent prospective cohort study, used an algorithm consisting of a dichotomized clinical decision rule, d-dimer testing, and CTPA to evaluate patients with suspected PE.[36] A modified version of the Wells clinical decision rule was utilised (see Table 2). Patients were categorized as "pulmonary embolism unlikely" and "pulmonary embolism likely." Patients in the "pulmonary embolism likely" group proceeded directly to chest CT, whereas those in the "pulmonary embolism unlikely" category underwent d-dimer testing. Only patients with abnormal d-dimer were referred for chest CT. Pulmonary embolism was considered to be excluded in patients categorised as "pulmonary embolism unlikely" with negative d-dimer results and in patients with negative chest CT scans. Use of this simple algorithm permitted a management decision in 98% of patients and was associated with a low risk of VTE.

The best combination of tests for any individual patient, however, remains the subject of controversy.[74–75] Such a pragmatic approach as outlined in the Christopher Study and the BTS guidelines may have clinical utility allowing the clinician to reliably confirm or exclude the

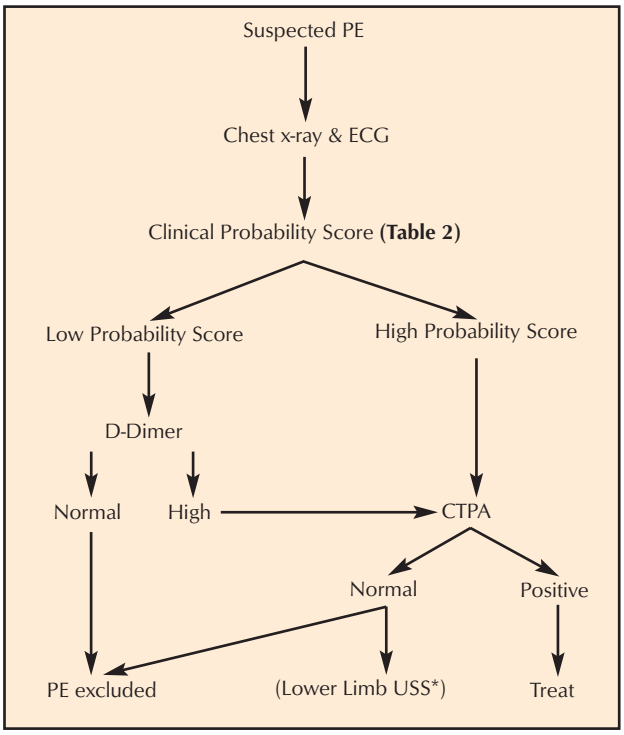

Figure 1. Suggested Algorithm.
⋆ (lower limb venous ultrasound should be undertaken if clinical suspicion persists or if clinical evidence of DVT).

© Copyright 2007 Rila Publications Ltd.

diagnosis using a simple algorithm (Figure 1) which can be applied to any acute receiving unit.

Massive Pulmonary Embolism

Massive PE has been defined as a PE associated with a systolic blood pressure < 90 mmHg or a drop in systolic blood pressure of 40 mmHg from baseline for a period > 15 minutes, which is not otherwise explained by hypovolaemia, sepsis, or a new arrhythmia.[76] It is a catastrophic entity that often results in acute right ventricular failure and death. Frequently undiscovered until autopsy, fatal PE typically leads to death within one to two hours of the event.[77–78] Early mortality in patients with massive PE is at least 15%, and the degree of haemodynamic compromise is the most powerful predictor of in-hospital death.

Presentation is usually with profound dyspnoea at rest, often accompanied by anxiety, syncope, or presyncope. Physical examination is helpful and usually reveals arterial hypotension, tachycardia, tachypnoea, or cyanosis. Signs of acute right ventricular dysfunction are often present. The ECG may be normal but often exhibits tachycardia and the changes associated with right ventricular strain.

In haemodynamically unstable patients, a bedside transthoracic echocardiogram should be obtained as soon as the diagnosis of massive PE is suspected. An echocardiogram is useful to substantiate the diagnosis by confirming right ventricular dysfunction and dilatation but may also exclude diagnoses that may mimic PE such as aortic dissection, pericardial tamponade, or acute myocardial infarction.

An immediate CTPA may be feasible if geographically co-located in patients who can be stabilized with fluids, vasopressors, or mechanical ventilation.

The treatment of sub-massive and massive PE will de discussed in a future article.

References

1. Heit JA. The epidemiology of venous thromboembolism in the community: implications for prevention and management. *J Thromb Thrombolysis*. 2006; **21**: 23–9.
2. Goldhaber SZ, Visani L, De Rosa M. Acute pulmonary embolism: clinical outcomes in the International Cooperative Pulmonary Embolism Registry (ICOPER). *Lancet* 1999; **353**: 1386–9.
3. Musset D, Parent F, Meyer G, Maıˆtre S, Girard P, Leroyer C, et al. Diagnostic strategy for patients with suspected pulmonary embolism: a prospective multicentre outcome study. *Lance*. 2002; **360**: 1914–20.
4. British Thoracic Society guidelines for the management of suspected acute pulmonary embolism. *Thorax* 2003; **58**: 470–83.
5. Goldhaber SZ. Echocardiography in the management of pulmonary embolism. *Ann Intern Med* 2002; **136**: 691–700.
6. Moser, KM. Venous thromboembolism. *Am Rev Respir Dis* 1990; **141**: 235.
7. Itti E, Nguyen S, Robin F, et al. Distribution of ventilation/perfusion ratios in pulmonary embolism: an adjunct to the interpretation of ventilation/perfusion lung scans. *J Nucl Med* 2002; **43**: 1596–602.
8. Ferrari E, Imbert A, Chevalier T, et al. The ECG in pulmonary embolism. Predictive value of negative T waves in precordial leads: 80 case reports. *Chest* 1997; **111**: 537–43.
9. Afzal A, Noor HA, Gill SA, et al. Leukocytosis in acute pulmonary embolism. *Chest* 1999; **115**: 1329–32.
10. Prediletto R, Miniati M, Tonelli L, et al. Diagnostic value of gas exchange tests in patients with clinical suspicion of pulmonary embolism. *Crit Care* 1999; **3**: 111–6.
11. Elliott CG, Goldhaber SZ, Visani L, et al. Chest radiographs in acute pulmonary embolism. Results from the International Cooperative Pulmonary Embolism Registry. *Chest* 2000; **118**: 33–8.
12. Rodger M, Carrier M, Jones G, et al. Diagnostic value of arterial blood gas measurement in suspected pulmonary embolism. *Am J Respir Crit Care Med* 2000; **162**: 2105–8.
13. Rodger M, Makropoulos D, Turek M, et al. Diagnostic value of the electrocardiogram in suspected pulmonary embolism. *Am J Cardiol* 2000; **86**: 807–9.
14. Stein PD, Afzal A, Henry JW, et al. Fever in acute pulmonary embolism. *Chest* 2000; **117**: 39–42.
15. Wells PS, Ginsberg JS, Anderson DR, et al. Use of a clinical model for safe management of patients with suspected pulmonary embolism. *Ann Intern Med* 1998; **129**: 997–1005.
16. Weinmann, EE, Salzman, EW. Deep-vein thrombosis. *N Engl J Med* 1994; **331**: 1630.
17. Monreal, M, Lafoz, E, Casals, A, et al. Occult cancer in patients with deep venous thrombosis. *Cancer* 1991; **67**: 541.
18. Prandoni, P, Lensing, AW, Buller, HR, et al. Deep-vein thrombosis and the incidence of subsequent symptomatic cancer. *N Engl J Med* 1992: **327**: 1128.
19. Monreal, M, Fernandez-Llamazares, J, Perandreu, J, et al. Occult cancer in patients with venous thromboembolism: Which patients, which cancers. *Thromb Haemost* 1997; **78**: 1316.
20. Cornuz J, Pearson SD, Creager MA, et al. Importance of findings on the initial evaluation for cancer in patients with symptomatic idiopathic deep venous thrombosis. *Ann Intern Med* 1996; **125**: 785–93.
21. Hettiarachchi RJ, Lok J, Prins MH, *et al*. Undiagnosed malignancy in patients with deep vein thrombosis: incidence, risk indicators, and diagnosis. *Cancer* 1998; **83**: 180–5.
22. Sorensen HT, Mellemkjaer L, Olsen JH, et al. Prognosis of cancers associated with venous thromboembolism. *N Engl J Med* 2000; **343**: 1846–50.
23. Stein, PD, Terrin, ML, Hales, CA, et al. Clinical, laboratory, roentgenographic and electrocardiographic findings in patients with acute pulmonary embolism and no pre-existing cardiac or pulmonary disease. *Chest* 1991; **100**: 598.
24. Miniati M, Prediletto R, Formichi B, et al. Accuracy of clinical assessment in the diagnosis of pulmonary embolism. *Am J Respir Crit Care Med* 1999; **159**: 864–71.
25. Value of the ventilation/perfusion scan in acute pulmonary embolism. Results of the prospective investigation of pulmonary embolism diagnosis (PIOPED). *The PIOPED Investigators*. JAMA 1990; **263**: 2753.
26. Wells PS, Anderson DR, Rodger M, Stiell I, Dreyer JF, Barnes D, et al. Excluding pulmonary embolism at the bedside without diagnostic imaging: management of patients with suspected pulmonary embolism presenting to the emergency department by using a simple clinical model and d-dimer. *Ann Intern Med* 2001; **135**: 98–107.
27. Perrier A, Roy PM, Aujesky D, Chagnon I, Howarth N, Gourdier AL, et al. Diagnosing pulmonary embolism in outpatients with clinical assessment, D-dimer measurement, venous ultrasound, and helical computed tomography: a multicenter management study. *Am J Med* 2004; **116**: 291–9.

© Copyright 2007 Rila Publications Ltd.

28. Perrier A, Miron MJ, Desmarais S, et al. Using clinical evaluation and lung scan to rule out suspected pulmonary embolism: is it a valid option in patients with normal results of lower-limb venous compression ultrasonography? *Arch Intern Med* 2000; **160**: 512–6.
29. Righini M, Goehring C, Bounameaux H, et al. Effects of age on the performance of common diagnostic tests for pulmonary embolism. *Am J Med* 2000; **109**: 357–61.
30. Chagnon I, Bounameaux H, Aujesky D, et al. Comparison of two clinical prediction rules and implicit assessment among patients with suspected pulmonary embolism. *Am J Med* 2002; **113**: 269–75.
31. Leclercq MG, Lutisan JG, van Marwijk Kooy M, et al. Ruling out clinically suspected pulmonary embolism by assessment of clinical probability and D-dimer levels: a management study. *Thromb Haemost* 2003; **89**: 97–103.
32. Sanson BJ, Lijmer JG, Mac Gillavry MR, et al. Comparison of a clinical probability estimate and two clinical models in patients with suspected pulmonary embolism. *Thromb Haemost* 2000; **83**: 199–203.
33. Wells PS, Anderson DR, Rodger M, Ginsberg JS, Kearon C, Gent M, et al. Derivation of a simple clinical model to categorize patients probability of pulmonary embolism: increasing the models utility with the SimpliRED D-dimer.*Thromb Haemost* 2000; **83**: 416–20.
34. Wicki J, Perneger TV, Junod AF, et al. Assessing clinical probability of pulmonary embolism in the emergency ward: a simple score. *Arch Intern*; **161**: 92–7.
35. Le Gal G, Righini M, Roy PM, et al. Prediction of pulmonary embolism in the emergency department: the revised Geneva score. *Ann Intern Med* 2006; **144**: 165–71.
36. Van Belle A, Buller HR, Huisman MV, Huisman PM, Kaasjager K, Kamphuisen PW, Kramer MH, Kruip MJ, Kwakkel-van Erp JM, Leebeek FW, Nijkeuter M, Prins MH, Sohne M, Tick LW. Effectiveness of managing suspected pulmonary embolism using an algorithm combining clinical probability, D-dimer testing, and computed tomography. *JAMA* 2006; **295**: 172–9.
37. Rodger, M, Makropoulos, D, Turek, M, et al. Diagnostic value of the electrocardiogram in suspected pulmonary embolism. *Am J Cardiol* 2000; **86**: 807.
38. Geibel, A, Zehender, M, Kasper, W, et al. Prognostic value of the ECG on admission in patients with acute major pulmonary embolism. *Eur Respir* J 2005; **25**: 843.
39. Ferrari, E, Imbert, A, Chevalier, T, et al. The ECG in pulmonary embolism. Predictive value of negative T waves in precordial leads--80 case reports. *Chest* 1997; **111**: 537.
40. Kline, JA, Hernandez-Nino, J, Newgard, CD, et al. Use of pulse oximetry to predict in-hospital complications in normotensive patients with pulmonary embolism. *Am J Med* 2003; **115**: 203.
41. Ginsberg, JS, Wells, PS, Kearon, C, et al Sensitivity and specificity of a rapid whole-blood assay for d-dimer in the diagnosis of pulmonary embolism. *Ann Intern Med* 1998; **129**, 1006–11.
42. Perrier, A, Desmarais, S, Miron, M, et al Non-invasive diagnosis of venous thromboembolism in outpatients. *Lancet* 1999; **353**, 190–5.
43. Kelly, J, Hunt, BJ A clinical probability assessment and d-dimer measurement should be the initial step in the investigation of suspected venous thromboembolism. *Chest* 2003; **124**, 1116–19.
44. De Monye, W, Sanson, BJ, Mac Gillavry, MR, et al. Embolus location affects the sensitivity of a rapid quantitative D-dimer assay in the diagnosis of pulmonary embolism. *Am J Respir Crit Care Med* 2002; **165**: 345.
45. Van Beek EJR, Brouwers EMJ, Song B, et al. Lung scintigraphy and helical computed tomography for the diagnosis of pulmonary embolism: a meta-analysis. *Clin Appl Thromb Hems* 2001; **7**: 87–92.
46. Hartmann I, Hagen P, Melissant C, et al. Diagnosing acute pulmonary embolism: effect of chronic obstructive pulmonary disease on the performance of D-dimer testing, ventilation/perfusion scintigraphy, spiral computed tomographic angiography, and conventional angiography. *Am J Respir Crit Care Med* 2000; **162**: 2232–7.
47. Mayo JR, Remy-Jardin M, Muller NL, et al. Pulmonary embolism: prospective comparison of spiral CT with ventilation-perfusion scintigraphy. *Radiology* 1997; **205**: 447–52.
48. Garg K, Welsh CH, Feyerabend AJ, et al. Pulmonary embolism: diagnosis with spiral CT and ventilation-perfusion scanning – correlation with pulmonary angiographic results or clinical outcome. *Radiology* 1998; **208**: 201–8.
49. Van Rossum AB, Pattynama PM, Mallens WM, et al.Can helical CT replace scintigraphy in the diagnostic process in suspected pulmonary embolism? A retrolective-prolective cohort study focusing on total diagnostic yield. *Eur Radiol* 1998; **8**: 90–6.
50. Schoepf UJ, Holzknecht N, Helmberger TK, Crispin A, Hong C, Becker CR, Reiser MF. Subsegmental pulmonary emboli: improved detection with thin-collimation multi-detector row spiral CT. *Radiology* 2002; **222**: 483–90.
51. Van Rossum AB, van Erkel AR, van Persijn van Meerten EL, et al. Accuracy of helical CT for acute pulmonary embolism: ROC analysis of observer performance related to clinical experience. *Eur Radiol* 1998; **8**: 1160–4.
52. Domingo ML, Marti-Bonmati L, Dosda R, et al. Interobserver agreement in the diagnosis of pulmonary embolism with helical CT. *Eur J Radio*l 2000; **34**: 136–40.
53. Remy-Jardin M, Remy J, Baghaie F, et al. Clinical value of thin collimation in the diagnostic workup of pulmonary embolism. *Am J Roentgenol* 2000; **175**: 407–11.
54. Perrier A, Howarth N, Didier D, et al. Performance of helical computedtomography in unselected outpatients with suspected pulmonary embolism. *Ann Intern Med* 2001; **135**: 88–97.
55. Ghuysen A, Ghaye B, Willems V et al. Computed tomographic pulmonary angiography and prognostic significance in patients with acute pulmonary embolism. *Thorax* 2005; **60**: 956–61.
56. Stein PD, Fowler SE, Goodman LR, et al. Multidetector computed tomography for acute pulmonary embolism. *N Engl J Med* 2006; **354**: 2317–27.
57. Turkstra F, Kuijer PM, van Beek EJ, et al. Diagnostic utility of ultrasonography of leg veins in patients suspected of having pulmonary embolism. *Ann Intern Med* 1997; **126**: 775–81.
58. MacGillavry M, Sanson B, Buller H, et al. Compression ultrasonography of the leg veins in patients with clinically suspected pulmonary embolism: is a more extensive assessment of compressibility useful? *Thromb Haemost* 2000; **84**: 973–6.
59. Kelley, MA, Carson, JL, Palevsky, HI, Schwartz, JS. Diagnosing pulmonary embolism: New facts and strategies. *Ann Intern Med* 1991; **114**: 300.
60. Hull, RD, Raskob, GE, Coates, G, *et al*. A new noninvasive management strategy for patients with suspected pulmonary embolism. *Arch Intern Med* 1989; **149**: 2549.
61. Kucher N, Rossi E, De Rosa M, Goldhaber SZ. Prognostic role of echocardiography among patients with acute pulmonary embolism and a systolic arterial pressure of 90 mm Hg or higher. *Arch Intern Med.* 2005; **165**: 1777–81.
62. Come, PC. Echocardiographic evaluation of pulmonary embolism and its response to therapeutic interventions. *Chest* 1992; **101**: 151S.
63. Grifoni, S, Olivotto, I, Cecchini, P, et al. Short-term clinical outcome of patients with acute pulmonary embolism, normal blood pressure, and echocardiographic right ventricular dysfunction. *Circulation* 2000; **101**.

© Copyright 2007 Rila Publications Ltd.

64. Ferrari E, Baudouy M, Cerboni P, et al. Clinical epidemiology of venous thromboembolic disease. Results of a French Multicentre Registry. *Eur Heart J* 1997; **18**: 685–91.
65. Kasper W, Konstantinides S, Geibel A, et al. Prognostic significance of right ventricular afterload stress detected by echocardiography in patients with clinically suspected pulmonary embolism. *Heart* 1997; **77**: 346–9.
66. Giannitsis, E, Muller-Bardorff, M, Kurowski, V, et al. Independent prognostic value of cardiac troponin T in patients with confirmed pulmonary embolism. *Circulation* 2000; **102**: 211.
67. Janata, K, Holzer, M, Laggner, AN, Mullner, M. Cardiac troponin T in the severity assessment of patients with pulmonary embolism: cohort study. *BMJ* 2003; **326**: 312.
68. Yalamanchili, K, Sukhija, R, Aronow, WS, et al. Prevalence of increased cardiac troponin I levels in patients with and without acute pulmonary embolism and relation of increased cardiac troponin I levels with in-hospital mortality in patients with acute pulmonary embolism. *Am J Cardiol* 2004; **93**: 263.
69. Scridon, T, Scridon, C, Skali, H, et al. Prognostic significance of troponin elevation and right ventricular enlargement in acute pulmonary embolism. *Am J Cardiol* 2005; **96**: 303.
70. Kostrubiec M, Pruszczyk, Bochowicz A, et al. Biomarker-based risk assessment model in acute pulmonary embolism. *Eur Heart J* 2005: **26**: 2166–72.
71. Gupta A, Frazer CK, Ferguson JM, et al. Acute pulmonary embolism: diagnosis with MR angiography. *Radiology* 1999; **210**: 353–9.
72. Spuentrup, E, Katoh, M, Wiethoff, AJ, et al. Molecular Magnetic Resonance Imaging of Pulmonary Emboli with a Fibrin-specific Contrast Agent. *Am J Respir Crit Care Med* 2005; **172**: 494.
73. Miniati, M, Bottai, M, Monti, S. Comparison of 3 clinical models for predicting the probability of pulmonary embolism. Medicine (Baltimore) 2005; **84**: 107.
74. Roy, PM, Colombet, I, Durieux, P, et al. Systematic review and meta-analysis of strategies for the diagnosis of suspected pulmonary embolism. *BMJ* 2005; **331**: 259.
75. Kucher, N, Goldhaber, SZ. Management of massive pulmonary embolism. *Circulation* 2005; **112**: e28,
76. Guidelines on diagnosis and management of acute pulmonary embolism. Task Force on Pulmonary Embolism, European Society of Cardiology. *Eur Heart J.* 2000; **21**: 1301–36.
77. Coon, WW, Willis, PW. Deep venous thrombosis and pulmonary embolism: Prediction, prevention and treatment. *Am J Cardiol* 1959; **4**: 611.
78. Soloff, LA, Rodman, T. Acute pulmonary embolism. II. Clinical. *Am Heart J* 1967; **74**: 829.

© Copyright 2007 Rila Publications Ltd.