Emergency Management of Phaeochromocytoma

Dr Andrew Solomon & Professor Pierre Bouloux

Abstract

Phaeochromocytomas are catecholamine secreting tumours associated with unpredictable patterns of hypertension. A variety of forms of investigation are available for detecting hypersecretion of catecholamines or their metabolites. Recent developments in the biochemical diagnosis, localisation and management of phaeochromocytoma and its associated crisis are reviewed.

Keywords

Phaechromocytoma, catecholamines, metanephrines, hypertensive crisis.

Search strategy

The topic was searched using the term phaeochromocytoma /pheochromocytoma, focussing on 'emergency' or 'crisis'. Medline, Embase and the Cochrane Library were searched using the subheadings of prevention and control, diagnosis, therapy and drug therapy.

Key points

- Phaeochromocytoma is an important secondary cause of hypertension and has a variety of clinical presentations
- Investigation ideally requires unequivocal confirmation of catecholamine excess followed by localisation
- Management of phaeochromocytoma is medical followed by surgical; a hypertensive crisis may occur following a range of precipitants and requires careful titration of antihypertensive therapy

Introduction

Phaeochromocytomas and paragangliomas are chromaffin cell tumours of the sympathetic nervous system characterised by hypersecretion of catecholamines and their metabolites. Phaeochromocytomas were termed as such (*phaios*: dusky colour) by Pick in 1912 and are adrenomedullary tumours; paragangliomas are extra-adrenal tumours arising from the medullary neural crest.[1] They are uncommon, 'often sought but rarely found', and occur at a rate of between 1-5 per million per annum with maximum incidence between 20-50yrs. However, the condition may occur at any age, including in children[2] and during pregnancy (only around 220 cases reported)[3] providing a diagnostic challenge to differentiate from pre-eclampsia. Ante-mortem diagnosis is more likely in younger patients – in whom extra-adrenal and multifocal tumours are more common. Overall, approximately 10% of tumours are bilateral, malignant, and extra-adrenal. Bilateral tumours are more likely to be associated with a familial syndrome. In those over 60, in whom an incidence nearer 1 in 2500 is found at autopsy, it is thought that altered baroreceptor reflexes make it more likely to remain undiagnosed. Phaeochromocytomas carry a mortality of 70-80% in the case of an untreated hypertensive crisis; however successful surgery effects a cure rate of around 75% with <2% perioperative mortality in expert centres.Treatment of phaeochromocytoma aims to counteract excessive catecholamine secretion whilst ensuring optimal end-organ function. Following definitive therapy, follow-up is life-long; 5-year survival rates for benign and malignant tumours are 96% and 44% respectively. Paragangliomas are more likely to be malignant and to recur.

Phaechromocytomas are the underlying cause in 0.1% of those with hypertension – this figure is higher in those genetic conditions with a raised baseline risk such as Multiple Endocrine Neoplasia II (MENII) and Neurofibromatosis (Table 1).

Pathology

Biosynthesis of catecholamines occurs in central nervous system nuclei, sympathetic neurons and chromaffin cells. Chromaffin granules in phaeochromocytomas are similar to those in the normal adrenal medulla. Chromaffin cells, including those found in the brain and adrenal medulla, express the phenylethanolamine-N-methyltransferase (PNMT) enzyme. PNMT is necessary for the methylation of noradrenaline to adrenaline and is cortisol dependent. The metabolism of catecholamines occurs via two enzymatic pathways; catechol-o-methyltransferase (COMT) and monoamine oxidase (MAO). COMT converts adrenaline to metanephrine and noradrenaline to normetanephrine. Metanephrine and normetanephrine are oxidised MAO to vanillylmandelic acid (VMA) by oxidative deamination. MAO has an important role in

Dr Andrew Solomon
MRCP
Clinical Research Fellow
Department of Endocrinology
He is an SpR on the North Thames Training Rotation

Professor Pierre Bouloux
MD FRCP
Professor of Endocrinology,
Department of Endocrinology
Royal Free Hospital
Pond St
London
NW3 2QG

Professor Pierre Bouloux
Director of the Centre for Neuroendocrinology at the Royal Free Hospital and Medical School

Correspondence:
Dr Andrew Solomon
MRCP
Clinical Research Fellow,
Department of Endocrinology
Royal Free Hospital
Pond St
London
NW3 2QG
Email: andrew.solomon@doctors.org.uk
Tel: 0207 417 6190
Fax: 0207 417 6190

Emergency Management of Phaeochromocytoma

Familial condition	Estimated risk of phaeochromocytoma	Genetic basis
MEN2a medullary carcinoma of thyroid, 4-gland parathyroid hyperplasia, phaeochromocytoma	**50%**	**RET** proto-oncogene
MEN2b As MEN 2a + Marfanoid habitus and visceral neuromas	**50%**	**RET** proto-oncogene
Familial Paraganglioma syndrome	**Est. 20 %**	**SDHD, SDHB**
Neurofibromatosis	**11%**	**NF1**
Von Hippel Lindau	**10-20%**	**VHL**

Table 1. Familial conditions at increased risk of phaeochromocytoma

regulating noradrenaline and dopamine metabolism; intravesical stores of noradrenaline are increased by MAO inhibitors. Small tumours (<50g) have a rapid metabolic turnover often releasing unmetabolised contents into the plasma – thus explaining how smaller tumours may cause disproportionately severe symptoms.

Crises can occur without marked changes in circulating catecholamines and conversely, blood pressure may remain normal in the face of markedly raised plasma catecholamine concentrations.

Additional products secreted from these tumours include a range of peptides such as calcitonin, gastrin, serotonin, vasoactive intestinal peptide(VIP), neuropeptide Y(NPY), adrenocarticotrophic hormone (ACTH), parathyroid hormone(PTH) and its related peptide, (PTHrp) – each potentially causing their attendant syndromes.

Cosecretion of NPY has been claimed as a cofactor for catecholamine mediated vasoconstriction. It is thought to be involved in the mechanism of hypertensive crisis precipitated by tumour manipulation, despite adequate preoperative alpha blockade.[4]

Clinical presentation

In terms of clinical presentation, the triad of headache, palpitations and sweating is the best recognised syndrome ; symptomatic paroxysms sometimes known as 'spells' occur in only 10-17% of patients – characteristically similar in any individual patient. Phaeochromocytoma is a great mimic and a wide variety of presentations have been reported. Common clinical features include palpitations, sweating, pallor, anxiety, pulmonary oedema, paralytic ileus, angina and myocardial infarction or stroke. More unusual symptoms include paraesthesia, pulsatile scotomas and hemianopia. Certain symptoms may indicate localisation of paragangliomas; for example if occurring in association with micturition, finding a tumour located adjacent to the bladder is likely. Weight loss, pallor, orthostatic hypotension and vomiting are commonly overlooked features. In addition, objective measures of labile blood pressure, tachyarrythmias, cardiomyopathy and 'unexplained' lactic acidosis should all alert the physician towards the diagnosis.

The differential diagnosis of the clinical presentation includes thyrotoxicosis, anxiety states, menopausal vasomotor symptoms, illicit drug use, alcohol and caffeine withdrawal, intake of MAOIs and tyramine–containing foods, autonomic dysfunction e.g in spinal injury, Guillain-Barre syndrome, acute intermittent porphyria, lead poisoning and abrupt withdrawal of drugs including clonidine, methyldopa and beta blockers.

Diagnosis of phaeochromocytoma

Baseline investigations should include full blood count, electrolytes, glucose, calcium, magnesium, renal, liver and thyroid function tests. In addition electrocardiography, and chest radiographs would normally be performed. In cases of high clinical suspicion; biochemical tests can provide diagnostic specificity of 95%.[5] Biochemical investigation is usually performed prior to radiological studies due to the risk of contrast media inducing an unexpected hypertensive episode (Figure 1).

There is a large number of modalities for the biochemical investigation of suspected phaeochromocytoma.[6,7] Indication for undertaking such tests are listed in Table 2. In the UK most laboratories currently offer urine catecholamines, a few provide plasma catecholamines and free plasma metanephrines are even less commonly available. Urinary vanillylmandelic acid (VMA) is now rarely measured . Laboratories generally use HPLC (high performance liquid chromatography) with electro-chemical detection of catecholamines.

In general, 85% of tumours produce elevated noradrenaline levels, and only 70% produce elevated adrenaline. Monosecretion of adrenaline is rare. Elevated plasma adrenaline or urinary metanephrine suggests a tumour of adrenal origin; exclusive noradrenaline secretion suggests either a very large adrenal tumour or a paraganglioma. Large adrenal tumours often outstrip their corticomedullary blood flow and develop their own direct arterial vessels. This reduces the tumour's exposure to cortisol reducing PNMT activity and preferentially releasing noradrenaline.

- Young hypertensive patient
- Unexplained shock
- Abnormal blood pressure response to anaesthesia or surgery
- Hypertension refractory to several antihypertensives
- Family history of phaeochromocytoma, medullary carcinoma of thyroid or MEN
- Neurofibromatosis or Café au Lait spots
- Von-Hippel Lindau Syndrome
- Sturge Weber Syndrome
- Tuberose Sclerosis
- Ataxia Telangiectasia
- Acromegaly
- Cushing's Disease
- Radiological evidence of adrenal mass i.e. incidentaloma

Table2. Indications for biochemical investigation in suspected phaeochromocytoma

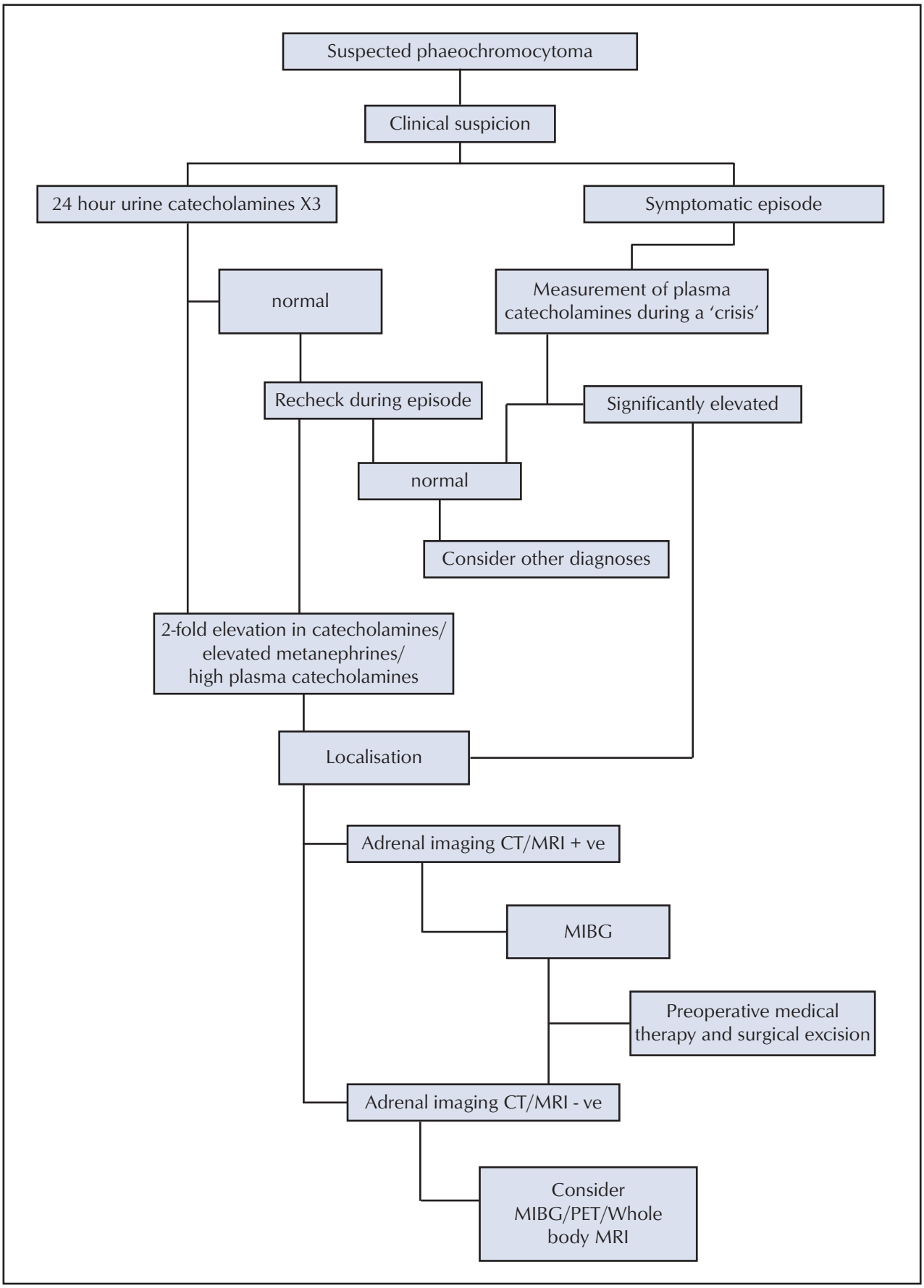

Figure 1. Suggested algorithm for diagnosis of phaeochromocytoma

Emergency Management of Phaeochromocytoma

Diagnostic techniques (See Tables 2-4)

1) 24 hr urine for unmetabolised or free catecholamines

A 24 hour urine collection for urinary metanephrines or catecholamines is usually undertaken, but an overnight sample may of similar accuracy and more convenient.[8] When collecting urine catecholamines, patients do not need to be on a vanilla-free diet, but must ensure collection is in an acid-containing bottle. Often a larger tumour will produce catecholamine metabolites (pre-metabolised within the tumour), smaller tumours may secrete more free catecholamines. Tricyclic antidepressants, alpha and beta blockers and any drugs containing catecholamines or affecting dopamine metabolism should be stopped 3-4 days prior to testing.

2) Plasma catecholamines

Plasma catecholamines are most useful during symptomatic episodes or during dynamic testing. Plasma noradrenaline levels exceeding 10nmol/l or adrenaline levels exceeding 1.5 nmol/l give a high specificity. Elevated plasma adrenaline levels suggest the tumour is of adrenal origin. Plasma catecholamines are elevated by caffeine, nicotine, exercise and certain medications.

3) Plasma free metanephrines

The potential for measurement of plasma free metanephrines is generating significant interest suggesting that this may become a diagnostic modality of choice in the future – and is regarded as the most sensitive biochemical test. Recent data suggests that plasma metanephrines may provide information about the size and location of the tumour. These results were obtained from a prospective analysis of 275 phaeochromocytoma patients.[9] However several large centres disagree on the optimal plasma investigation, partly due to up to a 15% false positive rate of plasma metanephrines. A systematic review assessing this technique has recently been published.[10] The authors concluded that this test had a sensitivity of 96-100% and specificity of 85-100%; i.e. that a negative test could rule out phaeochromocytoma.

Dynamic tests – A variety of dynamic tests for phaeochromocytoma have been developed. They may be useful for patients with borderline changes (Table 3).

Adrenal Venous sampling – is occasionally performed but is of some risk; alpha and beta blockade should be administered prior to the procedure. Reversal of the noradrenaline: adrenaline ratio in the adrenal vein is suggestive of the diagnosis.

Pentolinium suppression test This test involves giving 2.5 mg pentolinium intravenously and measuring serum catecholamines at 10min intervals and at one hour. Elevated catecholamines are seen in those with phaeochromocytoma whereas suppression occurs in normal subjects.
Clonidine test 300 µg clonidine is given orally, with hourly measurement of catecholamine levels for 3 hours. Failure of suppression into the normal range at 120 and 180 min is suggestive of phaeochromocytoma.
Phentolamine test 5mg phentolamine injected i.v. should provide a significant fall in blood pressure in a hypertensive patient with phaeochromocytoma.
Glucagon test This is usually performed using 0.5-1mg of glugacon i.v. with prior alpha and beta blockade and, to be positive, requires >2.5x increase in catecholamines.

Table 3. Dynamic tests used in diagnosis

Radiological Localisation

CT and MRI - are the first line imaging modalities offering high sensitivity; however specificity of these modalities is only around 70%.

Contrast enhanced CT is thought to be relatively safe using non-ionic media without the use of alpha blockade, although it is still advisable. Around 12% of tumours demonstrate speckled calcification and phaeochromocytomas intensely enhance with contrast. Phaeochromocytomas usually provide high intensity signal on T2 MRI; chemical-shift imaging is used to differentiate from lipid-containing adrenal adenomas.

MIBG Scanning Meta-iodobenzylguanidine - MIBG - is a compound similar to noradrenaline that is taken up by adrenergic tissue. This type of scan, after administration of ^{131}I- or ^{123}I-labeled MIBG, is especially useful in cases of extra-adrenal, residual or metastatic disease. It has around 90-96% sensitivity and 98-99% specificity. Following intravenous injection of MIBG, the patient is scanned at both 24 and 48-72hrs. Tricyclics and labetalol should be discontinued several weeks before the scan. Radionuclide ^{123}I-MIBG scanning may be used intraoperatively.

Octreotide scanning relies on the presence of somatostatin receptors on the surface of these tumours. When used, the spleen may affect the quality of adrenal imaging.

Positron emission tomography (PET) has become widely used in clinical oncology. Tumour-specific agents have been developed to image phaeochromocytomas in addition to the commonly used (18F)Fluorodeoxyglucose. They include (11C)-hydroxyephedrine (11C)-epinephrine and 6-18F fluorodopamine. 6-18F fluorodopamine has been shown to identify some confirmed phaeochromocytomas not seen on ^{131}I MIBG scanning. It is likely that in endocrine oncology in general and phaeochromocytoma in particular, PET scanning will become an increasingly available, highly informative imaging modality.[11] Sensitivity and specificity of diagnostic methods are summarised in Table 4.

Management

Definitive therapy for phaeochromocytomas is surgical; with medical therapy used peri-operatively and in metastatic disease. Surgery, or at least debulking of the

tumour, is the primary management strategy. The regime of alpha blockade, followed after 48 hours by beta blockade is now standard. Complete excision of phaechromocytomas leads to normalisation of blood pressure in around 75% of cases. Essential hypertension may persist after therapy.

If longer term oral treatment is required, the use of combined alpha and beta blockade is the therapeutic combination of choice – with a suggestion of a synergistic effect in combination with metyrosine. However, there is increasing use of metyrosine, alpha blockade and calcium channel blockers. Longer term management of chromaffin cell tumours have recently been extensively reviewed.[13]

Phaeochromocytoma crisis - Treatment of a hypertensive crisis

During a phaeochromocytoma crisis, the supply-demand mismatch caused by catecholamine driven tachycardia, increased afterload, and increased myocardial oxygen demand can precipitate serious complications. Precipitants for hypertensive crisis are summarised in Table 5. Clinically, 2 or more symptoms may occur simultaneously, with abrupt onset, with most 'crises' lasting 15-60 minutes. Subjects often describe a sense of impending doom, 'that they are about to die' and a severe sense of anxiety. Initial management of a hypertensive crisis may involve intravenous boluses of phentolamine. Phentolamine is a short acting non-selective competitive alpha adrenergic blocker, its short half-life allows for repeated dosing, every few minutes if necessary. An initial dose of 1mg can be given, and then extended towards 5mg boluses or as a continuous infusion of 5-10 mcg/kg/min made up as 100mg phentolamine in 500ml of 5% dextrose. Phenoxybenzamine may be used as described above – both initially orally or intravenously 0.5mg/kg i.v over 2-4 hrs; side effects include severe hypotension and watershed cerebral infarction. Commencing beta blockade within 24 hrs is advised. Beta-blockade during a hypertensive crisis may be achieved using esmolol (i.v. 50-200mg/kg/min).

Sodium nitroprusside may be given as a continuous infusion from a light-sensitive bag though it appears to be somewhat less potent. It is used at doses of 0.5mcg/kg/min up to 10mcg/kg/min.

Test	Sensitivity%	Specificity%
2 x 24hr urine catecholamines	100	95
Plasma free Metanephrines	97	85
Urinary VMA	65	86
MRI	98	70
CT	93	70
MIBG	80	95

Table 4. Sensitivity and specificity of diagnostic methods

Precipitating factors for Hypertensive Crisis
• Tumour Haemorrhage
• Raised intrathoracic pressure e.g. coughing
• Exercise
• Parturition
• Pressure on abdomen
• Tumour palpation
• Pneumoperitoneum*[12]
• Drugs – Unopposed beta-blockade, glucagon, ACTH, anaesthetic agents, metoclopramide, tricyclics, opiates, intravenous contrast agents, phenothiazines, naloxone, cytotoxic agents.

Table 5. Precipitating factors for Hypertensive Crisis

Metyrosine, a competitive inhibitor of tyrosine hydroxylase may also be used. The starting dose is usually 250mg twice to four times per day – it may be used alone or in combination with an alpha-blocker.

Malignant Phaeochromocytomas

Malignancy in phaeochromocytoma is best indicated by aggressiveness of disease i.e. local invasion or distant metastases. Histology may be similar to benign disease. Management for malignant disease includes surgical excision or debulking, and long term antihypertensive therapy. Further therapeutic options include high dose MIBG therapy, chemotherapy or radiotherapy. In addition, radiofrequency ablation or transarterial embolisation of hepatic metastases has been performed with some response.

Acknowledgments

Useful input for this article was provided by Dr Stephen Whiting, Consultant Biochemist, Royal Free Hospital

References:

1. Prys-Roberts C. Phaeochromocytoma - recent progress in its management. *Br.J.Anaesth* 2000. **85(1):** 44-57.
2. Kohane D.S., Ingelfinger J.R., Nimkin K, Wu C. A Nine-Year-Old Girl with Headaches and Hypertension. *N.Engl.J.Med* 2005. **352:** 2223-2231
3. Kaltsas GA, Papadogias D, Grossman AB. The clinical presentation (symptoms and signs) of sporadic and familial chromaffin cell tumours (phaeochromocytomas and paragangliomas). *Front Horm Res* 2004; **31:** 61-75
4. Bravo EL, Tagle R. Pheochromocytoma: State-of -the-Art and Future Prospects. *Endocr.Rev*. 2003. **24(4):** 539-553
5. Peaston RT, Weinkove C. Measurement of catecholamines and their metabolites. *Ann Clin Biochem* 2004; **41(Pt 1):** 17-38
6. Bravo EL, Gifford RW, Jr. Pheochromocytoma. *Endocrinol Metab Clin North Am* 1993; **22(2):** 329-341
7. Peaston RT, Weinkove C. Measurement of catecholamines and their metabolites. *Ann Clin Biochem* 2004; **41(Pt 1):** 17-38
8. Peaston RT, Lennard TW, Lai LC. Overnight excretion of urinary catecholamines and metabolites in the detection of pheochromocytoma. *J Clin Endocrinol Metab* 1996; **81(4):** 1378-1384
9. Eisenhofer G, Lenders JW, Goldstein DS, Mannelli M, Csako G, Walther MM *et al*. Pheochromocytoma catecholamine phenotypes and prediction of tumor size and location by use of plasma free metanephrines. *Clin Chem* 2005; **51(4):** 735-744

Emergency Management of Phaeochromocytoma

10. Sawka AM, Prebtani AP, Thabane L, Gafni A, Levine M, Young WF, Jr. A systematic review of the literature examining the diagnostic efficacy of measurement of fractionated plasma free metanephrines in the biochemical diagnosis of pheochromocytoma. *BMC Endocr Disord* 2004; **4(1):** 2
11. Pacak K, Eisenhofer G, Goldstein DS. Functional imaging of endocrine tumors: role of positron emission tomography. *Endocr Rev* 2004; **25(4):** 568-580
12. Tauzin-Fin P, Sesay M, Gosse P, Ballanger P. Effects of perioperative alpha1 block on haemodynamic control during laparoscopic surgery for phaeochromocytoma. *Br J Anaesth* 2004; **92(4):** 512-517
13. Kaltsas GA, Besser GM, Grossman A.B. The Diagnosis and Medical Management of Advance Neuroendocrine Tumors. *Endocr.Rev.* 2004. **25(3):** 458-511