Acute Medicine V9 N3_Acute Med V9 N3.qxd 26/10/2010 13:54 Page 130

Picture Quiz: Question

Picture Quiz: A Bad Case of the Flu

M Maw, F Zahoor & E Tabiowo

Case History

A 51-year-old man who was normally fit and well, presented with a one-week history of fever, cough, shortness of breath, myalgia and diarrhoea.

On examination he was febrile at 37.8°C, acutely short of breath with oxygen saturations of 75% on 15L of oxygen via a non re-breath mask and a respiratory rate of 25. He was haemodynamically stable with a blood pressure of 120/70 and pulse rate of 95. Blood tests showed normal Haemoglobin 16.3g/dl, low white blood cells $3.3x10^9$/L, lymphocytes $0.9x10^9$/L, platelets $130x10^9$/L and normal renal function.

His admission chest x-ray is shown in Figure 1. Within a few hours he was intubated and ventilated. A nasogastric tube was placed for nutritional support and a repeat chest x-ray is shown in Figure 2.

Questions

1. What are the abnormalities shown in Figure 1?
2. What complication is shown in Figure 2?

Dr Matthew Maw
MbChB MRCP (ST4 Acute Medicine – University Hospitals North Staffordshire)

Dr Feisal Zahoor
MbChB MRCP (ST4 Acute Medicine – University Hospitals North Staffordshire)

Dr Eugene Tabiowo
MbChB MRCP (ST4 Acute Medicine – Wrexham Maelor Hospital)

Correspondence:
Dr Matthew Maw
MbChB MRCP
ST4 Acute Medicine – University Hospitals North Staffordshire
Email: montague_maw@hotmail.com

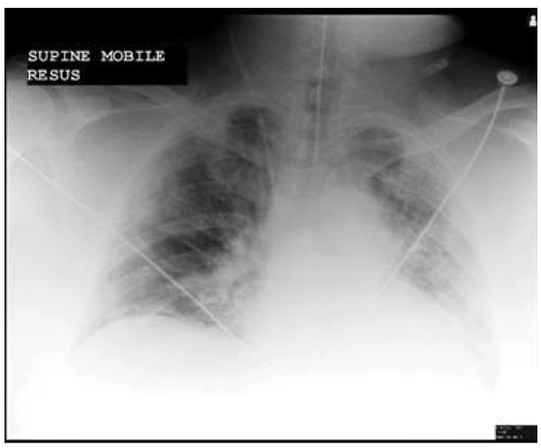

Figure 1.

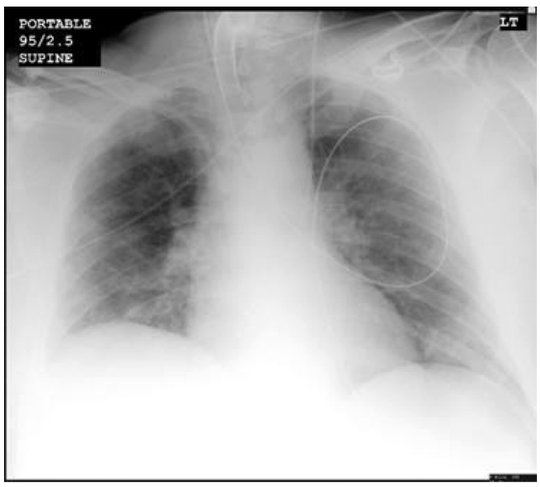

Figure 2.

© 2010 Rila Publications Ltd.