Clinical Review

Pneumothorax management: are the guidelines all-encompassing for the purpose of Acute Medicine?

R Cama, J Murray & N Murch

Abstract

Pneumothorax is defined as the presence of air in the pleural space, between the lung and the chest wall. It is a significant global health problem, with considerable morbidity and healthcare costs. Best management strategy remains controversial, with significant variation in practise, both nationally and internationally. The lack of consensus is driven by the paucity of the evidence base. Current research trials, particularly those looking at ambulatory management, are making progress and may help streamline future guidelines. This review presents five case reports of patients treated with methods which are not entirely synchronous with the current British Thoracic Society (BTS) guidelines; providing guidance for acute medical physicians who are routinely presented with such cases and exploring future developments in pneumothorax management.

Epidemiology

UK data on hospital admission rates, for combined primary spontaneous pneumothorax (PSP) and secondary spontaneous pneumothorax (SSP), are reported as 16.7 cases per 100 000 for men and 5.8 cases per 100 000 for women per annum.[1] This equates to around 50 000 bed days within the National Health Service (NHS), as there are approximately 8000 admissions a year with the average length of stay being just under a week.[2] These admissions costs the NHS an estimated £20m in bed days alone. The £20m figure is a gross underestimation as it only reflects the number of bed days for patients managed medically and does not take into account the number of patients who will have recurrence of their condition or patients who will require surgical intervention. Ambulatory management of some of these admissions could decrease the burden on a service which is already struggling to meet its demand.

Current guidelines

Pneumothorax has traditionally been categorised into PSP, SSP, or traumatic (iatrogenic or otherwise). The distinction between PSP and SSP is based on the absence or presence of clinically apparent lung disease. Virtually every lung disease has been reported to be associated with SSP;[4] however chronic obstructive pulmonary disease is the most common underlying condition, accounting for approximately 60% of all presentations.[5] In the absence of clinical lung disease, a 20 pack year smoking history is also considered equivalent to an underlying lung disease.[5, 6] Many studies have demonstrated anatomical abnormalities even in patients labelled with PSP without known previous respiratory disease.[7, 8] Abnormalities such as emphysema-like changes,[9] sub-pleural blebs and bullae[10] are found at thoracoscopy and computerised tomography (CT) scanning in a significant number of cases, particularly in patients that smoke tobacco and/or cannabis.[11] It is likely that a more comprehensive categorisation of lung disease would provide effective tailoring of treatment. However, the aetiology of pneumothoraces is beyond the remit of this review. We briefly focus on the current management guidelines.

PSP and SSP are currently viewed as discrete groups due to their morbidity and mortality, clinical presentation, and recommended guidelines. One of the major differences existing between guidelines is related to the method of measuring the pneumothorax. The BTS guidelines define the size of the pneumothorax by the interpleural distance measured at the hilum – with large pneumothoraces occupying a distance of 2cm or greater (Figure 1).[12] The rationale is that a 2cm pneumothorax equates to a 50% reduction in the lung volume. The volume of a pneumothorax approximates to the ratio of the cube of the lung diameter to the hemithorax diameter.[13] A pneumothorax of 2cm on a posteroanterior (PA)

Key messages
High-quality randomised control trials currently reviewing the standard care and the use of the Heimlich valve in ambulatory management may streamline future guidelines.
Familiarisation with new equipment such as thoracentesis catheters is advised to all acute physicians.
Management of a pneumothorax should be increasingly individualised and tailored to the patient's wishes.
Collaboration with respiratory physicians is recommended when a patient is not responding to intervention and/ or the patient does not fit exactly into the treatment framework advised by the BTS guidelines.

Rigers Cama
MBBS
Foundation Year 1 Doctor
Royal Free London NHS Foundation Trust
Royal Free Hospital

James Murray
MBBS MRCP
SpR Respiratory Medicine/ Clinical Teaching Fellow
Royal Free London NHS Foundation Trust
Royal Free Hospital

Nick Murch
MB.BCh FRCP
Clinical Lead for Acute Medicine
Honorary Clinical Senior Lecturer, UCL
Acute Medicine Training Programme Director, NC & E London
Royal Free London NHS Foundation Trust
Royal Free Hospital

Correspondence
James Murray.
SpR Respiratory Medicine/ Clinical Teaching Fellow
Royal Free London NHS Foundation Trust
Royal Free Hospital
Email: james.murray11@nhs.net

© 2018 Rila Publications Ltd.

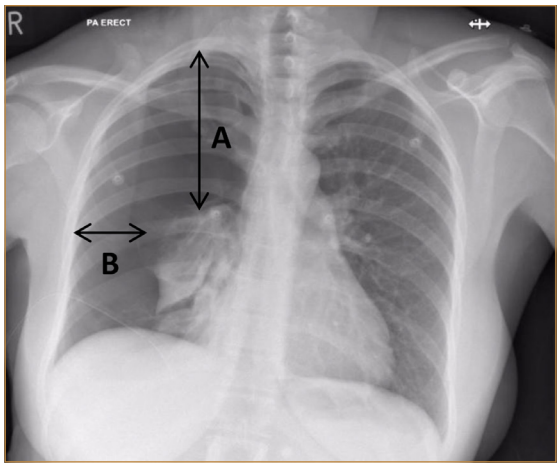

Figure 1. Depth of pneumothorax; A = apex to cupola distance – American guidelines; B = the interpleural distance measured at the hilum – BTS guidelines.

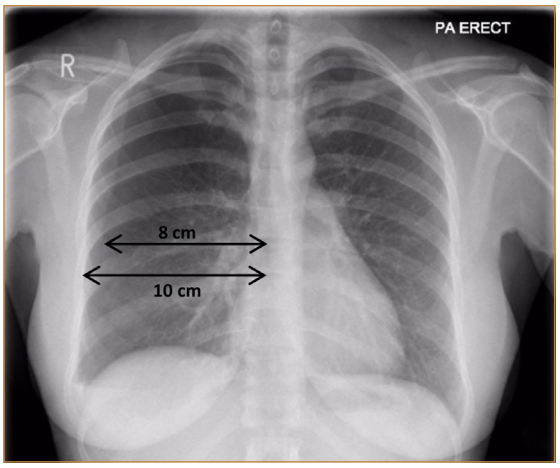

Figure 2. Quantitation of size of pneumothorax.

radiograph occupies approximately 50% of the hemithorax volume if the lung is 8cm in diameter and the hemithorax is 10cm (10^3-8^3)/10^3 = 49% (Figure 2). In contrast, the American College of Chest Physicians (ACCP) define the size of the pneumothorax by the distance measured from the apex of the lung to the thoracic cupola (Figure 1).[14]

Management of PSP

PSP typically occurs in young adults, with a peak age incidence of 15-34 years in the United Kingdom.[2] The main risk factors for PSP are cigarette smoking[8] and male gender;[2, 15] however, often no precipitating cause can be identified. Many episodes occur at rest, presenting with chest pain or dyspnoea.

The management of PSP depends on the size of the pneumothorax on a PA radiograph and whether the patient is symptomatic or not. BTS guidelines recommend that patients with small PSP (less than 2cm) and no associated breathlessness should be considered for discharge with early outpatient review (Figure 3).[12] The patients should be given advice before discharge, stressing the importance of returning to hospital in the event of developing worsening symptoms, and the importance of attending the arranged follow up with a respiratory physician.

In the event of a large pneumothorax and/or severe dyspnoea, the BTS and ACCP guidelines recommend active intervention[12,14]. The BTS guidelines currently favour needle aspiration in such cases, whereas the ACCP guidelines recommend inserting a small-bore chest drain (8 to 14 Fr). A Cochrane review by Wakai et al. (2007) showed that there is no significant difference between simple aspiration and intercostal tube drainage with regards to immediate success rate, early failure rate, duration of hospitalisation, one year success rate and number of patients requiring pleurodesis at one year.[16, 17] Further, simple aspiration is associated with reduced hospitalisation and length of stay.[16]

The success rate of needle aspiration ranges from 30% to 80%.[16, 18, 19] The BTS guidelines recommended that needle aspiration is stopped after 2.5L of air has been aspirated, with further re-expansion being unlikely, due to the likelihood of a persistent air leak. If needle aspiration is unsuccessful on first attempt, a repeat is unlikely to be successful unless there were technical difficulties such as a blocked or kinked catheter.[12] The current recommendation post failed needle aspiration is the insertion of a chest drain. Patients that have successful needle aspiration can be considered for early discharge.

Management of SSP

Unlike PSP, SSP can be a potentially life-threat threatening event because patients with co-existing lung disease have less physiological reserve to deal with the cardiorespiratory compromise. Thus, patients tend to present with marked symptoms of dyspnoea and chest pain.

In reflection of this difference between PSP and SSP, both the BTS and ACCP guidelines recommend early intervention and admission for all SSP cases. Oxygen therapy is recommended in the guidelines, but caution is advised for patients with carbon dioxide retention. The BTS guidelines recommend attempting needle aspiration in young (< 50 years) asymptomatic patients with a pneumothorax measuring 1-2cm, and upon successful lung re-expansion, a 24 hour period of inpatient observation.[12] The ACCP guidelines suggest that this is unlikely to be successful and patients should be managed with a chest drain.[14] Where needle aspiration is not successful, and in cases of large or symptomatic pneumothoraces, a small- bore chest drain is recommended. For pneumothoraces, it is increasingly accepted, without

© 2018 Rila Publications Ltd.

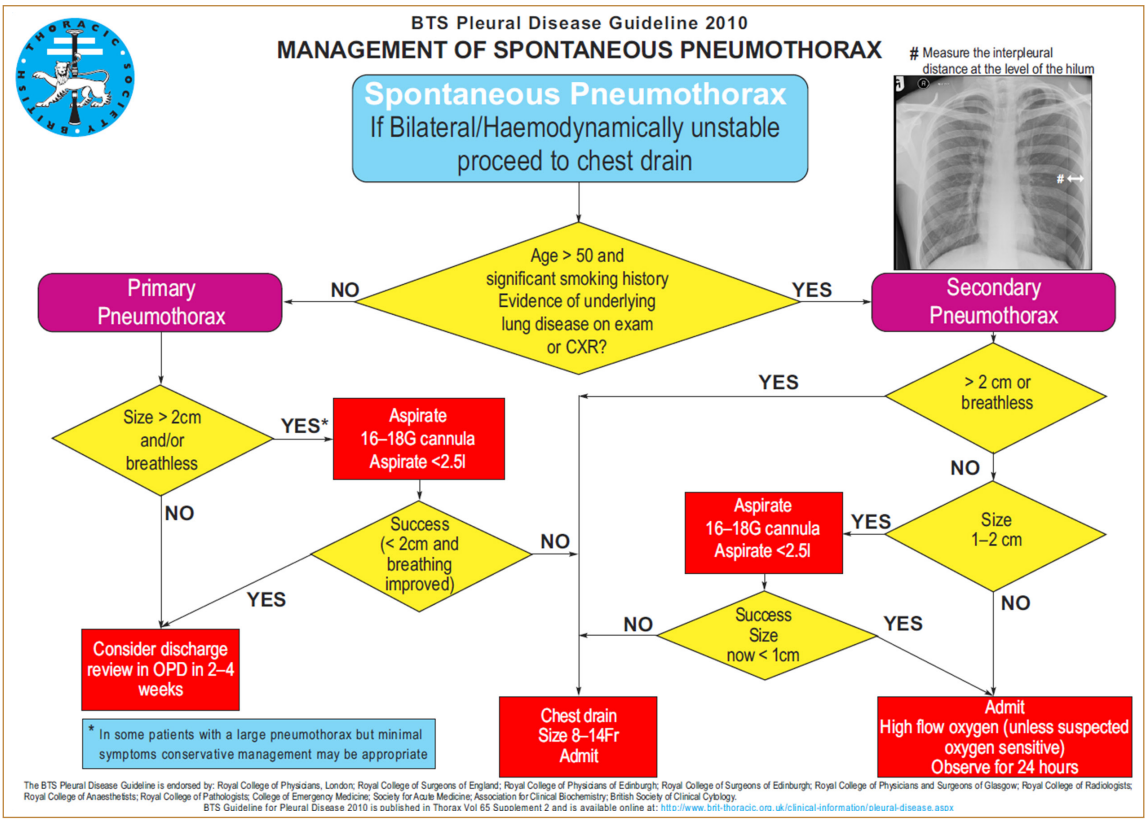

Figure 3. British Thoracic Society guidelines on spontaneous pneumothorax. Credit to British Thoracic Society 2010 and Rocket® Medical.

formal randomised control trial evidence, that smaller drains are as effective as large-bore ones.[12, 14, 20] Some authors advocate larger drain sizes (20– 24 Fr) in ventilated patients to facilitate drainage but this is unproven. Figure 4, highlights the difference in external diameter of different sized drains.

Bintcliffe et al. (2014) recommend early referral to a chest physician in all SSP cases.[22] Further, patients with a persistent air leak after 48 hours of treatment should be discussed with a thoracic surgeon offering an individualised approach to surgical management. With recurrence rates of SSP being quoted as high as 41% in some studies,[23] it is imperative that patients are counselled regarding the risks of recurrence and the potential for a more definitive management in the form of pleurodesis (the apposition of the visceral and parietal pleura to seal the pleural space). The ACCP recommend surgical pleurodesis via a thoracoscopic approach – in the form of pleural abrasion, bullectomy, partial pleurectomy or talc poudrage for patients with an ongoing air leak[14]. Patients who are unfit for surgery or decline surgical intervention, are offered medical pleurodesis with a sclerosant agent such doxycycline, talc via the chest drain or a blood patch approach.[22, 24] In a retrospective study in Japan, Onuki et al. (2017) showed that in the PSP and SSP groups, the recurrence rates among patients who received nonsurgical treatment were 24.5% and 17.4%, while those among

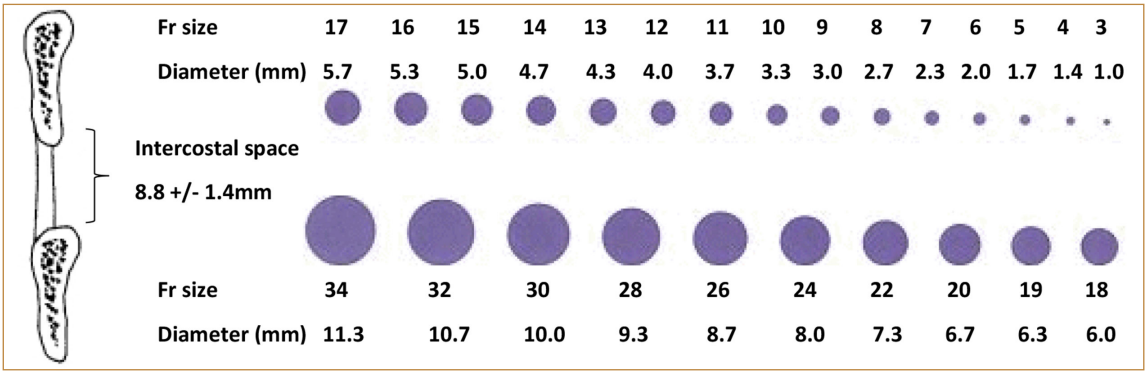

Figure 4. Relative sizes of the mean intercostal distance in the adult (fifth intercostal space, mid-axillary line); and sizes of chest tubes ranging from 3 – 34 Fr.[21]

© 2018 Rila Publications Ltd.

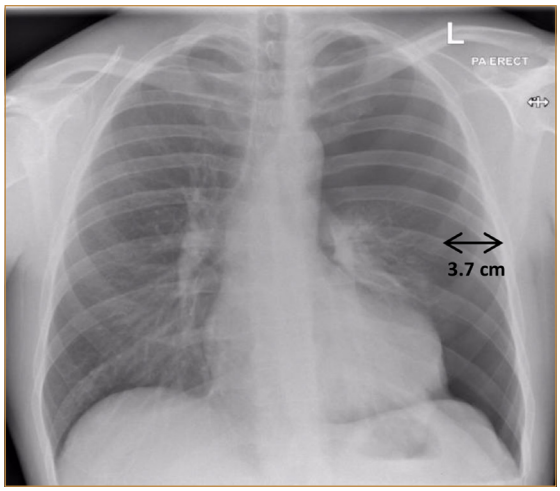

Figure 5. Left-sided pneumothorax with an interpleural distance of 3.7cm.

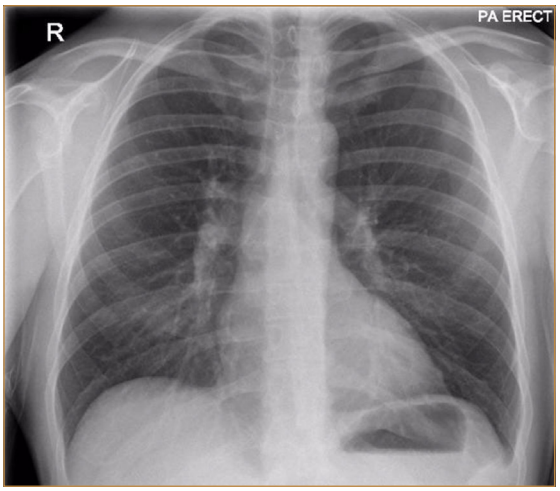

Figure 6. Demonstrates the resolution of the pneumothorax post needle aspiration with an 8Fr Rocket™ catheter.

patients who underwent surgery were 2.7% and 1.9%, respectively, highlighting the effectiveness of surgical management.[25]

Traumatic pneumothoraces

The current BTS guidelines include algorithms for the management of PSP and SSP but do not provide sufficient guidance when it comes to the management of traumatic pneumothoraces. Traumatic pneumothoraces can be broadly divided into non-iatrogenic and iatrogenic (barotrauma and procedure-related). The former are the 'true' cases of traumatic pneumothoraces secondary to penetrating injuries such as stab and gunshot wounds, or blunt injuries that lead to rib fractures. Such cases are managed as per the advanced trauma life support (ATLS) guidelines, and are not covered in this review.

Iatrogenic pneumothoraces have become more common as increasingly invasive diagnostic and therapeutic interventions have been adopted into clinical practice. According to Sharma and Jindal (2008), the top five causes are transthoracic needle aspiration or biopsy, subclavian vessel puncture, thoracocentesis, closed pleural biopsy and mechanical ventilation.[26] The BTS guidelines do not cover the management of such cases. However, we propose that the treatment of iatrogenic pneumothoraces should be based on the least invasive intervention and tailored to the patient's underlying lung health and clinical circumstances.

Case report 1

A forty-three year old male, with no past medical history but a high body mass index (37 kg/m^2), was admitted with a two day history of chest pain and dyspnoea. A chest radiograph on admission to his emergency department revealed the presence of a large left-sided pneumothorax (interpleural distance of 3.7cm at the level of the hilum) (Figure 5). The current BTS guidelines would classify this as a PSP, as the patient has no underlying lung disease and is a non-smoker. The BTS recommendation would be needle aspiration using a 16-18G cannula.

However, given the patient's high body mass index, this is unlikely to be successful. Both 16G and 18G cannulas are 45mm in length, and are unlikely to penetrate into the pleural space.[27] Many studies evaluating the ideal location for needle decompression of a tension pneumothorax have shown that the average chest wall thickness for men ranges between 38mm to 40mm at the second intercostal space and between 33mm to 39mm at the mid-axillary location.[28, 29] Obese individuals and those with muscular chest wall can have a chest wall thickness which is not amenable to safe needle aspiration.

In this case, the pneumothorax was aspirated through the use of a 8Fr Rocket™ catheter. A repeat film post aspiration showed negligible interpleural distance at the level of the hilum (Figure 6). The advantages of a Rocket™ catheter over a standard cannula are its length, a 3-way tap system and a collection bag, which at full capacity contains 2.5L of air. This is in accordance with BTS guidelines



Figure 7. Rocket™ Thoracentesis Set 8FG used for the drainage of air from the pleural space, credit to Rocket® Medical.

© 2018 Rila Publications Ltd.

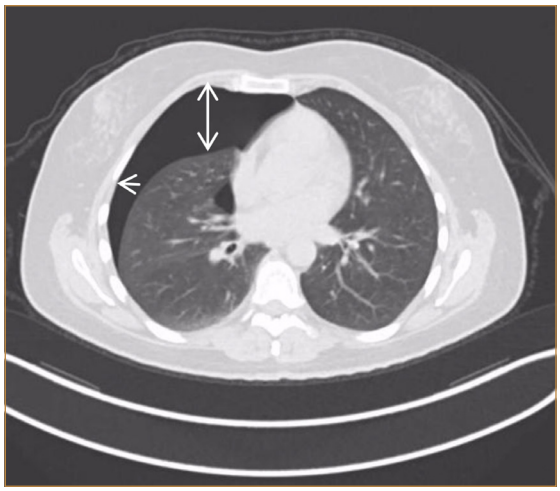

Figure 8. Demonstrates a right-sided pneumothorax on PET-CT.

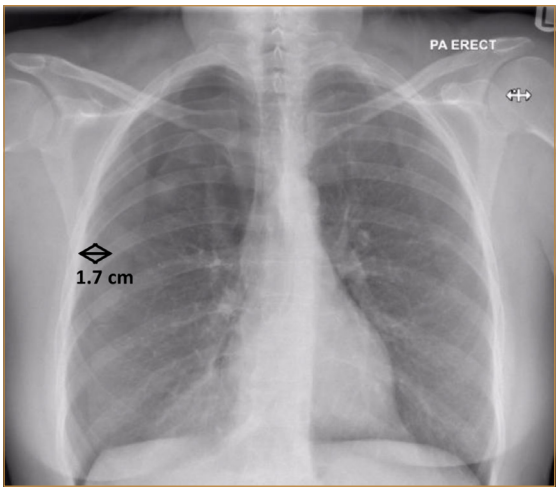

Figure 9. Right sided pneumothorax with an interpleural distance of 1.7cm.

which state that needle aspiration should stop after 2.5L of air has been aspirated. Although not part of the current BTS guidelines, we think that Rocket™ catheters may have a higher success rate for aspiration than the standard needle aspiration technique. With increasing obesity rates, we propose that acute medical physicians familiarise themselves with similar catheters (Figure 7) and consider individualisation of catheter length on a patient's body mass index.

Case report 2

A fifty-five year old female, who was being investigated for lung cancer, underwent a CT guided biopsy of a right upper lobe nodule at a local district hospital. A post-procedure chest radiograph did not show a pneumothorax and she was discharged home on the same day. A week later the patient attended the radiology department for a PET-CT (Position Emission Tomography-Computerised Tomography); this revealed a moderate to large right-sided pneumothorax, measuring 1.2cm at the level of the hilum on a chest radiograph (Figures 8 and 9). The patient was symptomatic, reporting chest tightness, but was particularly keen not to be admitted into hospital. The current BTS guidelines provide no guidance with respect to the management of iatrogenic pneumothoraces.

Taking into account the patient's wishes and relatively good health, the patient was managed with a Pleural Vent Device™ – which is a type of Heimlich valve (HV). HVs are lightweight one-way valves attached to a chest drain negating the need for attachment to an underwater seal (Figure 10 and 11). The use of this small portable device facilitated discharge and the patient was brought back for a chest radiograph via an ambulatory clinic. The Pleural Vent Device™ was removed at the clinic as the pneumothorax had resolved. Our institution has a wealth of experience as regards ambulatory management of pneumothoraces, having been the

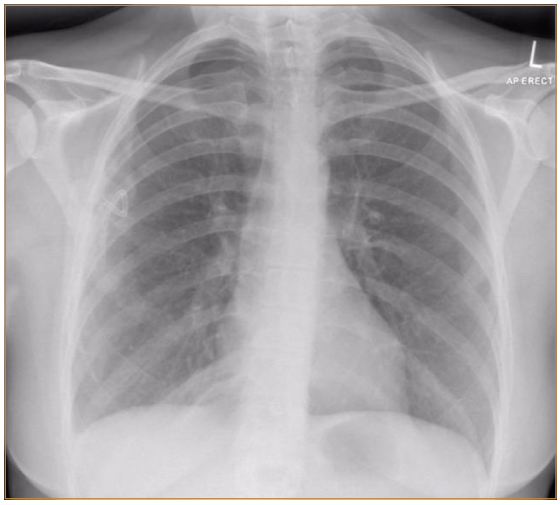

Figure 10. Radiograph taken post insertion of Pleural Vent Device™, with good re-expansion of lung.

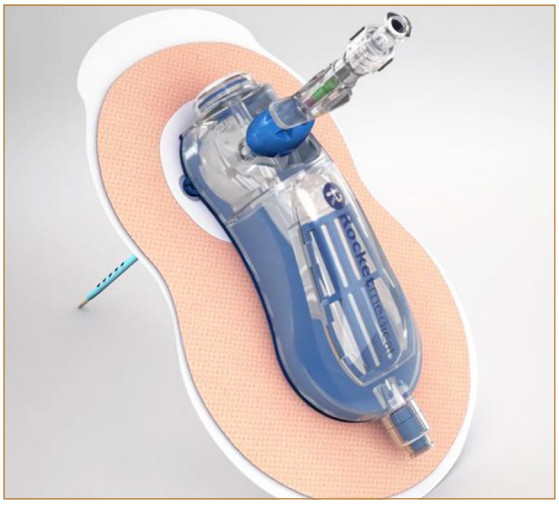

Figure 11. Pleural Vent Device™, credit to Rocket ® Medical.

© 2018 Rila Publications Ltd.

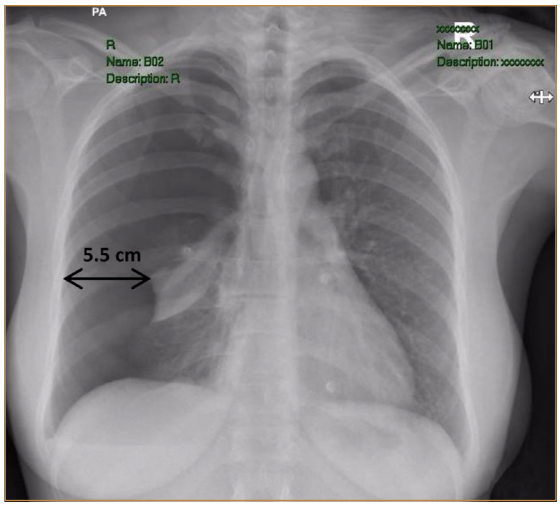

Figure 12. Right sided pneumothorax with an interpleural distance of 5.5cm.

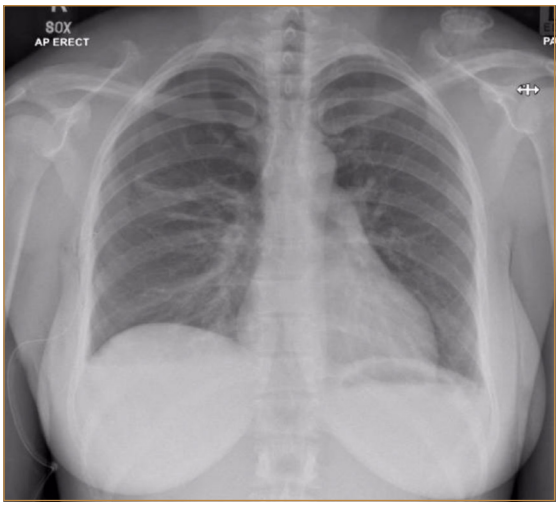

Figure 13. Chest radiograph one day post chest drain insertion, demonstrating good re-expansion of the lung.

first hospital to successfully ambulate patients with iatrogenic pneumothoraces post lung biopsy through the use of the HV.

Brims and Maskell (2013) were to first authors to conduct a meta-analysis of the literature looking at the evidence for the use of HVs in the ambulatory treatment of pneumothoraces.[30] Their review showed that HVs were used with good success rates in the outpatient management of iatrogenic pneumothoraces (reported at 97.5%), and minimal rates of complications. Similar success rates were reported in the ambulatory management of PSP (83.3%) and SSP (88.7%). However, the quality of the data used was moderate to poor with a high risk of bias, due to a lack of good quality randomised controlled trials in the literature. Nevertheless, the consensus from the two randomised controlled trials in the literature (Ho et al. (2011)[31] and Roeggla et al. (1996))[32] and the many observational studies is that the use of HVs is effective and safe.

The adoption of HVs into clinical practice could significantly reduce hospital admissions, and save the NHS 40 000 bed days per year, assuming that the HV is successful in the treatment of 80% of pneumothoraces. Our institution is one of twenty sites in the UK that are involved in a randomised controlled trial looking at the use of HV (Randomised Ambulatory Management of Primary Pneumothorax (RAMPP trial)).[33] The trial randomises patients with PSP to standard care as per BTS guidelines or a pleural vent device such as the HV. The primary outcome is the length of hospital stay in the first thirty days post pneumothorax. With many trusts already ambulating patients successfully with HVs, we recommend a change in practise as it is safe and cost effective. We hope that the RAMPP trial will merely confirm that.

Case report 3

A thirty-five year old female, with no past medical history and a non-smoker, presented to the emergency department with a one week history of dyspnoea and chest pain. The chest pain had started suddenly whilst on a road-trip in Belgium, with no precipitating factors. Her admission chest radiograph showed a large right sided pneumothorax (5.5cm at the level of the hilum), with near complete collapse of the right lung (Figure 12). BTS guidelines would classify this as a PSP, and the recommendation would be needle aspiration. However, many studies have shown that needle aspiration is unlikely to be successful if the pneumothorax size exceeds 50% of the lung volume.[34, 35]

Further, the patient was a keen traveller and wanted to continue with her annual driving ventures into Europe and was anxious to do this without a definitive management strategy. Accounting for this, the patient was admitted into the hospital and managed using a chest drain. The chest drain remained in situ for 1 day and a repeat chest radiograph showed significant resolution of the pneumothorax (Figure 13). The patient was discharged the following day with safety netting advice regarding flying and scuba diving. The patient was reviewed a week later and her pneumothorax had resolved completely.

This case illustrates to the acute medical physician that deviation from the BTS guidelines may be reasonable and the choice of management should be situation specific. The BTS guidelines do not take into consideration how long a patient has had a pneumothorax for, the actual size of the pneumothorax or the patient's concerns and wishes.

© 2018 Rila Publications Ltd.

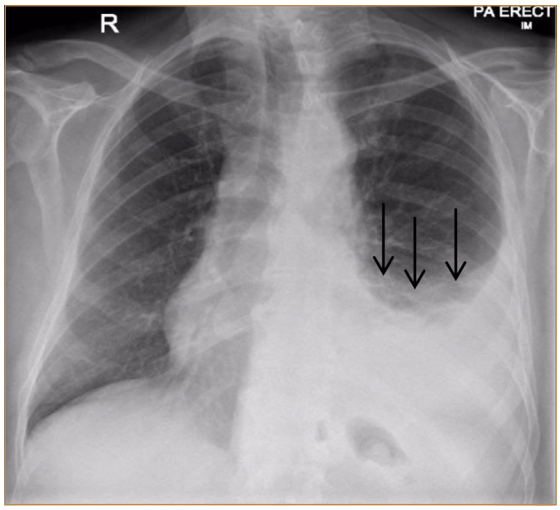

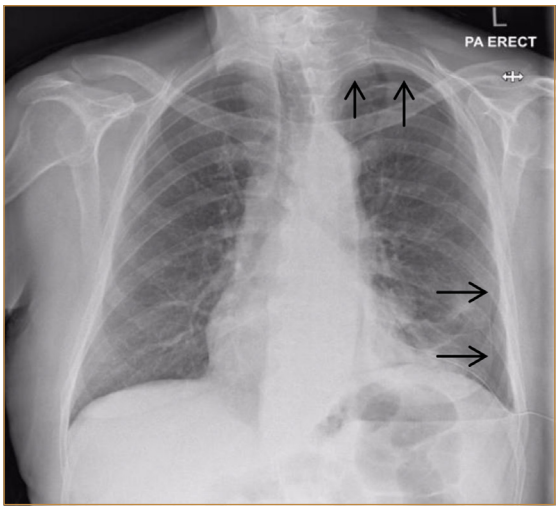

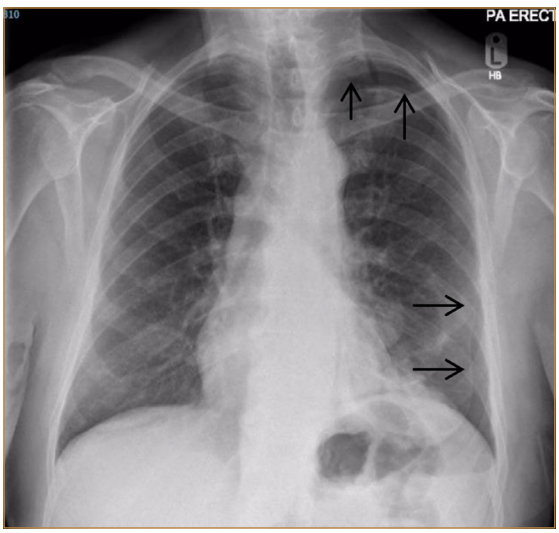

Figure 14-16. A series of chest radiographs taken over the space of 4 days. Figure 14 shows a moderate sized left-sided pleural effusion (arrows indicate pleural effusion). A left-sided intercostal drain is inserted (Figure 15) with good effect however the patient develops a small pneumothorax and hydropneumothorax (arrows indicate pneumothorax). This persists over the series of chest radiographs. On the final chest radiograph (Figure 16) the intercostal drain has been removed with no significant enlargement of the left sided pneumothorax (arrows indicate pneumothorax).

Case report 4

A seventy-four year old male, with metastatic adenocarcinoma of the lung that was complicated by recurrent pleural effusions requiring thoracenteses presented with breathlessness. A chest radiograph revealed a large left-sided pleural effusion (Figure 14); this was managed with a 12 Fr chest drain. Serial chest radiographs post procedure suggested pneumothorax / hydropneumothorax, which persisted (Figures 15 and 16). The static nature of the serial radiographs indicated trapped lung (pneumothorax ex vacuo) rather than true pneumothorax and therefore the chest drain was removed, with no significant enlargement of the pneumothorax on subsequent chest radiograph. Trapped lung is due to restricting fibrous visceral pleural thickening that develops from chronic inflammatory processes of the pleura and prevents lung re-expansion.[35] The non-compliant lung separates from the parietal pleura, and the pleural space fills with fluid, resulting in a hydropneumothorax. Drainage of the pleural fluid leads to pneumothorax ex vacuo because the lung cannot re-expand to fill the chest cavity. The diagnosis is confirmed by chronicity and stability of the pneumothorax and is commonly a consequence of malignant effusion and other inflammatory processes involving the pleura.[36]

The gold standard management of a malignant effusion in a patient with a good performance status is surgical pleurodesis via VATS (Videos Assisted Thoracoscopic Surgery).[37] This approach is not possible when the lung is trapped as apposition of the pleurae is impossible. This patient was managed with the use of an indwelling pleural catheter (IPC) (Figures 17 and 18). Patients with recurrent malignant pleural effusions who are unfit, or unsuitable, can be managed with an IPC as it enables outpatient management through periodic ambulatory fluid (and air) drainage. Bertolaccini et al. 2017 promote the use of IPC over surgical and medical pleurodesis in patients with poor performance status and short life expectancy as it minimises their length of stay in hospital.[38]

Although not a common condition, this case is aimed at making the acute medical physician aware of the condition. A trapped lung should be considered a differential diagnosis when there is a persistent pneumothorax post chest drain insertion.

Case report 5

A fifty-eight year old female, with systemic sclerosis attended a routine rheumatology appointment with chest pain and dyspnoea, following a one

© 2018 Rila Publications Ltd.

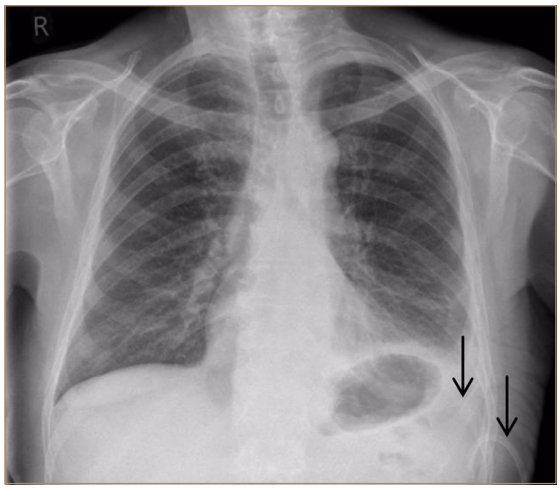

Figure 17. Stable appearances of the small left pleural effusion, left indwelling pleural catheter in situ (arrows indicate drain). The left apical pneumothorax has resolved.



Figure 18. Indwelling pleural catheter, credit to Rocket® Medical.[39]

week course of oral antibiotics for a presumed chest infection. A chest radiograph revealed a large left sided pneumothorax (3.1 cm at the level of the hilum) (Figure 19). As per BTS guidelines for SSP, a 12 Fr Seldinger drain was inserted. Although, the drain was bubbling and swinging suggesting patency, there was poor radiographic resolution of the pneumothorax (Figure 20).

The drain was clamped four days later, with no effect on the size of the pneumothorax (Figure 21). As a result, the drain was removed and the patient was discharged, with outpatient follow up. Five days later, the patient had repeat radiograph, which showed the persistence of the pneumothorax. She was referred to a local cardiothoracic centre for surgical intervention. The patient was initially managed conservatively with a large drain and thoracic suction, but as her lung did not expand satisfactorily, she underwent surgery. The patient had a left sided VATS bullectomy and talc pleurodesis.

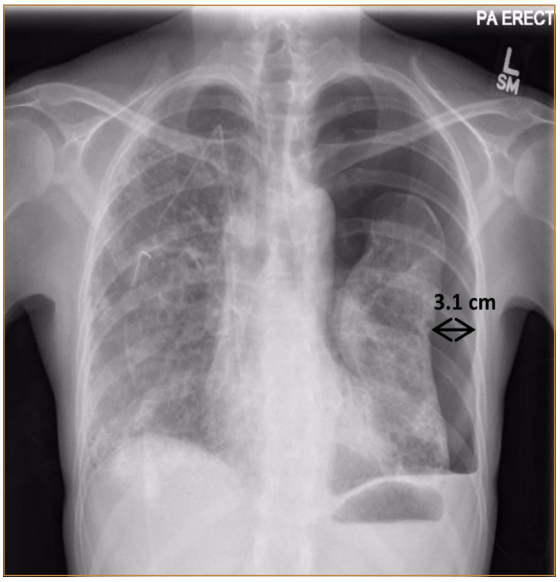

Figure 19. Left-sided pneumothorax with an interpleural distance of 3.1cm.

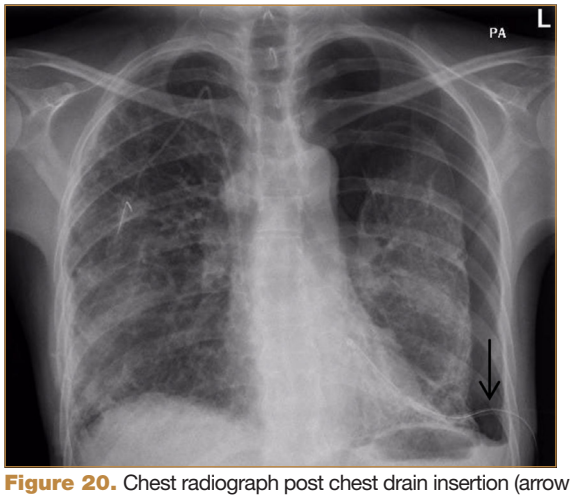

Figure 20. Chest radiograph post chest drain insertion (arrow indicates drain); no significant resolution of pneumothorax.

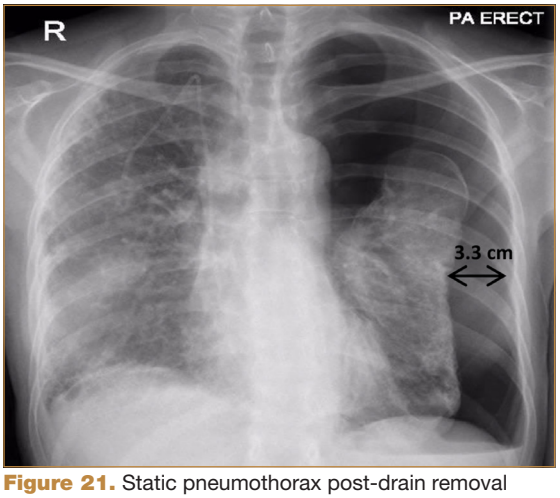

Figure 21. Static pneumothorax post-drain removal (interpleural distance of 3.3cm).

© 2018 Rila Publications Ltd.

The learning point from this case is that early referral to a thoracic surgeon is required when there is a persistent air leak/ non-resolution of the pneumothorax.

Conclusion

Treatment of pneumothorax should adhere to national and/or international guidelines where possible. Significant variation in practice may exist, where guidelines may not be all-encompassing. With a number of high-quality trials currently reviewing the standard care and the use of HVs in ambulatory management, the guidelines may need to become more nuanced in the future. This review of five case reports was designed to familiarise the acute medical physician with current trials, the use of new equipment such as thoracentesis catheters and to highlight that care should be increasingly personalised depending on the patient's wishes. Further, close collaboration between the acute medical and respiratory teams is recommended in cases where the patient does not fit exactly into the treatment framework advised by the BTS guidelines.

Conflict of interest

None declared.

References

1. Gupta D, Hansell A, Nichols T, *et al.* Epidemiology of pneumothorax in England. *Thorax* 2000; **55**:666-71.
2. Data from Health & Social Care Information Centre. 2018. www.hscic.gov.uk.
3. Maskell N. Pneumothorax management: time to improve the evidence base. *Thorax* 2017; **72(12)**:1065-1066.
4. Bauman M, Noppen M. Pneumothorax. *Respirology* 2004; **9**: 157–164.
5. Cheng Y, Huang T, Lin C, *et al.* The impact of smoking in primary spontaneous pneumothorax. *J Thorac Cardiovasc Surg* 2009; **138**: 192–95.
6. Bense L, Eklund G, Odont D, *et al.* Smoking and the increased risk of contracting pneumothorax. *Chest* 1987; **92(6)**:1009-12.
7. Donahue D, Wright C, Viale G, *et al.* Resection of pulmonary blebs and pleurodesis for spontaneous pneumothorax. *Chest* 1993; **104(6)**:1767-9.
8. Lesur O, Delorme N, Polu J, *et al.* Computed tomography in the aetiological assessment of idiopathic spontaneous pneumothorax. *Chest* 1990; **98(2)**:341-7.
9. Bense L, Lewander R, Eklund G, *et al.* Nonsmoking, non-alpha 1-antitrypsin defi ciency-induced emphysema in nonsmokers with healed spontaneous pneumothorax, identifi ed by computed tomography of the lungs. *Chest* 1993; **103(2)**:433-8.
10. Mitlehner W, Friedrich M, Dissmann W. Value of computer tomography in the detection of bullae and blebs in patients with primary spontaneous pneumothorax. *Respiration* 1992; **59**: 221–27.
11. Feldman A, Sullivan J, Passero M, *et al* Pneumothorax in polysubstance-abusing marijuana and tobacco smokers: three cases. *J Subst Abuse* 1993;**5**:183-6.
12. MacDuff A, Arnold A, Harvey J. Management of spontaneous pneumothorax: British Thoracic Society Pleural Disease Guideline. 2010. *Thorax* 2010;**65(Suppl 2)**:ii18-31.
13. Henry M, Arnold T, Harvey J. BTS guidelines for the management of spontaneous pneumothorax. *Thorax* 2003;**58(Suppl II)**:39e52. (4).
14. Baumann MH, Strange C, Heffner J, *et al.* Management of spontaneous pneumothorax: an American College of Chest Physicians Delphi consensus statement. *Chest* 2001;**119**:590–602.
15. Nakamura H, Konishiike J, Sugamura A, *et al.* Epidemiology of spontaneous pneumothorax in women. *Chest* 1986; **89(3)**:378-82.
16. Wakai A, O'Sullivan RG, McCabe G. Simple aspiration versus intercostal tube drainage for primary spontaneous pneumothorax in adults. *Cochrane Database Syst Rev* 2007; **24;(1)**:CD004479.
17. Parlak M, Uil S, Van den Berg J. A prospective, randomised trial of pneumothorax therapy: manual aspiration versus conventional chest tube drainage. *Respir Med* 2012;**106**:1600-5.
18. Archer G, Hamilton A, Upadhyay R, *et al.* Results of simple aspiration of pneumothoraces. *Br J Dis Chest* 1985; **79(2)**:177-82.
19. Markos J, McGonigle P, Phillips M. Pneumothorax: treatment by small-lumen catheter aspiration. *Aust NZ Med* 1990; **20(6)**:775-81.
20. Vedam H, Barnes D. Comparison of large- and small-bore intercostal catheters in the management of spontaneous pneumothorax. *Int Med J* 2003; **33(11)**:495-9.
21. Gammie J, Banks M, Fuhrman C, *et al.* The pigtail catheter for pleural drainage: a less invasive alternative to tube thoracostomy. *JSLS* 1999; **3(1)**: 57–61.
22. Bintcliffe O, Maskell N. "Spontaneous pneumothorax". *BMJ* 2014; 348.8
23. Sadikot R, Greene T, Meadows K, *et al.* Recurrence of primary spontaneous pneumothorax. *Thorax* 1997; **52**:805-9.
24. Hallifax R, Yousuf A, Jones H, *et al.* Effectiveness of chemical pleurodesis in spontaneous pneumothorax recurrence prevention: a systematic review. *Thorax* 2017; **72(12)**:1121-1131.
25. Onuki T, Ueda S, Yamaoka M, *et al.* Primary and secondary pneumothorax: prevalence, clinical features, and in-hospital mortality. *Can Respir J.* 2017; 2017:6014967.
26. Sharma A, Jindal P. Principles of diagnosis and management of traumatic pneumothorax. *J Emerg Trauma Shock* 2008; **1(1)**: 34–41.
27. Infusion therapy. BD Venflon™ Pro Safety Shielded IV Catheter. 2018. www.bd.com
28. Schroeder E, Valdez C, Krauthamer A, *et al.* Average chest wall thickness at two anatomic locations in trauma patients. *Injury* 2013; **44(9)**: 1183-5.
29. Lann D, Vu T, Thiels C, *et al.* Chest wall thickness and decompression failure: a systematic review and meta-analysis comparing anatomic locations in needle thoracostomy. *Injury* 2016; **47(4)**: 797-804.
30. Brims F, Maskell N. Ambulatory treatment in the management of pneumothorax: a systematic review of the literature. *Thorax* 2013; **68**:664-9.
31. Ho K, Ong M, Koh M, *et al.* A randomized controlled trial comparing mini chest tube and needle aspiration in outpatient management of primary spontaneous pneumothorax. *Am J Emerg Med* 2011; **29**:1152-7.
32. Roeggla M, Roeggla G, Muellner M, *et al.* The cost of treatment of spontaneous pneumothorax with the thoracic vent compared with conventional thoracic drainage. *Chest* 1996; **110(1)**:303.
33. Randomised ambulatory management of primary pneumothorax (RAMPP). 2018. www.isrctn.com
34. Chan S, Lam PK. Simple aspiration as initial treatment for primary spontaneous pneumothorax: results of 91 consecutive cases. *J. Emerg. Med.* 2005;**28**:133–138.
35. Ng A, Chan K, Lee S. Simple aspiration of pneumothorax. *Singapore Med. J.* 1994;**35**:50–
36. Huggins J, Doelken P, Steven S. The unexpandable lung. *F1000 Med Rep.* 2010; **2**: 77.
37. Roberts M, Neville E, Berrisford R, *et al.* Management of a malignant pleural effusion: British Thoracic Society Pleural Disease Guideline 2010. *Thorax*. 2010; **Suppl 2**:ii32-40.
38. Bertolaccini L, Viti A, Paiano S, *et al.* Indwelling Pleural Catheters: A Clinical Option in Trapped Lung. *Thorac Surg Clin*. 2017; **27(1)**:47-55.
39. PleurX™ proprietary valve and drainage features. 2018. www.bd.com

© 2018 Rila Publications Ltd.