Acute Med V9 N1:Acute Med V9 N1.qxd 22/02/2010 18:09 Page 13

Case Report

Tension pneumocephalus with cerebrospinal fluid rhinorrhoea in a post craniotomy patient

N H Smallwood & S Sreenivasan

Key points:
- Consider tension pneumocephalus in any patient presenting with non-specific neurological symptoms in the weeks following neurosurgery
- A history of possible CSF leakage should increase level of suspicion for this diagnosis.
- Early cranial imaging is crucial to ensure the diagnosis is made promptly.
- Urgent neurosurgical opinion is required where tension pneumocephalus is found

Abstract
Tension pneumocephalus is an uncommon but important complication of neurosurgery, often requiring urgent surgical intervention. It should be considered in any patient presenting with neurological symptoms after recent craniotomy, particularly if they also have clinical features consistent with cerebrospinal fluid (CSF) leak. We describe a patient who presented four weeks post-craniotomy with fluctuating neurological signs and CSF rhinorrhoea, who made a full recovery following repair of a frontal sinus defect and dural tear.

Keywords
Pneumocephalus, Cerebrospinal fluid rhinorrhoea.

Case report
An 84 year old man was seen in the Acute Assessment Unit four weeks following a craniotomy and excision of a left frontal meningioma. He had an uneventful recovery, and had been discharged from a rehabilitation ward with no residual focal neurologic deficit.

Three weeks later, the patient woke with an expressive dysphasia and weakness of the right arm and leg. This fluctuated over the following two days, and was associated with intermittent confusion. There was no history of fever or headache. The patient was subsequently referred by his general practitioner for medical assessment, with a presumptive diagnosis of acute stroke. He gave a past history of hypertension, but had no other risk factors for ischaemic cerebrovascular disease.

On examination, the patient had right-sided sensory neglect, as well as an expressive dysphasia. There was a mild right-sided hemiplegia, with pronator drift and incoordination of movements. Power examination was normal on the left side. Tone, sensation, and reflexes were equal bilaterally and normal. He was unable to stand unaided, with negative Rhomberg's sign. The remainder of his physical examination was unremarkable.

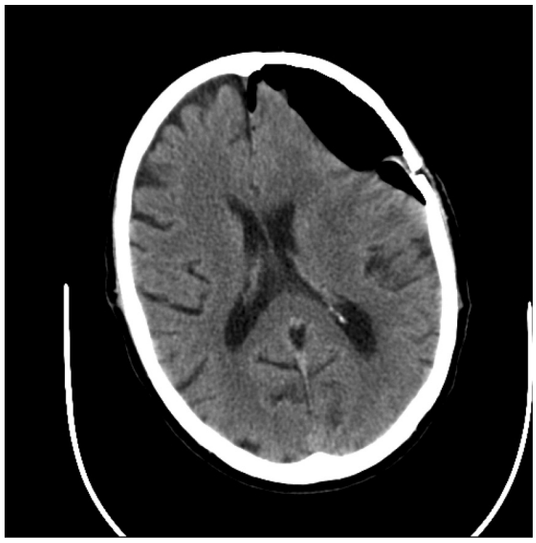

Figure 1. Section of CT head showing unilateral collection of left subdural air with mass effect causing midline shift.

Routine blood tests, including a full blood count, electrolytes, thyroid function, blood glucose and C-reactive protein, were unremarkable. Computed tomography (CT) of the head was performed (Figure 1). This revealed evidence of pneumocephalus exerting mass effect with midline shift away from the side of the abnormality. These features were consistent with a diagnosis of tension pneumocephalus.

On further direct enquiry, the patient described a persistent clear nasal discharge over the previous eight days, which he had frequently tried to clear by forcefully blowing his nose. These symptoms were suggestive of CSF rhinorrhoea, indicating a likely CSF leak following his surgery. This history had not been elicited prior to the CT diagnosis being made.

Nicholas H Smallwood
StR Acute Medicine,
Gloucester Royal Hospital

N Smallwood is an ACCS acute medical trainee (St2) based at Gloucester Royal Hospital, currently working in the Intensive Care Unit.

Shiva Sreenivasan
Consultant Acute Medicine,
Gloucester Royal Hospital

Correspondence:
Smallwood Nicholas H
StR Acute Medicine,
Department of Critical Care,
Gloucester Royal Hospital,
Great Western Road,
Gloucester,
GL1 3NN.
Email: nick.smallwood@gmail.com

© 2010 Rila Publications Ltd.

Acute Med V9 N1:Acute Med V9 N1.qxd 22/02/2010 18:09 Page 14

Tension pneumocephalus with cerebrospinal fluid rhinorrhoea in a post craniotomy patient

He was transferred urgently to the regional neurosurgical unit where he underwent repair of a frontal sinus and dural defect. On follow up four weeks later, he had no residual neurological deficit or symptoms of CSF leak.

Discussion

Intracranial air (pneumocephalus) is common after neurosurgical intervention and has been reported in up to 100% of supratentorial craniotomies.[1] Treatment is usually not required as the air is gradually absorbed. Tension pneumocephalus, however, is less common, and is most often seen in the immediate post-operative period, particularly where surgery involves the posterior fossa or is undertaken in the sitting position,[2] or following evacuation of chronic subdural haematomas.[3] It has also been reported as a complication of spinal surgery where nitrous oxide was used during anaesthesia.[4]

In addition to his neurological deficit, our patient described CSF rhinorrhoea for the eight days preceding his hospital admission, as a consequence of a frontal sinus and dural defect which acted as a portal of air entry into the subarachnoid space. It is likely that this dural tear functioned as a one-way valve, allowing air to collect intracranially under increasing pressure. The positive pressure needed to expand the pneumocephalus may have been generated from the patient blowing his nose to clear the CSF discharge. Alternatively, it has been proposed that loss of CSF through a dural defect results in negative intracranial pressure, which entrains air into the subarachnoid space, thus expanding a pneumocephalus.[5]

This case highlights the need to consider CSF leak and tension pneumocephalus in any patient who presents with new neurological features following recent craniotomy. A focused history to elicit symptoms of CSF leak and early imaging are essential in this category of patients in order not to miss this uncommon but important complication.

Acknowledgements

The authors would like to thank Dr P Birch for his help preparing the image

Competing Interests

None declared

References

1. Reasoner DK, Todd MM, Scamman FL, *et al*. The incidence of pneumocephalus after supratentorial craniotomy. Observations on the disappearance of intracranial air. *Anesthesiology*. 1994; **80**:1008–1012.
2. Prabhakar H, Bithal PK, and Garg A. Tension pneumocephalus after craniotomy in supine position. *J Neurosurg Anesthesiol*. 2003; **15(3)**: 278–81.
3. Bremer AM, Nguyen TQ. Tension pneumocephalus after surgical treatment of chronic subdural hematoma: report of three cases. *Neurosurgery* 1982; **11**: 284–287.
4. Theilen J, Heller AR, Litz RJ. Nitrous oxide-induced tension pneumocephalus after thoracic spinal cord surgery: a case report. *J Neurosurg Anesthesiol*. 2008; **20(3)**: 211–2.
5. McIntosh BC, Strugar J, Narayan D. Traumatic frontal bone fracture resulting in intracerebral pneumocephalus. *The Journal of Craniofacial Surgery*. 2005; **16(3)**: 461–3.

© 2010 Rila Publications Ltd.