A case to remember….

Syncope in the Hospital

Mark Mallet

Abstract

A case is presented in which a man with anomalous coronary artery anatomy and thrombotic coronary stenoses had an episode of syncope. Further subsequent presyncopal events coincided with ventricular tachycardia on ambulatory ECG; stenting of the lesions eliminated further symptoms. The importance of seeking prognostically significant cardiac causes of syncope is discussed.

Keywords

Syncope, ventricular tachycardia

Teaching point:

- Even in the absence of pre-existing heart disease, a cardiac cause should always be considered in cases of recurrent exertional syncope.

Case History

A 55 year old hospital porter presented to the Emergency Department with a blackout. Over the previous two weeks he had suffered a number of episodes of light-headedness on walking up stairs associated with chest discomfort. These had always passed on resting. He had had no significant illnesses in the past and was on no medication. On this occasion he had again noted light-headedness and chest discomfort, but despite resting he lost consciousness and fell to the ground. He recovered within a few seconds and was able to complete his task before attending the Emergency Department.

On examination he was in sinus rhythm, the rest of the physical examination was normal, and his 12 lead ECG and routine blood tests were unremarkable.

48 hour ECG monitoring was commenced later that day. During this period he had further episodes of pre-syncope but continued working. Analysis of the tape revealed that these coincided with periods of sustained polymorphic ventricular tachycardia (figure 1). Cardiac catheterisation was performed. This revealed anomalous coronary circulation with a single coronary artery arising from the right coronary sinus. There was a tight stenosis of the right coronary branch (figure 2). He was treated with aspirin and beta-blockade and underwent urgent percutaneous revascularisation. Following

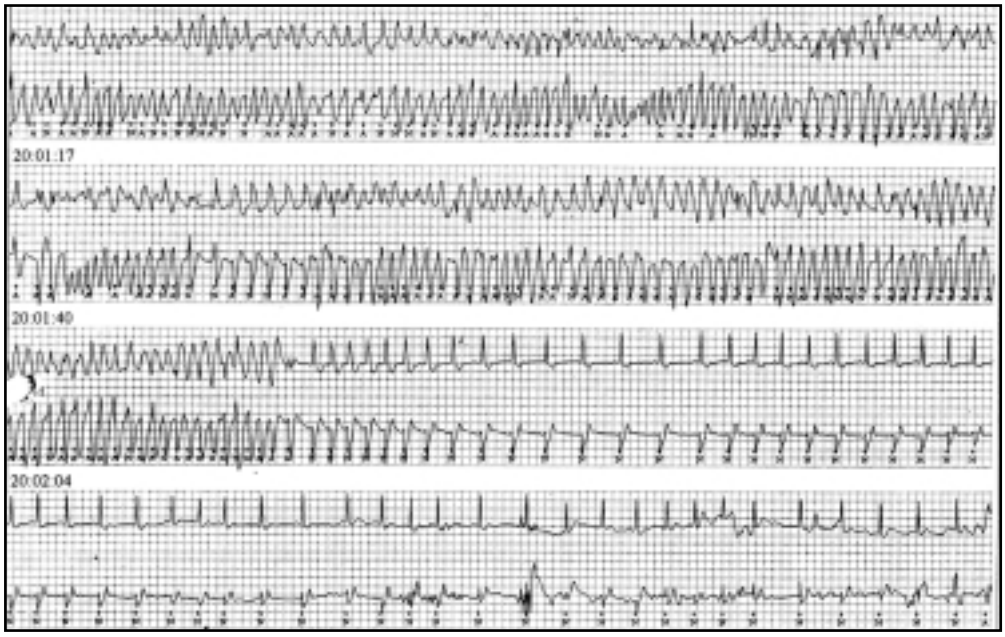

Figure 1 Ambulatory ECG showing ventricular tachycardia

Mark Mallet
MA MRCP

Correspondence:
Consultant Physician,
Medical Assessment Unit,
Royal United Hospital,
Bath, UK

discharge he was completely free of symptoms and was able to complete a treadmill test with no abnormalities.

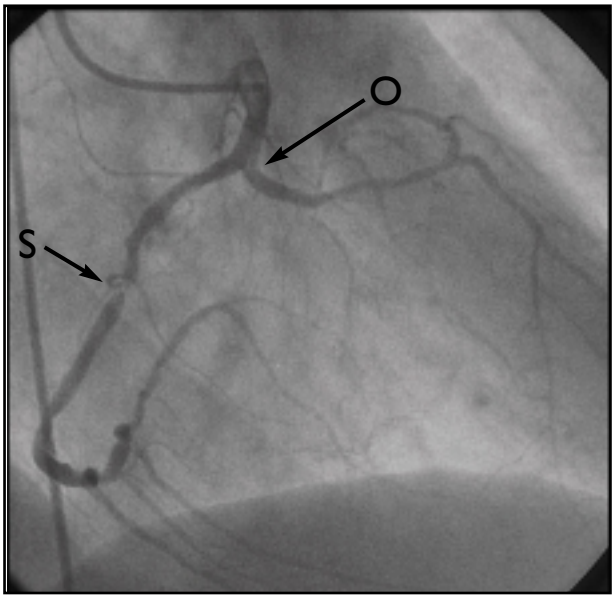

Figure 2 Coronary angiogram showing anomalous common origin of the coronary arteries (O), and tight right coronary artery stenosis (S)

Discussion

Syncope is defined as a sudden transient loss of consciousness with loss of postural tone and spontaneous recovery. The underlying mechanism is transient global cerebral hypoperfusion. The key questions in the evaluation of an apparent episode of loss of consciousness are (1) was this a syncopal event? (2) is the heart normal? and (3) does the history point to any specific diagnosis?[1]

In a number of studies the 1-year mortality from cardiac causes of syncope, such as obstructive lesions or arrhythmias, ranges between 18-33%, compared to non-cardiac causes (0-12%) or unexplained syncope (6%).[2] Patients at highest risk are those with severe left ventricular dysfunction, and attempts to risk-stratify syncopal patients show that age ≥ 45 years, history of heart failure, history of ventricular arrhythmias, and abnormal ECG predict arrhythmic syncope or death in up to 80% with three or more of these factors.[3]

Features in the history which point towards a possible cardiac cause of syncope include known cardiac disease, supine or exertional symptoms, and possibly associated palpitations.[4,5] It is useful to note the presence or absence of autonomic symptoms such as nausea, sweating or weakness, either before or after the event, which might suggest a vagally-mediated cause. A family history of sudden death, medication which might prolong the Q-T interval, and a short duration of symptoms are also important factors to elicit.

In patients who present following a syncopal event, the physical examination and ECG are often normal. The history therefore provides the basis for deciding who needs further investigation, and if so, how this should proceed. Since the majority of syncope is neurally mediated (vaso-vagal) and may not even present to hospital, it is vital to identify the minority who have significant underlying pathology. This case higlights the importance of maintaning a high index of suspicion for a cardiac cause, even in the absence of apparent risk factors. The association with exertion and prior chest discomfort were suggestive of myocardiac ischaemia; if the Holter Monitor had failed to detect any dysrhythmia, excercise testing would probably have been considered. Only if cardiac disease can confidently be excluded can the patient be fully reassured, in which case the prognosis is excellent.

Reference

1. Brignole M, Alboni P, Benditt D, *et al*. Task Force on Syncope, European Society of Cardiology. Guidelines on management (diagnosis and treatment) of syncope. *Eur Heart J* 2001; **22**:1256-1306
2. Kapoor W, Snustad D, Peterson J, *et al*. Syncope in the elderly. *Am J Med* 1986; **80**:419-28
3. Martin TP, Hanusa BH, Kapoor WN. Risk stratification of patients with syncope. *Annals Emerg Med* 1997; **29**:459-66
4. Alboni P, Brignole M, Menozzi C, *et al*. Diagnostic value of history in patients with syncope with or without heart disease. *J Am Coll Cardiol* 2001; **37**:1921-28
5. Oh JH, Hanusa BH, Kapoor WN. Do symptoms predict cardiac arrhythmias and mortality in patients with syncope? *Arch Intern Med* 1999; **159**:375-80