Acute Medicine V9 N2_V3_RM_Acute Med V9 N2.qxd 12/06/2010 11:28 AM Page 55

Aortic dissection: a review of the diagnosis and initial management

AL Thomson-Moore & M Papouchado

Key Learning Points
- The classical history and examination findings are found in only a minority of cases of aortic dissection
- Aortic dissection should be considered in any patient presenting with sudden onset, tearing chest pain
- Prognosis and treatment depends on the type of aortic dissection
- Endovascular stenting may become the treatment of choice for type B aortic dissection in the future

Abstract
Aortic dissection is a medical emergency which carries a high mortality, particularly if undiagnosed and untreated. The diagnosis may be overlooked because the 'classical' history, examination and imaging signs are present in only a minority of cases. After reflecting on the underlying pathophysiology, this review examines aspects of the history and examination which should alert Acute Physicians to a possible diagnosis of aortic dissection. The relative benefits of different imaging techniques are summarised, along with the prognosis and treatment for different types of aortic dissection. Finally a case of aortic dissection which went undiagnosed for a month is presented to illustrate some of the key teaching points raised in this article.

Keywords
Aortic dissection, dissecting haematoma, non-invasive imaging, endovascular stenting, presentation.

Aortic Dissection
Incidence and Pathophysiology
Aortic dissection occurs when the aortic intima dissects away from the adventitia, creating a false lumen through which blood flows. Population-based, longitudinal studies estimate an incidence of 2.9/100,000/year.[1]

Dissection can be spontaneous, traumatic or iatrogenic. There is an association with acquired and congenital vascular connective tissue diseases such as atherosclerosis, aortic syphilis, Marfans and Ehlers-Danlos Syndrome. In 10-30% of cases aortic dissections are preceded by an intimal tear/rupture which develops into an intramural haematoma, and then into a dissecting haematoma. The time interval between the initial intimal tear and development of the dissecting haematoma is usually more than eight days, but in some cases may be several weeks.[2]

As the blood dissects the aortic wall complications arise, such as aortic rupture, diffusion-dependent organ ischaemia, cardiac tamponade and aortic regurgitation.

Classification
Aortic dissection is classified according to the site of the dissecting haematoma. The original DeBakey classification has three divisions[3]
- Type I involves the ascending aorta, aortic arch, and descending aorta.
- Type II is confined to the ascending aorta.
- Type III is confined to the descending aorta distal to the left subclavian artery

The more commonly used Stanford Classification[4] comprises two divisions: Stanford A encompasses DeBakey Types I and II, and Stanford B, DeBakey Type III (see Figure 1). The site of the dissecting haematoma has important prognostic and management implications.

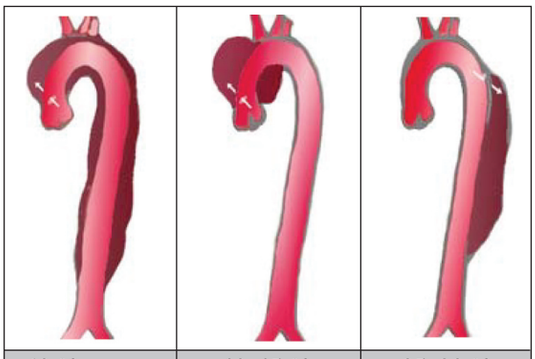

60 %	10-15 %	25-30 %
DeBakey I	DeBakey II	DeBakey III
Stanford A		Stanford B
Proximal		Distal

Figure 1. Classification of aortic dissection.

Dr AL Thomson-Moore
MA(Oxon) MBBChir (Cantab), ST2 ACCS, Southmead Hospital, Bristol.

Dr M Papouchado
MBBChir (Cantab) FRCP, Consultant Cardiology Southmead Hospital, Bristol

Correspondance:
Dr Alexandra Thomson-Moore
ICU, Southmead Hospital North Bristol Trust, Southmead Road, Westbury-on-trym, Bristol, Avon BS10 5NB
Email: 1977atm@doctors.org.uk

© 2010 Rila Publications Ltd.

Acute Medicine V9 N2_V3_RM_Acute Med V9 N2.qxd 12/06/2010 11:28 AM Page 56

Clinical Presentation and Medico-Legal Implications

There is no symptom or sign that is entirely sensitive or specific[5] for the diagnosis. In some cases, symptoms and signs relate entirely to hypoperfusion of a distal artery and its dependent structures.[6] Traditional teaching is that aortic dissection presents with:

- Sudden onset, 'tearing' chest pain (accurately describing the underlying pathophysiology);
- Blood pressure differential between right and left arm of more than 20mmHg, or carotid-peripheral pulse delay;
- Widened aortic knuckle or mediastinum on chest x-ray (CXR)

A prospective study of 41,495 presentations to an emergency department, of which 128 had a diagnosis of aortic dissection, found that each of these three variables is a statistically significant independent predictor for aortic dissection. However absence of all of these clinical variables occurred in 7% of cases. A blood pressure/pulse difference gave a high probability of aortic dissection (greater than 80%) whereas the other two variables in isolation gave a medium probability of aortic dissection, rising to high probability when found in combination.[7]

However, the international registry of aortic dissection in 2000 showed that, whereas 83% of presentations had sudden tearing chest pain, only 15.1% had a pulse delay[8] and 39% widening of the mediastinum and/or aortic knuckle on CXR. With a good history of sudden onset, tearing chest pain, perhaps in association with other symptoms or signs that fit the diagnosis, aortic dissection cannot be ruled out by the absence of a pulse delay and a CXR with a mediastinum of normal width.

Canadian courts have found doctors liable where given a history of sudden onset, tearing chest pain they failed to consider aortic dissection by documenting normal pulses and symmetrical blood pressures and treated for a diagnosis that did not fit the entire clinical picture (e.g. making a diagnosis of musculoskeletal chest pain where the patient

	Advantages	Disadvantages	Sensitivity (%)	Specificity (%)
TTE	More readily available than TOE. Can be performed at the bedside in critically ill patients. No exposure to ionising radiation or contrast.	Poor sensitivity due to poor visualisation of important structures.	59.3	83
TOE	Can be performed at the bedside in critically ill patients. No exposure to ionising radiation or contrast. Can determine coronary artery involvement and cardiac function.	Not readily available and invasive. Proximal aortic arch obscured and cannot define the extent of abdominal involvement. Poor specificity due to false positives in the ascending aorta.	97.7	76.9
CT	Non invasive, readily available and rapid. Allows distinction of Type A from Type B, and the extent of aortic and end organ involvement. Precursors to aortic dissection, such as intramural haematoma, can be visualised and their progression to an aortic dissection predicted.	The use of contrast may be contraindicated. Exposure to ionising radiation. Involvement of the coronary arteries or aortic valve is difficult to determine but this is improving with technological advances.	93.8	87.1
MRI	Non invasive with no exposure to ionising radiation or contrast. Provides excellent information on the shape and length of the dissection including branch involvement.	Not readily available and expensive. Critically ill patients are unmonitored for a long time. Claustrophobia and metal work, e.g. pacemaker are contraindications.	98.3	97.8
Sensitivity = [TP/TP+FN] where TP is True Positive and FN is False Negative; Specificity = [TN/TN+FP] where TN is True Negative and FP is False Positive				

Figure 2. Advantages and disadvantages of different imaging techniques
TTE = trans-thoracic echocardiogram; TOE = transoesophageal echocardiogram; CT = computed tomography; MRI= magnetic resonance imaging

© 2010 Rila Publications Ltd.

Acute Medicine V9 N2_V3_RM_Acute Med V9 N2.qxd 12/06/2010 11:28 AM Page 57

was also vomiting and had visceral pain). Where documentation noted the absence of any of the classic three variables in an unusual presentation (e.g. isolated nerve palsy), doctors have been found not guilty.[9]

Non Invasive Imaging and Chemical Markers

Three dimensional imaging of the aorta can provide a more accurate assessment of its calibre than a CXR. The reliability of each of these imaging modalities in diagnosing aortic dissection needs to be understood in order to be able to interpret the results (see Figure 2).

Although magnetic resonance imaging (MRI) provides the highest sensitivity and specificity, practical constraints mean that CT is the most commonly used imaging modality in this country and is often the investigation of choice in local guidelines.[10] The National Institute of Clinical Excellence (NICE) has not produced any guidelines for the investigation of aortic dissection to date. The advantages and disadvantages of each imaging technique also need to be considered in (see Figure 2).

A number of chemical markers such as serum soluble elastin fragments and D-dimer have also been identified as markers suggestive of aortic dissection.[11] Serial measurements of smooth muscle myosin heavy chain antibodies has been shown to have a 90% sensitivity and 97% specificity in predicting progression from aortic haematoma to aortic dissection.[12] Work is ongoing to see whether these biochemical markers could be used clinically. Although elevated D-dimer is a common finding in the context of acute aortic dissection the low specificity of this test means that it cannot be recommended in the initial diagnostic strategy. However clinicians should be mindful that elevation of D-dimer in the context of chest pain and collapse does not always imply pulmonary embolism.

Treatment and Prognosis

Treatment and prognosis depend on the site of the dissecting haematoma.

Type A Dissection

Patients with Type A aortic dissections have a poorer prognosis. The higher mean arterial pressure can lead to aortic rupture and contribute to a greater rate of dissection, Dissection of the aortic root is associated with cardiac tamponade, aortic regurgitation and occlusion of the coronary ostia, while the aortic arch is the site of origin of the carotid and subclavian arteries. The aim of surgery is to relieve symptoms and minimise complications.

Despite the better outcomes with open surgical intervention for type A aortic dissection (see Figure 3), patients need to be pre-selected. Age greater than 70 has been shown to be an independent risk factor for mortality with open surgical intervention.[15] However survival for octogenarians who undergo open surgery for Type A aortic dissection remains respectable at 51% at 1 year and 44% at 5 years, and is even higher where patients are preselected and those who are moribund, shocked or needing aortic arch replacement are excluded.[16]

	Type A aortic dissection	Type B aortic dissection
Medical Management	60	10
Open Surgical Intervention	30	20-30
Endovascular stenting	-	10

Figure 3. In-hospital mortality (%) for type A and B aortic dissection.[13 14]

Type B Dissection

Type B aortic dissection is less common and typically runs a more indolent course with an overall survival rate of 82.4% at 24 hours[17] and 77% at three years.[18] The majority are therefore treated conservatively. Blood pressure is lowered by reducing cardiac output (using intravenous beta blockers or calcium channel blockers) and/or peripheral vascular resistance (intravenous sodium nitroprusside or isosorbide dinitrate). A systolic blood pressure of 100-120mm Hg is desirable, however adequate organ perfusion needs to be maintained so a target mean arterial blood pressure needs to consider co-morbidities such as ischaemic heart disease. Continuous blood pressure readings with an arterial line should be established and additional monitoring of the central venous pressure, urine output, urea, creatinine and haemoglobin levels and Glasgow Coma Score (GCS) may be judged to be beneficial. Appropriate analgesia with paracetamol and opiates should also be instituted. Non-steroidal anti-inflammatory drugs are best avoided as the renal function is already at risk from hypoperfusion.

Open surgical intervention in type B aortic dissection is considered when complications such as aortic rupture or ischaemia of diffusion dependent organs seems likely. This is established by symptoms of persistent/recurrent chest pain, imaging showing an expanding dissecting haematoma and signs of ischaemia in diffusion dependent organs. Patency of the false lumen is a strong independent prognostic indicator for progression of the dissecting haematoma. Surveillance programs have shown that where blood flow through the false lumen is arrested, thrombosis leading to healing of the dissection is more likely to be achieved.[19] Dilation of the distal aortic arch also carries a greater risk of progression.[20]

The advent of endovascular stenting provides an alternative definitive treatment to open surgical interventions using a less invasive technique. This is where much of the current research around aortic dissection is focused. In-hospital and two year mortality data, comparing stenting and open surgery, shows endovascular stenting has better outcomes than open surgical interventions (see Figure 3); The INSTEAD (INvestigation of STEnt grafts in patients with type B Aortic Dissection) trial is ongoing to review longer term outcomes.[16] If the long term mortality data remains low endovascular stenting may prove to be the treatment of

© 2010 Rila Publications Ltd.

Acute Medicine V9 N2_V3_RM_Acute Med V9 N2.qxd 12/06/2010 11:28 AM Page 58

choice for all type B aortic dissections in the younger population given the relative longevity they require from their aorta. In light of these surgical advances all presentations of aortic dissections should be discussed with the cardiothoracic team.

All patients should receive long term anti-hypertensive treatment and ongoing surveillance using three-dimensional imaging.

Case History

An 82 year old lady, treated for hypertension but otherwise fit and healthy, described a one month history of chest pain. Initially the pain had been abrupt in onset and 'tearing' in nature, located on the anterior chest wall. The pain was exacerbated by movement, such as when she drew water from her well or cycled to the village shop. Over the month the pain had become constant, more severe, radiated into her back and had rendered her almost chair bound. She had been seen by three different GPs who had all found her to be haemodynamically stable with no audible heart murmur or pulse differential. The pain was treated as 'musculoskeletal', with a range of analgesics, none of which gave her relief. Due to her progressive deterioration she was referred to the on-call medical team for further investigation.

Admission clerking elicited the same history and examination findings. Initial investigations revealed anaemia and acute renal failure (see Figure 4).

The CXR (Figure 5a) showed mediastinal widening and the calcium sign which had not been present on a CXR taken four months earlier (Figure 5b). Based on these appearances and the abnormal renal function, aortic dissection was considered likely, with probable extension to the renal arteries.

Haemoglobin	10.1 g/dl
Urea	45.1 mmol/l
Creatinine	1123 µmol/l
eGFR	3 mL/min

Figure 4. Blood results on admission.

She underwent urgent trans-thoracic echocardiogram (TTE) along with abdominal ultrasound. Her poor renal function precluded CT with contrast. The TTE provided only limited views of the aortic arch, but appearances were felt to be 'highly suspicious' of aortic dissection. Renal ultrasound revealed a mild left hydronephrosis, with normal sized kidneys and a normal abdominal aortic calibre.

The likely diagnosis and its implications were discussed with the patient. She declined further investigations and interventionthough given her renal function, an MRI was felt to be the three-dimensional imaging modality of choice. She was never discussed with the cardiothoracic team. Her condition deteriorated progressively and she died one week after admission.

Points for Reflection

In aortic dissection the initial complaint of sudden, tearing chest pain is due to a tear of the aortic intima from the adventitia. The dissecting haematoma can occur days later and this in part explains why a CXR is often unhelpful with a normal cardiac contour and no widening of the mediastinum. At this stage even non-invasive three dimensional imaging may miss a small intimal tear. Furthermore whilst chronic dilatation of the aorta increases the risk of aortic dissection, the intima of a chronic aortic aneurysm is often intact and widening of the mediastinum alone is not diagnostic of aortic dissection. Indeed the term dissecting aneurysm is misleading and 'dissecting haematoma' may be a better term.

In the case presented the diagnosis was delayed due to failure to consider the significance of the initial abrupt,

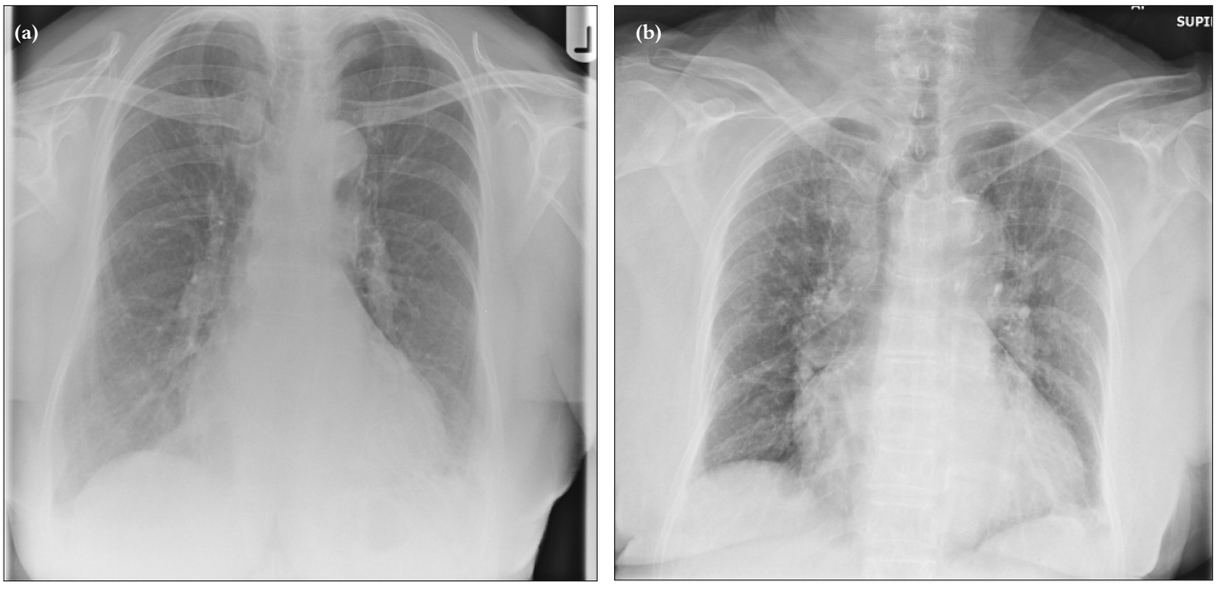

Figure 5: (a) CXR taken four months prior to her admission. **(b)** CXR showing widened mediastinum with the Calcium Sign: >10mm between calcified intima and outer border of aorta. This is very suggestive of a dissecting haematoma.

© 2010 Rila Publications Ltd.

Acute Medicine V9 N2_V3_RM_Acute Med V9 N2.qxd 12/06/2010 11:28 AM Page 59

'tearing' chest pain. Although initially the pain showed features which were consistent with a musculoskeletal cause, and medico-legally the absence of pulse/blood pressure differential was repeatedly documented, by the time she was referred to hospital the severe renal impairment and her general decline left her with a high mortality risk even if she had been considered for surgery.

Conclusion

Aortic dissection may be missed if undue reliance is made on 'classic' signs that are not found in a large proportion of cases. It should be considered in any patient presenting with sudden onset, tearing chest pain. A normal CXR does not reliably exclude the diagnosis, and patients may initially remain relatively active.

References

1. Meszoros I, Morocz J, Szlavi J *et al*. Epidemiology and Clinicopathophysiology of aortic dissection. A population based longitudinal study over 27 years. *Chest* 2000; **117(5)**: 1271–1278.
2. Estrera A, Miller C, Lee TY *et al*. Acute type A intramural haematoma. Analysis of current management strategy. *Circulation* 2006; **114**: II 432.
3. DeBakey ME *et al*. Surgical management of dissecting aneurysms of the aorta. *J Thorac Cardiovasc Surg* 1965; **49**: 130–49.
4. Daily PO *et al*. Management of acute aortic dissections. *Ann Thorac Surg* 1970; **10(3)**: 237–247.
5. Khan IA. Clinical Manifestations of Aortic Dissection. *J Clin Basic Cardiology* 2001; **4**: 265–267.
6. Hsin-Chien C *et al*. Hoarseness as an unusual presentation of aortic dissection. *Eur Arch Oto-Rhino-Laryngology* 2005; **262(3)**: 189–191.
7. Von Kodlitsch Y *et al*. Clinical prediction of acute aortic dissection. *Archives of Internal Medicine* 2000; **160**: 2977–2982.
8. Hagan PG *et al*. International registry of acute aortic dissection: new insights into an old disease. *JAMA* 2000; **283**: 897–903.
9. https://www.cmpa-acpm.ca/cmpapd04/docs/resource_files /risk_id/2008/com_ri0812-e.cfm
10. http://www.imagingpathways. health.wa.gov.au/includes /pdf/aort_d.pdf
11. Patel PD *et al*. Pathophysiology, diagnosis and management of aortic dissection. *Therapuetic Advances in Cardiovascular Disease* 2008; **6**: 439–468.
12. Suziku T *et al*. Biochemical diagnosis of aortic dissection: from bench to bedside. *Japanese Heart J* 1999; **40(5)**: 527–534.
13. Estrera AL, Miller CC, Goodrick J *et al*. Update on outcomes of acute type B aortic dissection. *Ann Thorac Surg* 2007; 83: S842–S845.
14. Fattori R, Thomas T, Tsai MD *et al*. Complicated Acute Type B Dissection:is surgery still the best option? *J Am Coll Cardiol Intv,* 2008; **1**: 395–402.
15. Mehta R, O'Gorman P, Bossone E *et al*. Acute type A aortic dissection in the elderly: clinical characteristics, management, and outcomes in the current era *J Am Coll Cardiol,* 2002; **40**: 685–692.
16. Piccardo A, Regesta T, Zannis K, *et al*. Outcomes after surgical treatment for type A acute aortic dissection in octogenarians: a multicenter study. *Ann Thorac Surg*. 2009 Aug; **88(2)**: 491–7.
17. Kunishige H, Myojin K, Ishibashi Y *et al*. Predicotrs of surgical indications for acute type B aortic dissection based on enlargement of aortic diameter during the chronic phase. *Japanese Journal of Cardiovascular and Thoracic Surgery* 2006; **54(11)**; 477–82.
18. Nienaber CA, Zannetti S, Barbieri B, *et al*. INvestigation of STEnt grafts in patients with type B Aortic Dissection: design of the INSTEAD trial—a prospective, multicenter, *European randomized trial Am Heart J* 2005; **149**: 592–599.
19. Lumsden AB, Reardon MJ. Once dissected always dissected! Can stent grafts change the natural history of type B dissections? A report from the international registry of acute aortic dissection. *J Am Coll Cardiol Intv*; **1**: 403–4.
20. Akutsu K, Nejima J, Kiuchi K *et al*. Effects of the patent false lumen on the long-term outcome of type B acute aortic dissection. *Eur J Cardiothorac Surg*. 2004 Aug: **26(2)**: 359–66.

© 2010 Rila Publications Ltd.