Acute Medicine V10 N4:Acute Med 11/19/2011 2:41 PM Page 206

Case Reports

Serotonin Syndrome: An unusual cause of acute confusion and fever in the elderly

GP Misselbrook & R Shekhar

Key Learning Points
- Serotonin syndrome should be considered in the differential diagnosis of delirium in elderly patients taking serotonergic medications
- Serotonin syndrome is usually precipitated by the introduction of, or increase in dose of serotonergic drugs
- Addition of certain P450 cytochrome inhibitors, including macrolide antibiotics, may precipitate serotonin syndrome by inhibiting metabolism of the serotonergic drug
- A detailed drug history, including any recently prescribed medications, is essential to enable diagnosis of serotonin syndrome in elderly patients

Abstract
Delirium is a common cause for hospital admission among elderly patients. Although infection is the most common explanation, there is a large number of other potential causes. We present a case of acute delirium due to serotonin syndrome, precipitated by concomitant prescription of clarithromycin and fluoxetine. The symptoms improved following treatment with a benzodiazepine and discontinuation of the fluoxetine. The diagnosis and management of serotonin syndrome is discussed.

Case History
An 89-year old female was referred by her general practitioner to the acute medical unit (AMU) with a five-day history of increasing confusion, hyperthermia, hyperhydrosis and muscle rigidity. She had started clarithromycin for a presumed respiratory infection on the day her symptoms had appeared. There were no symptoms of urinary tract infection (UTI) and the cough had since resolved.

The patient had been living in a residential home since admission to hospital two months previously with a UTI and recurrent falls. There was a past medical history of hypertension and recurrent UTI for which she took long-term trimethoprim 100mg daily. Her other drug history included ramipril 2.5mg daily and fluoxetine 20mg daily. Fluoxetine had been started during her admission to rehabilitation two months ago, after her fall. She was normally able to walk a few yards with assistance but now required a hoist to be transferred due to the muscle rigidity.

Admission observations revealed an irregular pulse of 112 beats/minute, temperature of 37.5°C, respiratory rate 30 breaths/minute, blood pressure 137/68 and oxygen saturation 95% on air. Glasgow Coma Scale was 14/15, with marked cognitive impairment. On examination the patient was diaphoretic and warm to touch. Cardiovascular, respiratory and gastrointestinal examination were otherwise unremarkable. Neurological examination revealed generalised muscle rigidity with extra-pyramidal posturing with inducible clonus, fine tremor, widespread hyperreflexia and upgoing plantar reflexes bilaterally. Pupils were grossly dilated bilaterally and responsive to light. Electrocardiogram revealed fast atrial fibrillation; chest x-ray and urine microscopy and subsequent culture were unremarkable. Her oral medications, including the fluoxetine and clarithromycin were omitted, and she was treated initially for presumed recurrent UTI with intravenous (IV) tazobactam and piperacillin and IV fluids. Her blood results were unremarkable apart from a raised creatinine kinase (CK) of 337 IU/l (normal range 55-170 IU/l). Specifically the renal function, CRP and white cell count were normal.

Over the next 24 hours her temperature rose to 39°C and the muscle rigidity worsened. A diagnosis of serotonin syndrome was suspected and the patient was given 0.5mg midazolam subcutaneously. This resulted in a significant improvement in cognition and muscle rigidity with resolution of fever and diaphoresis. Fluoxetine was discontinued and the patient was commenced on a subcutaneous midazolam infusion of 5mg/24hrs. After 48 hours of this treatment the patient's rigidity and confusion had improved significantly, so that she was able to eat and drink. Oral diazepam was continued for a further week and physiotherapy was required for a number of weeks to improve the residual muscle rigidity, whilst the fluoxetine was fully eliminated. A CT Scan of the head one week after admission revealed no intracranial abnormalities.

Gary Peter Misselbrook
MBBS, Foundation Year Two Senior House Officer, Queen Elizabeth Foundation Hospital Kings Lynn NHS Trust

Raj Shekhar
MBBS, MD, MRCP, Consultant Stroke Physician, Queen Elizabeth Foundation Hospital Kings Lynn NHS Trust

Correspondence:
Gary Misselbrook
Norfolk and Norwich University Hospital, Colney Lane
Norwich
NR4 7UY
Email: garymisselbrook@doctors.org.uk

© 2011 Rila Publications Ltd.

Acute Medicine V10 N4:Acute Med 11/19/2011 2:41 PM Page 207

Action	Medications
Excess of serotonin or agonists	Lithium L-tryptophan Buspirone
Increased release of serotonin	Amphetamines 3,4-methylenedioxymethamphetamine (Ecstasy) Sibutramine Fenfluramine
Reduced reuptake of serotonin	Selective serotonin reuptake inhibitors (e.g. fluoxetine, sertraline, citalopram) Tricyclic antidepressants (e.g. amitriptyline, nortriptyline) Serotonin-norepinephrine reuptake inhibitors (e.g. venlafaxine) Serotonin 2A receptor blockers (e.g. trazadone) Opioid analgesics (e.g. tramadol, pethidine, fentanyl) St. John's Wort
Reduced serotonin metabolism	Monoamine oxidase inhibitors (e.g. phenelzine, selegiline) Linezolid
Others	Carbamazepine Triptans (e.g. sumatriptan, rizatriptan) Metoclopramide

Table 1. Drugs associated with serotonin toxicity.

P450 cytochrome subtype	Common Inhibitor
CYP2D6	Selective serotonin reuptake inhibitors Terbinafine Amiodarone Chlorphenamine Antipsychotics Cimetidine Cocaine Metoclopramide Ritonavir
CYP3A4	Protease inhibitors Macrolide antibiotics Azole antifungals Grapefruit juice (Bergamottin) Verapamil Ciprofloxacin Metronidazole Mifepristone Transcriptase inhibitors

Table 2. Commonly used CYP2D6 and CYP3A4 inhibitors that have the potential to increase the toxicity of selective serotonin reuptake inhibitors.

Discussion

Serotonin syndrome is a potentially life-threatening drug reaction due to excessive serotonergic activity (mostly 5-HT_{2A} overstimulation) in the central and peripheral nervous system.[1] The majority of cases are iatrogenic from increases in serotonergic agent doses or synergistic medication use, but intentional self-poisoning with serotonergic drugs may also occur. Serotonin toxicity occurs in about 18% of patients who overdose with SSRIs and causes death in 0.2% of overdoses.[2] A large number of drugs from various classes can cause serotonin syndrome (Table 1). Introduction of drugs that inhibit the cytochrome P450 isoenzymes in people already taking selective serotonin reuptake inhibitors (SSRIs) may also precipitate serotonin syndrome (Table 2).[3]

Fluoxetine is a substrate for mainly CYP2D6 but also CYP3A4 isoenzymes, as well as a major inhibitor of CYP2D6. Clarithromycin, which was presumed to be the precipitating factor for the serotonin toxicity in this case, is a potent inhibitor of CYP3A4 and therefore would have a small inhibitory effect on fluoxetine metabolism. Whilst serotonin toxicity caused by fluoxetine would be more likely with a potent CYP2D6 inhibitor such as terbinafine, there are case reports of fluoxetine-induced serotonin syndrome precipitated by concurrent clarithromycin use.[4] Genetic variation in cytochrome P450 expression is also recognised, and this may have played a part in the development of serotonin toxicity from the concurrent use of clarithromycin in our patient. While it is unusual to see serotonin syndrome in such low doses of fluoxetine, our patient was frail and elderly with a low body mass index, which may have increased her susceptibility.

Delirium is a common presenting complaint in elderly patients and has numerous causes, including urinary and chest sepsis.[5] The lack of response to antimicrobial therapy in this case, along with the normal inflammatory markers, normal chest x-ray and negative urine culture, along with the raised CK triggered consideration of serotonin syndrome as a cause for these symptoms. The muscle rigidity was also a new feature which could not be explained by the presumptive diagnosis of UTI; there was no prior history of parkinsonism or anti-dopaminergic drug use.

Symptoms of serotonin toxicity include a triad of cognitive, autonomic and somatic effects. Somatic features of neuromuscular excitability include clonus, hyperreflexia, myoclonus and rigidity. Autonomic symptoms include fever >38°C, hyperhidrosis, tachycardia, tachypnoea and diarrhoea. Cognitive symptoms of confusion, elevated mood or agitation may also be present. These symptoms usually appear within hours of the initiation or increase in dose of the serotonergic drug. Complications include disseminated intravascular coagulation (DIC), renal failure secondary to rhabdomyolosis, metabolic acidosis and acute respiratory distress syndrome.[6]

There is no specific test available for confirmation of serotonin syndrome. Blood results may show a leucocytosis, elevation of creatinine kinase, raised liver transaminases and lower bicarbonate levels.[6] As a result, diagnostic criteria such as the Hunter Serotonin Toxicity Criteria have been developed to aid diagnosis (Figure 1).[7] The diagnosis requires one of the groups of features in Figure 1 with a history of administration of a serotonergic

© 2011 Rila Publications Ltd.

Acute Medicine V10 N4:Acute Med 11/19/2011 2:41 PM Page 208

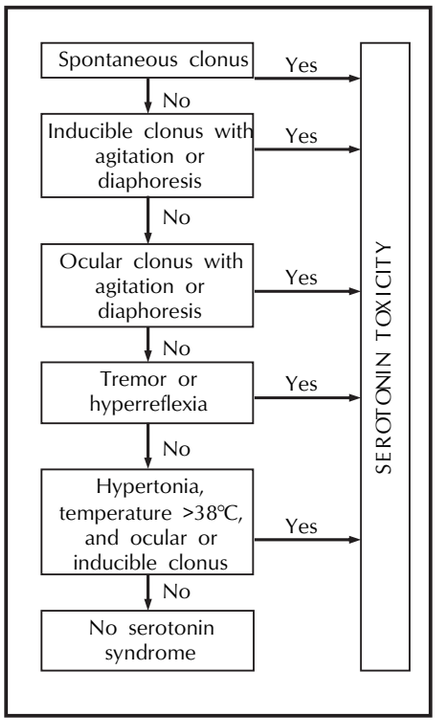

Figure 1. Hunter's decision rules for diagnosis of serotonin toxicity. Adapted with permission from Dunkley EJ, Isbister GK, Sibbritt D *et al.* The Hunter Serotonin Toxicity Criteria: simple and accurate diagnostic decision rules for serotonin toxicity. *QJM*. 2003; **96(9):** 635-642.

drug. These criteria have been found to be a sensitive (84%) and specific (97%) measure of serotonin toxicity.[7] Our patient had inducible clonus with diaphoresis, temperature >38C, tremor, hypertonia and hyperreflexia, meeting the criteria in three categories.

Neuroleptic malignant syndrome is an important differential diagnosis to consider. This can be differentiated by an absence of neuromuscular excitability, presence of dysphagia and hypersalivation, and a drug history containing neuroleptic medications. Other differential diagnoses should include sepsis, tetanus, herpes simplex encephalitis, overdose of sympathomimetic drugs, meningitis, thyroid storm, heat stroke, delirium tremens, acute baclofen withdrawal and malignant hyperthermia.[8]

The initial management of serotonin syndrome should include cessation of any serotonergic medications. Mild cases generally resolve within 24 to 72 hours with conservative therapy alone and do not usually require hospital admission. For patients with hyperthermia, autonomic instability or severe cognitive changes, hospital admission should occur for intensive monitoring. IV fluids should be given to avoid the risk of myoglobinuria. Benzodiazepines may be used for control of agitation and tremor. While there are no specific antidotes for serotonin syndrome, patients may benefit from the antihistamine cyproheptadine – a 5-HT_{2A} antagonist. An initial oral dose of 12mg should be given, followed by an additional 2mg every two hours if symptoms continue. Once the patient is stable a maintenance dose of 8mg QDS may be given.[3] Active cooling, sedation and intubation, and anticonvulsants may be required for serious cases.

Along with discontinuation of fluoxetine and clarithromycin, our patient received subcutaneous midazolam which provided rapid improvement in her symptoms. Cyproheptadine was not available initially and the oral route was not suitable due to the patient's muscle rigidity and reduced conscious level. Although there was a good initial response to midazolam, the short half-life of midazolam meant that repeated doses were needed to prevent recurrence of the muscle rigidity and delirium. An infusion was administered for 48hrs and oral therapy with diazepam started as soon as the patient was able to tolerate oral intake. Cyproheptadine was later felt to be unnecessary due to her response to benzodiazepines alone.

Patients with serotonin syndrome often improve within 24 hours, although symptoms can symptoms can persist in up to 40% of cases, particularly if modified release preparations have been used.[6] Metoclopramide should be avoided in serotonin syndrome as it may increase the already long half-life of fluoxetine (4-6 days).[9] Our patient still suffered from a degree of muscle rigidity four weeks later after presentation, requiring ongoing physiotherapy; this may have reflected the persistence of fluoxetine which may occur for up to six weeks after discontinuation.

References

1. Whyte, IM. Serotonin Toxicity/Syndrome. Medical Toxicology. Philadelphia 2004, *Williams and Wilkins,* 103-6.
2. Lai MW, Klein-Schwartz W, Rogers GC, *et al.* 2005 Annual Report of the American Association of Poison Control Centers' national poisoning and exposure database. *Clin Toxicology (Phila)*. 2006; **44(6-7):** 803-932.
3. Ables AZ, Nagubilli R. Prevention, diagnosis and management of Serotonin Syndrome. *American Family Physician*. 2010; **81(9):** 1139-1142.
4. Pollak PT, Sketris IS, MacKenzie SL, *et al.* Delirium probably induced by clarithromycin in a patient receiving fluoxetine. *Ann Pharmacother.* 1995; **29(5):** 486-488.
5. Young J, Inouye SK. Delirium in older people. *BMJ*. 2007; **334:** 842-846.
6. Birmes P, Coppin D, Schmitt L, *et al*. Serotonin syndrome: a brief review. *Canadian Med Assoc J*. 2003; **168(11):** 1439-1442.
7. Dunkley EJ, Isbister GK, Sibbritt D, *et al.* The Hunter Serotonin Toxicity Criteria: simple and accurate diagnostic decision rules for serotonin toxicity. *QJM*. 2003; **96(9):** 635-642.
8. Isbister GK, Buckley NA, Whyte IM. Serotonin toxicity: a practical approach to diagnosis and treatment. *Med J Australia*. 2007; **187(6):** 361-365.
9. Richelson E, Souder T. Binding of psychotropic drugs to human brain receptors, focus on newer generation compounds. *Life Sci*. 2000; **68:** 29-39.

© 2011 Rila Publications Ltd.