Cerebrospinal Fluid analysis in Suspected Subarachnoid Haemorrhage

Dr S Hill & Dr A Pinto

Abstract

Aneurysmal subarachnoid haemorrhage (SAH) is an acute life-threatening neurological disorder. A delay in diagnosis can lead to substantial and avoidable morbidity and mortality. It is important to identify patients with SAH promptly, to enable specialist referral to neurosurgical centres. This review aims to provide an up-to-date practical guide concerning the interpretation of spinal fluid results in patients with suspected SAH.

Keywords

Subarachnoid haemorrhage, CSF, spinal fluid; spectrophotometry, analysis, detection, diagnosis

Key Points

- Never ignore a thunderclap or "worst ever" headache
- CT cannot fully exclude SAH, and the sensitivity falls with time post ictus
- LP must follow CT brain scan if the CT scan is negative for SAH unless there is a clear clinical contraindication
- LP should be performed >12 hours after the ictal event to allow discrimination between traumatic tap and SAH
- The presence of bilirubin in the CSF is critical in confirming SAH
- CT brain scan and LP are less reliable at identifying patients with SAH presenting more than two weeks from headache onset

Introduction

Accurate early recognition of subarachnoid haemorrhage (SAH) is critical. Unfortunately errors continue to occur in diagnosis because clinicians either fail to appreciate the spectrum of presentation or fail to follow recognised investigation pathways.[1,2] Patients who are initially given the wrong diagnosis often re-present in a clinically worse state when intervention is less likely to change outcome. The aim of this article is to clarify some of the areas which commonly cause confusion in relation to the diagnostic tests for SAH, focussing in particular on the timing, analysis and interpretation of cerebrospinal fluid (CSF) obtained at lumbar puncture (LP).

- Nausea / vomiting
- Pyrexia
- Photophobia
- Meningism / neck pain
- Transient loss of consciousness
- Seizures
- Focal neurological signs

Table 1. Examples of non-headache symptoms occurring in patients with SAH

Clinical Features

The clinical features of SAH are well recognised and have been reviewed in depth in previous articles in this journal. Suspicion of SAH is usually raised by the patient's description of 'thunderclap' headache (developing in seconds to minutes and often described as 'the worst headache of my life'), resulting in the need for further investigation. Associated symptoms are described in Table 1. It should be remembered that spontaneous resolution of symptoms, or relief of headache by simple analgesia does not exclude the diagnosis of SAH.

Diagnostic Tests for Subarachnoid Haemorrhage

Imaging

An unenhanced CT brain scan is the initial investigation of choice for suspected SAH. The sensitivity of modern CT, interpreted by an experienced radiologist, may be as high as 98% if the investigation is performed within twelve hours of onset of symptoms with a negative predictive value of 97.5%.[3,4] However it is essential to realise that both of these figures are below 100%. Furthermore, sensitivity of CT falls with time as blood is reabsorbed.[5] The CT scan should therefore be requested urgently, as blood in the subarachnoid space is immediately apparent, and there is no merit in delay. In practical terms, patients presenting outside normal working hours with a normal Glasgow Coma Score and without focal neurology can probably wait for CT brain scan early the following day.

Lumbar Puncture

Lumbar Puncture (LP) should follow a negative CT in ALL patients, unless an alternative diagnosis is made with the imaging results or contra-indicated by clinical state (papilloedema, reduced

Dr Stephen Hill
BM MRCP
Medical Registrar
Portsmouth Hospitals

Dr Ashwin Pinto
MA BM BCh MRCP
DPhil
Consultant Neurologist,
Southampton University
and Portsmouth Hospitals.

Correspondence:
Dr A Pinto
Consultant Neurologist,
Wessex Neurological
Centre
Southampton University
Hospitals NHS Trust
Tremona Road
Southampton SO16 6YD

Cerebrospinal Fluid analysis in Suspected Subarachnoid Haemorrhage

consciousness or focal neurological deficit).[6,7] Research has shown that failure to perform a LP following a negative CT brain scan is an important factor leading to the misdiagnosis of SAH[2] (Figure 1).

LP should be done twelve hours after the onset of headache in order for the spectrophotometry to be interpreted correctly and avoid a false negative result.[6] The most experienced clinician should undertake the task as traumatic taps can lead to misinterpretation and false positive results.[7] Opening pressure should always be measured as it may help with the differential diagnosis of thunderclap headache if the analysis of the CSF does not support SAH (for example cerebral venous sinus thrombosis).

Four samples should be collected sequentially[6]

1. One fluoride oxalate (or EDTA) tube with a minimum of 0.5ml (biochemistry- protein, glucose).
2. Two 28ml sterile universal containers (labelled '2' and '3') with approximately 2.5ml in each, sent to microbiology for cell counting.
3. One 28ml sterile universal container, labelled '4' containing at least 1ml for spectrophotometry. This should be covered immediately to protect it from the light (e.g. thick envelope or foil) as this causes degradation of bilirubin to deoxyhaemoglobin.

One ml of CSF represents about twenty drops from a 21 G spinal needle. A blood sample for serum bilirubin, protein and glucose should be sent at the same time. It is important to make the laboratory aware that a CSF sample for suspected SAH has been obtained so that the lab can prepare for analysis. The time of the onset of headache and time of the LP need to be clearly documented in the medical notes and on the request form so that the results of oxyhaemoglobin and bilirubin spectrophotometry can be correctly interpreted. Samples should not be sent in pneumatic delivery devices, as this may case artefactual haemolysis,[8] but prompt delivery to the laboratory is important so that the sample can be centrifuged as quickly as possible.

Interpretation of Lumbar Puncture results

Subarachnoid haemorrhage is invariably associated with a blood-stained appearance of CSF at lumbar puncture. An acellular CSF from an LP performed within 48hr of headache onset effectively excludes SAH. Unfortunately, a blood-stained CSF appearance may also be caused by the needle puncturing a blood vessel before entering the subarachnoid space (traumatic tap). When blood-stained CSF is observed at LP, some authorities recommend the "three tube test" (a decrease in red blood cells in consecutive tubes) to distinguish SAH from a traumatic tap. However, this test is notoriously unreliable and has now been replaced by CSF spectrophotometry. This will accurately distinguish SAH from a traumatic tap as long as the procedure is performed more than 12 hours after headache onset.

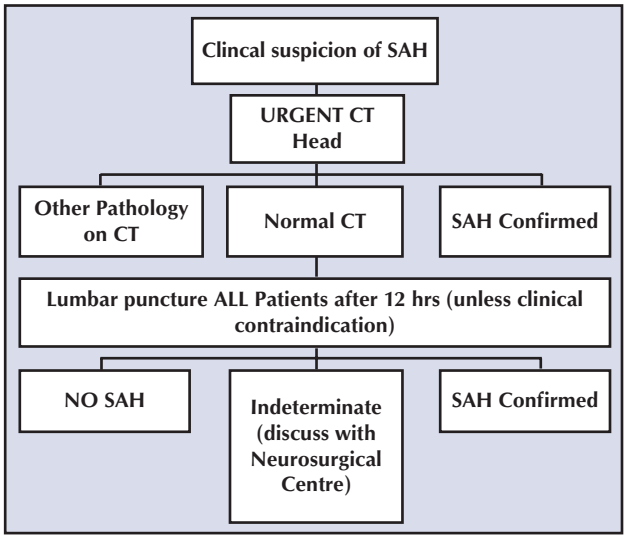

Figure 1. Summary of investigation of Suspected SAH

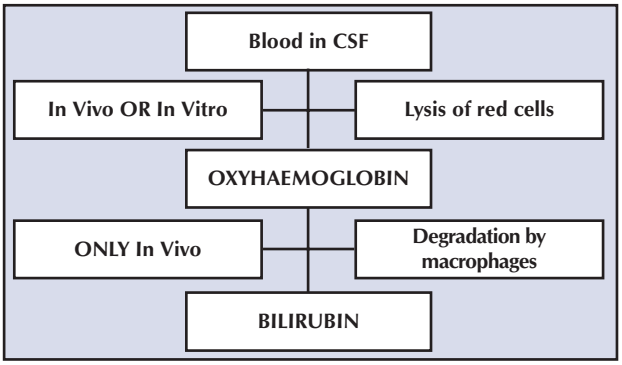

Figure 2. Degradation of blood in CSF

Blood in the cerebrospinal fluid (CSF) undergoes lysis within hours (Figure 2). This liberates oxyhaemoglobin, which gradually converts into bilirubin due to the action of macrophages and other cells in the leptomeninges. This conversion ONLY occurs in vivo and thus it is the detection of bilirubin in the CSF greater than twelve hours after onset of symptoms which is essential in the diagnosis of SAH. The elevated bilirubin will usually be accompanied by an elevated oxyhaemoglobin (which continues to form in vitro). Significant amounts of oxyhaemoglobin can mask a rise in bilirubin on spectrophotometry. Blood introduced to the sample as a result of a traumatic tap will not lead to increased bilirubin, unless the CSF is heavily contaminated (approx 402000/mm^3 Red Blood Cells).[9] Elevated serum bilirubin frequently results in elevation of CSF bilirubin level, which may complicate interpretation of the results (Figure 3).

The various haem pigments in the CSF give rise to a yellow discolouration- 'xanthochromia' (first described in 1902), which can be shown on visual inspection (unreliable) or spectrophotometry. The definition of xanthochromia is ambiguous as the term includes detection of all pigments derived from red cell breakdown including oxyhaemoglobin, methaemoglobin and bilirubin. The National Guidelines for CSF analysis in SAH[6] have given a method for calculating individual

If serum bilirubin is >20mmol/l adjust the CSF bilirubin by the following equation:

Net Bilirubin Absorbance (NBA) = measured NBA – Predicted absorbance (PA)

$$\text{Where PA} = \frac{\text{CSF protein}}{\text{Serum Total protein(g/L)}} \times \text{Serum bilirubin (mmol/L)} \times 0.042$$

Figure 3. Correction of CSF bilirubin for elevated Serum bilirubin

bilirubin and oxyhaemoglobin absorbance on spectrophotometry and advice on how to interpret results (Figure 4).

A CSF protein of >1000mg/l may lead to indeterminate results. If the tap contains several red cells, it may cause an artificially high protein level. The true CSF protein concentration can be calculated by subtracting 10mg/l for every 1000 RBCs/mm^3.

A raised oxyhaemoglobin alone is an unusual finding in subarachnoid haemorrhage but does not exclude the diagnosis because a significantly elevated oxyhaemoglobin peak can mask a CSF bilirubin peak. In these cases it is important to clearly check the timing of symptoms in relation to the LP (something that should have been done prior to the procedure) and discuss with the operator regarding the possibility of any local trauma. Repeat LP will be difficult to assess as blood may have been introduced to the subarachnoid space after the first attempt which may lead to a false positive result. However it is worth considering a repeat LP, after discussion with the Regional Neurosurgical Centre, as a negative result (for both oxyhaemoglobin and bilirubin) would still be helpful in excluding SAH. Furthermore cerebral angiography has a small, but increased morbidity compared to LP (1.8% risk of transient or permanent neurological complication[10]).

It is unclear how long CSF bilirubin persists after SAH. Most authorities agree that a negative CSF bilirubin within two weeks of an acute headache is sufficient to exclude a significant SAH. However CT brain scan and CSF analysis are less reliable at identifying patients with SAH presenting more than two weeks from headache onset and all such cases should be discussed with the local neurologist or regional neurosurgical unit.

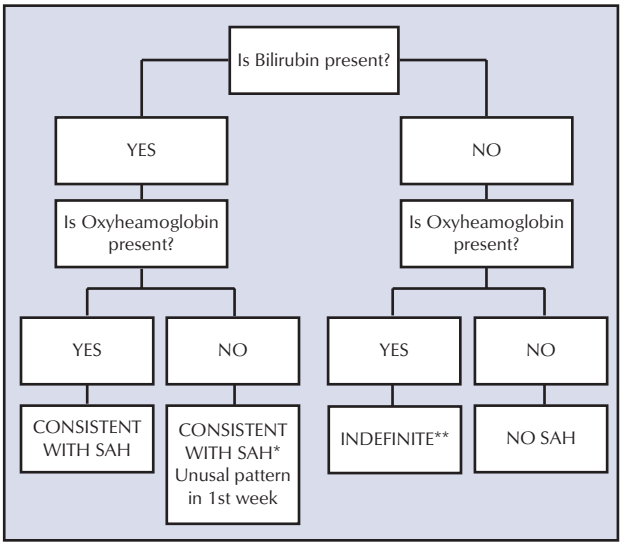

Figure 4. CSF interpretation decision tree

*If CSF protein is >1000mg/L, may be consistent with SAH, and increased bilirubin accompanying the CSF protein or other source of CSF blood. Interpret with caution in relation to SAH, especially if within the first week. Make sure CSF bilirubin has been adjusted for an elevated serum bilirubin

**Oxyhaemoglobin has a low predictive value alone, and if significantly elevated (may occur with a traumatic tap) can mask elevated bilirubin

References:

1. Edlow J, Caplan, L. Avoiding Pitfalls in the Diagnosis of Subarachnoid Haemorrhage. *The New Eng Jl Med* 2000; **342**: 29
2. Schofield M, Lorenz E, Hodgson T, Yates S, Griffiths P. How Well Do We Investigate Patients With Suspected Subarachnoid Haemorrhage? *Postgrad Med J* 2004; **80:** 27-30
3. Van der Wee N, Rinkel J, Hansen D, Van der Gijn J. Detection of Subarachnoid Haemorrhage on Early CT. *J Neurol, Neurosurg Psych* 1995; **58**: 357-359
4. Morgenstern L *et al*. Worst Headache and Subarachnoid Haemorrhage: Prospective, Modern Computed Tomography and Spinal Fluid Analysis. *Ann Emerg Med* 1998; **32**: 297-304
5. Kassell N, Torner J, Haley E, Jane J, Adams H, Kongable G. The International Cooperative Study on the Timing on Aneurysm Surgery. Part 1- Overall Management *Results. J Neurosurg* 1990; **73**: 18-36
6. Beetham R *et al* (UK National External Quality Assessment for Immunochemistry Working Group). National Guidelines for Analysis of Cerebrospinal Fluid in Suspected Subarachnoid Haemorrhage. *Ann Clin Biochem* 2003; **40**: 481-488
7. Cruickshank A. CSF Spectrophotometry in the Diagnosis of Subarachnoid Haemorrhage. *J Clin Pathol* 2001; **54**: 827-830
8. Wendman P, Hanson T, Ashby J. Interference in Spectrophotometric Analysis of Cerebrospinal Fluid by Haemolysis Induced by Transport Through a Pneumatic Delivery Tube System. *Ann Clin Biochem* 2001; **38**: 371-375
9. Criuckshank A, Smith L. Traumatic Tap Contamination of Cerebrospinal Fluid. *Proc Path* 2000; 15-17