Case Report

Bedside Point-of-Care Ultrasound of an Adult with Diffuse Intermittent Abdominal Pain

JC Nwanaji-Enwerem & A Landry

Keywords
Suprasternal Notch, Ultrasound, POCUS

Case History

A 29-year-old woman with a history of obesity status post Roux-en-Y gastric bypass greater than five years prior presented to the emergency department with four hours of sudden-onset stabbing left-sided abdominal pain associated with nausea and non-bloody emesis. She denied melaena and hematochezia, but did report two weeks of diarrhoea that was unchanged with this new onset abdominal pain.

Her vital signs were within normal limits with the exception of a blood pressure of 102/69. Physical exam was notable for left, mid, and upper abdominal tenderness with palpation and voluntary guarding. Initial investigations of urine hCG were unremarkable. Serum labs demonstrated no evidence of leukocytosis or anaemia. Electrolytes, liver function, renal function, lipase, and lactate were all within normal limits. Bedside point-of-care ultrasound of the abdomen was performed, which suggested the diagnosis (Figure 1) and expedited the appropriate consultation.

Questions

1. What sign can be observed on the bedside abdominal ultrasound image?
2. What disease process is associated with this sign?
3. What are the common causes of this disease process in a patient of this age group?

Answers

1. The bedside abdominal ultrasound image with the probe in the longitudinal view demonstrates the "pseudokidney" sign.[1]
2. The "pseudokidney" sign is associated with intussusception.[1]
3. The majority of adult cases of intussusception can be attributed to structural or pathologic lesions of the bowel wall or bowel lumen. This can include adhesions, lymphoid hyperplasia, malignant/benign tumours, and foreign bodies.[2]



Figure 1. Abdominal bedside point-of-care ultrasound.

Case Outcome

Bedside point-of-care abdominal ultrasound demonstrated the classic "pseudokidney" sign concerning for intussusception (arrow, Figure 2A) and subsequently expedited surgical consultation and CT imaging. CT abdomen and pelvis confirmed the diagnosis as jejunal intussusception (arrow, Figure 2B) and the patient was emergently taken for laparoscopy. Given inability to reduce intussuscepted bowel laparoscopically, open reduction and resection of perforated bowel was performed (arrow, Figure 2C). Her postoperative course was uneventful, and she was doing well with normalised bowel function and no recurrent abdominal pain at her 1-week follow-up visit.

Discussion

Intussusception, the telescoping of a region of bowel into the lumen of an adjacent bowel segment, is classically observed in paediatric populations where it presents as abdominal pain, vomiting, and currant-jelly stools.[3] The occurrence of intussusception is rarer in adults – only 5% of all cases of intussusception are observed in adults – and usually presents with non-specific symptoms of nausea and periodic, intermittent abdominal pain.[4] The non-specificity of these presenting symptoms when paired with

Jamaji C Nwanaji-Enwerem
Ph.D.
MD-PhD Program, Harvard Medical School, Boston, MA, USA

Adaira Landry
MD, MEd
Department of Emergency Medicine, Brigham and Women's Hospital, Harvard Medical School, Boston, MA, USA

Correspondence
Jamaji C Nwanaji-Enwerem
Ph.D.
MD-PhD Program, Harvard Medical School
25 Shattuck St, Boston, MA 02115, USA
Email: jamaji_nwanaji-enwerem@hms.harvard.edu

© 2020 Rila Publications Ltd.

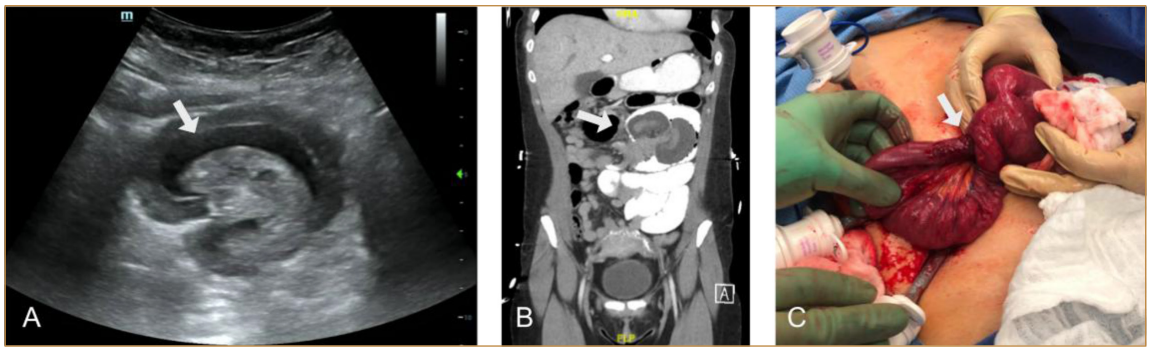

Figure 2. Bedside point-of-care abdominal ultrasound demonstrating intussuscepted bowel (arrow, panel A). Diagnosis of intussuscepted bowel was confirmed with CT abdomen and pelvis (arrow, panel B). The pathology was ultimately reduced in the operating room (arrow, panel C).

the rarity of disease occurrence in adults can result in the diagnostic delays that can negatively impact patient prognosis.[5] The present case and others in the literature suggest that bedside point-of-care abdominal ultrasound (POCUS) as a first-line imaging modality can aid in reducing diagnostic delays and thereby potentially improve patient outcomes[6–8]. Still, there are a limited number of studies that explicitly examine the utility of bedside abdominal ultrasounds with regard to adult intussusception outcomes. Of the few studies available in the literature, the majority were retrospective analyses and report an accuracy ranging from 60 – 85% for ultrasound-detected adult intussusception.[9-11] One particular multicentre retrospective analysis reported that abdominal ultrasound was able to correctly localise adult intussusception in 95% of cases and accurately detect complications in 100% of cases.[11]

Albeit intussusception is a surgical condition and the patient in this case initially presented to the emergency department, this patient could have developed these symptoms while inpatient on the medicine service. When faced with acute changes in a patient's status, vitals, physical examination, and laboratory studies are appropriately first performed. However, as illustrated in the present case, the information from these sources was limited and POCUS was an excellent adjunct to expedite the appropriate care pathway. There is a growing body of literature describing the utility of POCUS in acute and internal medicine.[12] In particular, benefits of POCUS have been described in the domains of procedural guidance (*e.g.* thoracentesis and central venous catheterisation) and bedside diagnostic accuracy[13]. Growing data in both of these domains are driving POCUS to become standard or care due to the marked improvements in patient safety. A recent position piece from the Society of Hospital Medicine articulates additional incentives for further integrating POCUS into acute and internal medicine including: (1) the fact that the POCUS exam is often performed by the same physician that is generating the clinical questions and will subsequently be tasked with integrating findings into the patient's care; and (2) the POCUS exam can be performed serially to assess responses to therapies or additional changes in clinical status.[14] Still, there remain hurdles to integrating POCUS in acute and internal medicine with the largest being gaps in physician POCUS training and curricula. Across the globe, medical institutions including the Society for Acute Medicine, the Royal College of Radiologists, and Harvard Medical School have begun to publish POCUS curricula for various levels of training in an effort to address these gaps.[15,16]

Ultimately, further research will be necessary to formally characterise the efficacy of abdominal ultrasound in adult intussusception diagnosis and prognosis. Sustained efforts will be equally critical to and define and implement the role for POCUS in acute medical care.

Declaration of Competing Interests

Nothing to declare.

© 2020 Rila Publications Ltd.

References

1. Anderson DR. The pseudokidney sign. *Radiology*. 1999 May;**211(2)**:395-7.
2. Marinis A, Yiallourou A, Samanides L, Dafnios N, Anastasopoulos G, Vassiliou I, Theodosopoulos T. Intussusception of the bowel in adults: a review. *World journal of gastroenterology: WJG*. 2009 Jan 28;**15(4)**:407.
3. Lu T, Chng YM. Adult intussusception. *The Permanente Journal*. 2015;**19(1)**:79.
4. Azar T, Berger DL. Adult intussusception. *Annals of surgery*. 1997 Aug;**226(2)**:134.
5. Yalamarthi S, Smith RC. Adult intussusception: case reports and review of literature. *Postgraduate Medical Journal*. 2005 Mar 1;**81(953)**:174-7.
6. Shyy W, Knight RS, Teismann NA. Ultrasound diagnosis of adult intussusception. *Journal of Emergency Medicine*. 2015 Oct 1;**49(4)**:498-9.
7. Eze VN. Idiopathic intussusception in an adult—an imageguided diagnosis. *BJR | case reports*. 2016 May 5:20150508.
8. van Dijk LJ, Noordman BJ, Scheepers JJ, Hartholt KA. A young woman with a jejuno-jejunal intussusception. *Case Reports*. 2015 Nov 25;2015:bcr2015212135.
9. Eisen LK, Cunningham JD, Aufses Jr AH. Intussusception in adults: institutional review. *Journal of the American College of Surgeons*. 1999 Apr 1;**188(4)**:390-5.
10. Wang N, Cui XY, Liu Y, Long J, Xu YH, Guo RX, Guo KJ. Adult intussusception: a retrospective review of 41 cases. *World journal of gastroenterology: WJG*. 2009 Jul 14;**15(26)**:3303.
11. Klinger C, Riecken B, Dietrich CF, Dirks K, Caca K, Fröhlich E. Use of Ultrasound in the Diagnostic Work-Up of Adult Intussusception–A Multicenter Retrospective Analysis. *Ultraschall in der Medizin-European Journal of Ultrasound*. 2018 Jul 5.
12. Blans MJ, Bosch FH. Ultrasound in acute internal medicine; time to set a European standard. *European journal of internal medicine*. 2017 Nov 1;**45**:51-3.
13. Watson K, Lam A, Arishenkoff S, Halman S, Gibson NE, Yu J, Myers K, Mintz M, Ma IW. Point of care ultrasound training for internal medicine: a Canadian multi-centre learner needs assessment study. *BMC medical education*. 2018 Dec;**18(1)**:217.
14. Soni NJ, Schnobrich D, Matthews BK, Tierny DM, Jensen TP, Dancel R, Cho J, Dversdal RK, Mints G, Bhagra A, Reierson K. Point-of-Care Ultrasound for Hospitalists: A Position Statement of the Society of Hospital Medicine. *Journal of hospital medicine*. 2019 Jan;**14**:E1-6.
15. Smallwood N, Dachsel M. Point-of-care ultrasound (POCUS): unnecessary gadgetry or evidence-based medicine?. *Clinical Medicine*. 2018 Jun 1;**18(3)**:219-24.
16. Rempell JS, Saldana F, DiSalvo D, Kumar N, Stone MB, Chan W, Luz J, Noble VE, Liteplo A, Kimberly H, Kohler MJ. Pilot point-of-care ultrasound curriculum at Harvard Medical School: early experience. *Western Journal of Emergency Medicine*. 2016 Nov;**17(6)**:734.

© 2020 Rila Publications Ltd.