Case Report

Pott's Puffy Tumour: a rare but sinister cause of facial swelling

S Birks & L Peart

Abstract

A 27 year old female presented to the emergency department with intermittent central forehead swelling over several months associated with a headache. She was admitted under the medical team as having had a suspected allergic reaction but the diagnosis of a Pott's Puffy Tumour was quickly made and confirmed through CT and MR imaging. This uncommon condition is related to sinusitis leading to localised abscess formation with osteomyelitis and a subsequent swollen appearance over the affected facial sinus.

This patient's sinus abscess extended into the epidural space and caused destruction of the anterior and posterior walls of the frontal sinus. The patient was managed with intravenous antibiotics, analgesia and referral to the local ENT team for surgical intervention.

Keywords

Pott's Puffy Tumour, Rhinosinusitis, Sinusitis, Allergy, Angioedema

Key Points

- Pott's Puffy Tumour is a rare clinical entity with dangerous complications.
- Allergic reactions and angioedema are more common but the associated swelling is not often well localised or tender.
- Consider sinus involvement in painful facial swelling over the facial sinuses with inflammatory features.
- Consider CT or MR imaging in cases of suspected sinusitis associated with facial swelling.
- Antibiotic therapy and prompt referral to specialist surgical teams are necessary for this condition.

Presentation

A 27 year old female presented to her local emergency department (ED) with a painful swelling to her central forehead. She reported that the swelling had first appeared several months ago and after a telephone consultation (without video-capabilities) with her general practitioner (GP), she was managed with oral Co-Amoxiclav in the community. This partially relieved her symptoms. The swelling returned approximately a month later and was again managed with the same oral antibiotic. She was not seen in her GP's surgery due to the coronavirus outbreak and subsequent reduction in face-to-face consultations.

On the third occasion, the swelling returned causing the patient to feel unwell and to experience more severe pain at the front of her head, prompting her visit to the ED. Blood tests taken on arrival demonstrated raised inflammatory markers (Table 1). She was tachycardic and pyrexial on initial assessment and the ED clinician also noted some swelling around the eyes bilaterally. The patient did not have a rash, wheeze, stridor or any suggestion of airway compromise but an allergic reaction was considered given the facial swelling so intravenous Hydrocortisone and Chlorphenamine were administered. As the patient had abnormal vital signs and the working diagnosis was a severe allergic reaction, she was referred to the medical team. The ED clinician also considered that the swelling may be a large forehead skin abscess so intravenous Co-Amoxiclav was also administered prior to referral.

The patient was a current smoker with no other medical conditions. In addition to the localised swelling, she reported clear rhinorrhoea but no history of any facial or head trauma. There was no history of recent allergen or occupational particulate exposure and she did not keep any pets. There was no evidence of a rash on examination. Additionally, there were no features of coronavirus infection and

Samuel Birks
MBBS, MSc, BSc(hons), FHEA
Core Training Doctor in Emergency Medicine
Sheffield Teaching Hospitals NHS Trust

Lucy Peart
MB ChB, MSc, BSc(hons), MRCP (Acute Medicine)
Consultant in Acute Medicine
Doncaster and Bassetlaw Teaching Hospitals NHS Trust

Correspondence
Samuel Birks
EMAD Corridor,
Northern General Hospital,
Herries Road,
Sheffield
S5 7AU
United Kingdom
Email: samuel.birks1@NHS.net

Table 1. Initial blood test results.

Blood Test	Result	Units	Reference Range
Haemoglobin	125	g/L	115 - 160
White Cell Count	18.2	x 10^9/L	4.0 – 12.0
Neutrophil Count	15.0	x 10^9/L	2.0 – 7.5
C-Reactive Protein	125.8	mg/L	0 - 5

© 2021 Rila Publications Ltd.



Figure 1. Axial CT image demonstrating a frontal bone abscess with destruction of the anterior and posterior walls of the frontal sinus.

the result of her viral swab for SARS-CoV-2 was negative.

The swelling to the forehead was circular, approximately 6 cm in diameter and 0.5 - 1 cm in height. It was localised to the central forehead with no associated erythema. On palpation, it was fluctuant and exquisitely tender.

The patient's cranial nerves and neurological system were functioning normally on examination and she did not display any photophobia or neck stiffness. Eye movements and pupillary reactions were unaffected but there was mild oedema evident to the lower eyelids bilaterally.

Given the anatomical location and extent of the swelling, the admitting medical doctor recognised the potential of sinus involvement and possibility of an abscess or frontal bone osteomyelitis. The possibility of a Pott's Puffy Tumour (PPT) was suggested on initial assessment. Intravenous Co-Amoxiclav was continued in line with advice from a microbiologist and computed-tomography (CT) imaging was requested (Figure 1).

Imaging & Investigations

The CT scan of the head confirmed the diagnosis and demonstrated frontal sinusitis with bony destruction of the anterior and posterior walls of the frontal sinus. Magnetic resonance imaging (MRI) corroborated this and demonstrated that a 2 x 2 x 3 cm abscess had formed and was extending from the scalp anteriorly, into the epidural space posteriorly (Figures 2 & 3). The maxillary and ethmoidal sinuses were also inflamed. Fortunately, brain parenchyma was unaffected.

Management

The patient was promptly referred to the Ear, Nose and Throat (ENT) team and her case was discussed with the neurosurgical team. Frontal sinus trephination was performed shortly after, with drainage of the abscess. The histopathology results of the sampled tissue showed inflammatory and granulatory tissue only with no evidence of malignancy. Microbiology results from a sample of the pus drained from the abscess revealed skin commensal bacteria only. The patient had an uneventful recovery from surgery and was discharged home on a six-week course of intravenous Co-Amoxiclav administered by an outpatient intravenous antibiotic service.

Discussion

Allergic reactions are a common presentation to the emergency department, comprising of between 0.4%[1] and 1%[2] of all presentations. The presence of facial swelling, in particular, can be of greater concern. This may cause the clinician to suspect more serious conditions such as angioedema and anaphylaxis which may prompt immediate treatment and referral to the inpatient medical teams.

Angioedema is characterised by swelling of subcutaneous tissues and classically affects the eyelids. Most often it is related to a reaction to an allergen or drug, but in the case of hereditary angioedema, it can also be triggered by exercise, trauma, stress and alcohol.[3] The swelling is often uncomfortable, but not tender, and may take up to 72 hours to fully resolve.[3,4] Treatment of allergic reactions and angioedema are similar and exist on a spectrum determined by severity of the illness given their common pathophysiology. Management of an allergy may simply require avoidance of the trigger and perhaps an oral antihistamine but treatment of angioedema in the acute setting also includes intravenous or intramuscular Hydrocortisone and Chlorphenamine.[4] Outside of the acute setting, management of angioedema includes prolonged (up to six weeks) treatment with a non-sedating antihistamine with or without a short course (five to seven days) of oral steroid, depending on the severity. A review of the patient's response to the treatment is advised, with onward referral to a dermatologist or immunologist in cases where the trigger is not identified or if there is a suspicion of hereditary angioedema.[4]

© 2021 Rila Publications Ltd.

Pott's Puffy Tumour: a rare but sinister cause of facial swelling

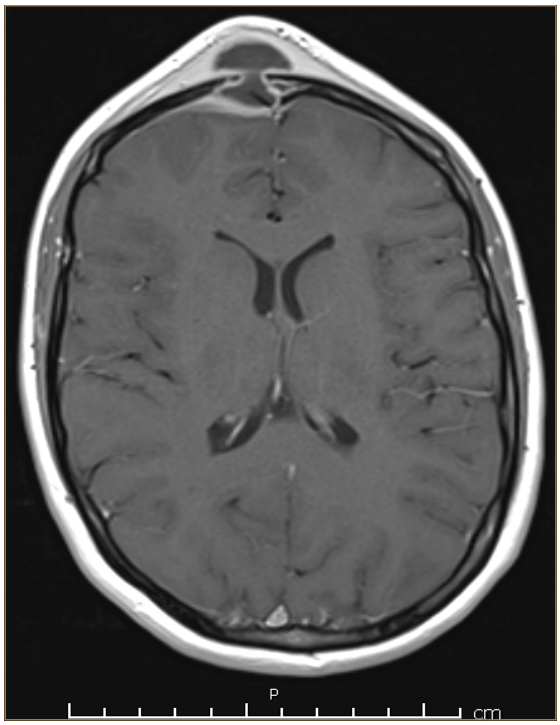

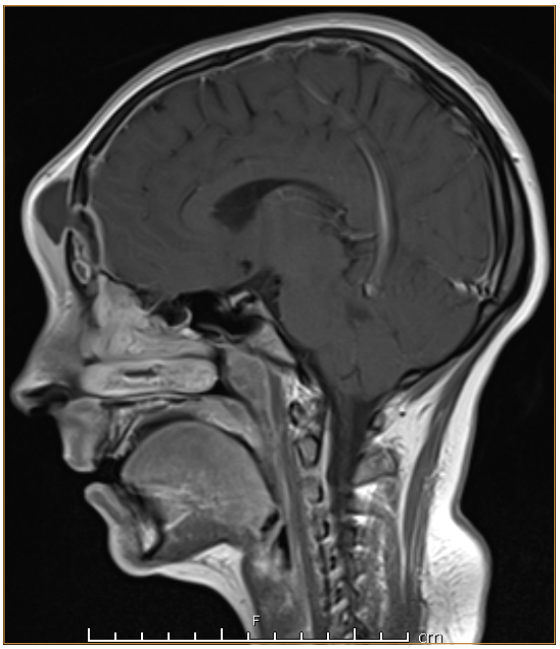

Figure 2 & 3. Axial and Sagittal MRI images demonstrating destruction of the bone surrounding the frontal sinus with a 2 x 2 x 3 cm abscess extending into the brain.

Acute rhinosinusitis is also common, affecting 6-15% of adults[5] and is the cause of 1-2% of all patient visits to general practitioners.[6] It is most often precipitated by an upper respiratory tract infection; the vast majority of which are viral. Bacterial causes only account for approximately 1 in 50 cases so antibiotic therapy is not routinely indicated.[7] The timeframe of acute sinusitis is defined by complete resolution of symptoms within 12 weeks of onset[8] but most cases resolve spontaneously in two to three weeks.[7] In cases that persist without improvement beyond 10 days, a nasal corticosteroid may help with symptoms but is unlikely to affect the duration of the illness[7].

Pott's Puffy Tumour (PPT) is a rare non-neoplastic complication of frontal sinusitis leading to formation of a subperiosteal abscess in the frontal bone. It was first described by Sir Percivall Pott in 1768 and its name is derived from the soft, spongy appearance of a swelling overlying the sinus.[9] The infection can cause localised destruction of the frontal bone and subsequent spreading of the abscess intracranially, potentially leading to epidural or cerebral abscesses, and meningitis.[10] The most common causative organisms include Streptococcus sp., Staphyloccocus sp. and Haemophilus Influenzae.[10] In modern medicine, the imaging modality most often used to make the diagnosis is CT, with MRI being helpful to further assess for complications and the extent of spread.[11] Given the rarity of this illness and unusual clinical presentation, it is understandable why it may be misdiagnosed. Early appropriate imaging and empirical antimicrobial therapy is therefore recommended in situations of diagnostic uncertainty such as this one.

According to current UK guidance for the management of acute sinusitis in the community, the presence of swelling over the frontal bone in this patient should have prompted immediate referral to hospital due to the risk of intracranial complications[7]. The patient's GP in this case, however, did not visualise her swelling due to the reduction in face-to-face consultations being performed at her general practice. This was because of the 2020 Coronavirus pandemic and subsequent measures to reduce spread of the virus. The 'blind' prescription of oral Co-Amoxiclav, however, may have been at least partly beneficial in managing the underlying pathology. Unfortunately though, the partial treatment of her symptoms meant that the patient did not represent until the pathology had progressed to the point that it required emergency surgical input.

The alterations in community assessment of patients' medical complaints because of the coronavirus pandemic may have a knock-on effect on the acute medical teams. Medical admitting physicians may find they are managing conditions that have not yet been visually assessed in the community before referral. This could lead to an increased secondary care workload and patient length of stay due to more advanced disease processes on admission, or conditions presenting to medicine that are usually managed by other specialties. Patients may also attend with more minor complaints usually managed

© 2021 Rila Publications Ltd.

in the community, for reassurance of a face to face consultation.

Due to the dangerous nature of the complications of a PPT, early diagnosis and management is imperative.[12] Fortunately, in this case, this was achieved swiftly after assessment by the admitting medical team.

Ethical Approval

Ethical approval was not required for this report. Patient consent was obtained prior to submission.

Declaration of Conflict of Interest

The authors declare that there is no conflict of interest.

References

1. Noble R, Friedlaender G, Cuthbertson B, *et al;* Acute Allergy and Anaphylaxis in the Emergency Department–a Review of 1 Year's Patient Presentations. *Emerg Med J*. 2013; **30(10)**: 874–874.
2. Kelly M, Donnelly JP, McAnnally J-R, *et al;* National estimates of emergency department visits for angioedema and allergic reactions in the United States. *Allergy and Asthma Proceedings*. 2013; **34(2)**: 150–4.
3. Ngan V; Angioedema [Internet]. DermNet NZ; 2006 [cited 2020 Aug 2]. Available from: https://dermnetnz.org/topics/angioedema/
4. The National Institute for Health and Care Excellence; Angio-oedema and anaphylaxis - NICE CKS [Internet]. 2018 [cited 2020 Sep 4]. Available from https://cks.nice.org.uk/topics/angio-oedema-anaphylaxis/
5. Bird J, Biggs TC, Thomas M, *et al;* Adult acute rhinosinusitis. BMJ [Internet]. 2013 [cited 2020 Aug 2]. Available from: https://www.bmj.com/content/346/bmj.f2687
6. Foden N, Burgess C, Shepherd K, *et al;* A guide to the management of acute rhinosinusitis in primary care management strategy based on best evidence and recent European guidelines. *Br J Gen Pract*. 2013; **63(616)**: 611–3.
7. The National Institute for Health and Care Excellence; Sinusitis - NICE CKS [Internet]. 2018 [cited 2020 Aug 2]. Available from: https://cks.nice.org.uk/sinusitis#!scenario
8. Royal College of Surgeons of England; Commissioning Guide: Chronic Rhinosinusitis [Internet]. 2016 [cited 2020 Aug 2]. Available from: https://www.rcseng.ac.uk/-/media/files/rcs/standards-and-research/commissioning/rhinosinusitis-commissioning-guide-for-republication.pdf
9. Tattersall R, Tattersall R; Pott's puffy tumour. *The Lancet*. 2002; **359(9311)**: 1060–3.
10. Rasuli B, Gaillard F; Pott puffy tumour [Internet]. Radiopaedia; [date unknown] [cited 2020 Aug 2]. Available from: https://radiopaedia.org/articles/pott-puffy-tumour?lang=gb
11. Sharma P, Sharma S, Gupta, N, *et al;* Pott Puffy Tumor. *Baylor University Medical Center Proceedings*. 2017; **30(2)**: 179-181.
12. Ketenci I, Unlü Y, Tucer B, *et al;* The Pott's puffy tumor: a dangerous sign for intracranial complications. *Eur Arch Otorhinolaryngol*. 2011; **268(12)**: 1755–63.

© 2021 Rila Publications Ltd.