Case Reports

Cerebral Nocardiosis in a patient with Waldenstrom's Macroglobulinaemia

P Tapley, T G Cranfield & G K Simon

Learning Points
- Always consider unusual infections in the differential diagnosis of a cerebral ring enhancing lesion in an immunosuppressed patient.
- Early tissue diagnosis should be considered even in elderly patients to enable appropriate therapy to be instigated.

Abstract
Nocardiosis is caused by nocardia species, a Gram positive aerobic filamentous bacillus. It is ubiquitous in the environment and often presents as pulmonary disease in more than 70% of patients.[1] Dissemination of the disease may manifest as brain abscesses, and is reported to account for approximately 2% of all brain abscesses.[2,3]

We present a case of cerebral nocardiosis in a patient with Waldenstrom's macroglobulinaemia, previously unreported in the literature.

Keywords
Nocardia, Waldenstrom's macroglobulinaemia, cerebral abscess

Dr Patrick Tapley
BM; ST1 Core Medical Training, Wessex Deanery, Queen Alexandra Hospital, Portsmouth, United Kingdom

Dr Tanya G
Cranfield MBBS FRCP FRCPath; Consultant Haematologist, Queen Alexandra Hospital, Portsmouth, United Kingdom

Dr Godwin K Simon
MBBS MD MRCP; Specialist Registrar Diabetes and Endocrinology, Wessex Deanery, Queen Alexandra Hospital, Portsmouth, United Kingdom

Correspondence:
Dr Patrick Tapley
Flat 1 York House
Queen Alexandra Hospital
Cosham Portsmouth
PO6 3LY
Tel: 07813988385
Email: patrick.tapley@porthosp.nhs.uk/paddytap@hotmail.com

Case Report
A 90 year old gentleman with Waldenstrom's macroglobulinaemia presented with altered sensation and distal weakness in his left arm, with grade 4 muscle power distally, following a witnessed grand-mal seizure.

He had been diagnosed with Waldenstrom's macroglobulinaemia 12 years earlier, following treatment for beta haemolytic Streptococcus septicaemia. Investigations at that time revealed an IgM kappa para protein with immune paresis, although he had remained asymptomatic, with no B symptoms. As a result of this he underwent regular review in the haematology outpatient clinic, with regular full blood count and paraprotein level monitoring. On two separate occasions he required chemotherapy treatment with fludarabine 70mg for a low haemoglobin and high paraprotein level, firstly in July 1997, and secondly in November 2005. This was successful, and in between and after these dates his paraprotein level remained stable at 11–12g/dL.

He had been admitted to hospital two weeks earlier with pneumonia, from which he had made a good improvement following antibiotic therapy. Urinary antigen testing had revealed *Legionella pneumophila* infection, and he improved clinically following a one week course of antibiotics. Prior to that he had been admitted to hospital only once, 12years earlier with pneumonia, which had led to the diagnosis of his Waldenstroms macroglobulinaemia. He was otherwise a very fit an independently mobile gentleman, and was active around the house and garden.

On examination there were no abnormalities of his cardiovascular, respiratory and abdominal systems. On neurological examination he was found to have an increased tone in all four limbs, with grade 4 power throughout his left arm, with normal sensation throughout. His cranial nerve examination revealed no abnormality with no papilloedema noted on fundoscopy.

His blood tests revealed a normocytic anaemia with a haemoglobin of 8.7g/dL, a white cell count of 13.3×10^9/L (neutrophil leucocytosis of 12.5×10^9/L), and a C-reactive protein of 84mg/L. His albumin on admission was noted to be 20, with normal renal function tests. His admission chest radiograph showed patchy shadowing predominantly involving the right mid and lower zones, which was showing improvement from the appearances at the time of his recent admission with pneumonia.

In view of the neurological symptoms and signs, he underwent a contrast enhanced computerized tomography (CT) brain scan. This showed a 1.8 × 1.6cm ring enhancing lesion in the right temporal lobe (see Figure 1). On microbiological advice he was started on intravenous meropenem, 1g three times a day in light of his raised inflammatory markers and the possibility of a cerebral abscess. A subsequent gadolinium enhanced magnetic resonance imaging (MRI) showed left temporal and frontal lesions, in addition to the right sided lesion. The MRI appearances of the lesion were suggestive of an abscess, rather than a cerebral metastasis. In view of his co-existent immune paresis and the possibility of unusual opportunistic infections being implicated it was deemed appropriate to arrange an Image Guided System (IGS™) brain

© 2008 Rila Publications Ltd.

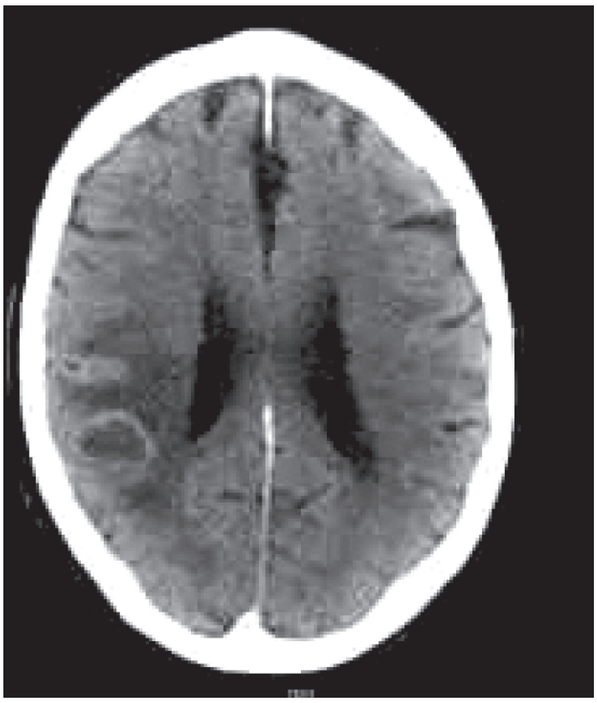

Figure 1. CT brain scan showing right temporal lobe ring enhancing lesions



Figure 2. Further left sided temporal lobe abscess.

biopsy. Pus was aspirated from the lesion and was sent for culture.

Five days post biopsy, and whilst still awaiting identification of an organism from the aspirated pus he had two episodes of focal right arm seizures, both witnessed and lasting less than one minute. He was commenced on a loading dose of intravenous phenytoin, followed by a regular once daily dose.

The following day *Nocardia cyriacigeorgica* was isolated from the aspirated pus, and on microbiological advice his antibiotics were changed to a combination of intravenous Amikacin 825mg 36hourly and Cefotaxime 2gram 4hourly, with the plan being for two weeks therapy, followed by oral co-trimoxazole (trimethoprim and sulfamethoxazole) 960mg four times a day, with a plan for a year's therapy. A further CT brain scan undertaken after the commencement of oral antibiotic treatment showed the initial lesions to be of a stable size; however a further lesion had developed on the left (Figure 2). Following further discussion with the microbiology team, he was changed back to intravenous meropenem 1g three times a day.

A further scan after three weeks of this treatment showed some improvement in the size of the lesions and no new lesions, while CT scan of his chest and abdomen revealed no other sites of involvement. Clinically his left arm weakness was slowly improving, hence it was felt that he would benefit from a period of rehabilitation, and was transferred to one of the rehabilitation wards. A further interval CT scan showed improvement in the size of the abscesses, and in view of this his antibiotic therapy was changed to oral Trimethoprim and sulfamethoxazole (co-trimoxazole) with the plan for a total of one year's therapy. He slowly regained the strength in his left arm and his independence, and was sent home. In total he was in hospital for three months. An outpatient CT brain undertaken 8 months after his original presentation showed that all of the abscesses had completely resolved. He was fully independent at home for a further five months before he was readmitted with a severe community acquired pneumonia, from which he died in hospital.

Discussion

On review of the literature, this is the first case of which we are aware demonstrating an association between Waldenstrom's macroglobulinaemia and cerebral abscess due to *nocardia*. Our patient had previously been treated with Fludarabine, a chemotherapeutic agent. This is known to cause T cell immune paresis, resulting in opportunistic infection.[4]

Clinical and radiological features of cerebral *nocardia* infections commonly mimic other pathologies, for example malignancy, or cerebral infarction.[3, 5–7] Both of these conditions would be much more commonly encountered, particularly in a patient of this age. A biopsy of the affected area is often required to make a firm diagnosis of opportunistic infections, as most are rarely grown in blood cultures. Most cases of cerebral n*ocardia* infection have been identified from biopsy material.[3,8,9] Some clinicians might consider brain biopsy to be an inappropriate investigation for a patient of 90 years. However, early brain biopsy in this case enabled appropriate antimicrobial therapy to be instigated early in the course of the disease, resulting in significant symptomatic improvement, and allowing the patient to be discharged home back to his previous level of functioning.

Antimicrobial therapy is the mainstay of treatment following identification of the organism. In our patient, there was a requirement for multiple courses of intravenous meropenem, due to recurrence of disease whilst on oral

© 2008 Rila Publications Ltd.

co-trimoxazole. It appears widely accepted that this treatment regimen of intravenous meropenem followed by maintenance co-trimoxazole is the best for treating cerebral abscesses due to *Nocardia* species, and often for prolonged periods.[3,8,9] Initially in our case the patient was changed from meropenem to a combination of amikacin and cefotaxime as it was felt that the meropenem was lowering his seizure threshold. Reinstigation of the meropenem following deterioration of the radiological appearances did not result in further seizure.

Due to the rarity of brain abscess due to *nocardia*, there is little literature on the most appropriate form of treatment. Treatment options include tissue diagnosis followed by antibiotics, aspiration of the abscess followed by antibiotics, or enucleation followed by antibiotics.[8] Most reports in the literature involve either single patients, or small case series. The largest case series identified eleven patients, who presented over the course of thirty one years.[10] The conclusions from three of the case series [10–12] were that a more aggressive surgical intervention, either by complete neurosurgical enucleation,[11] or aspiration for tissue diagnosis,[10] may be more effective than more conservative management strategies.[10–12]

The diagnosis of rarer infections, especially in the immuno-compromised patient, as opposed to pyogenic abscess due to common organisms or malignancy, should always be considered when presented with a case of a ring enhancing lesion. An aggressive approach of early tissue diagnosis and the early commencement of appropriate treatment,[3,12] reduces the associated high mortality rate,[2,3] which has been reported to be three times higher than that of other bacterial brain abscesses.[2,7]

References

1. Braga M, Beretta S, Farina C, *et al*; Medical treatment for nocardial brain abscesses case report. *J Neurol.* 2005; **252**: 1120–1121.
2. Shin JH, Lee HK; Nocardial brain abscess in a renal transplant recipient. *Clin Imaging*. 2003; **27**: 321–324.
3. Kennedy KJ, Chung KH, Bowden FJ, *et al*; A cluster of nocardial brain abscesses. *Surg Neurol.* 2007; **68**: 43–49.
4. Chen CI; Treatment for Waldenstrom's macroglobulinaemia. *Ann Oncol.* 2004; **15**: 550.
5. Menku A, Kurtsoy A, Tucer B, *et al*; Nocardia brain abscess mimicking tumour in immunocompetent patients: report of two cases and review of the literature. *Acta Neurochir (Wien).* 2004; **146**: 411–414.
6. Borm W, Gleixner M; Nocardia brain abscess misinterpreted as cerebral infarction. *J Clin Neurosci*. 2003; **10**: 130–132.
7. Mogilner A, Jallo GI, Zagzag D, *et al*; Nocardia abscess of the choroid plexus: clinical and pathological case report. *Neurosurgery*. 1998; **43**: 949–952.
8. Kilincer C, Hamamcioglu MK, Simsek O. *et al*; Nocardial brain abscess: review of clinical management. *J Clin Neurosci.* 2006; **13**: 481–485.
9. Yoneyama T, Yamakimi I, Mine S, *et al*; Nocardial brain abscess: surgery and postoperative antibiotic therapy. *No Shinkei Geka.* 2004**; 32**: 457–462.
10. Lee GY, Daniel RT, Brophy BP, *et al*; Surgical treatment of nocardial brain abscesses. *Neurosurgery*. 2002; **51**: 668–671.
11. Valarezo J, Cohen JE, Valarezo L, *et al*; Nocardial cerebral abscess: report of three cases and review of the current neurosurgical management. *Neurol Res.* 2003; **25**: 27–30.
12. Fleetwood IG, Embil JM, Ross IB; Nocardia asteroids cerebral abscess in immunocompetent hosts: report of three cases and review of surgical recommendations. *Surg Neurol.* 2000; **53**: 605–610.

© 2008 Rila Publications Ltd.

Acute Medicine_V7_N3.indd 130 10/03/2009 14:08:17