Acute Med V9 N1:Acute Med V9 N1.qxd 22/02/2010 18:09 Page 15

Case Report

Septic Pulmonary Embolism in an Intravenous Drug User

S Hoye, D Tolan & A Brownjohn

Key points:
- Intravenous drug users present significant diagnostic and management challenges on the acute medical unit, due to the high incidence of self discharge and the effects of drug withdrawal.
- Always consider septic pulmonary embolism in the differential diagnosis when an intravenous drug user presents with features of infection of uncertain origin.

Abstract
A recent case of septic pulmonary embolism in an intravenous drug user, complicated by issues of recurrent self discharge and delays in diagnosis yields opportunity to increase awareness of this uncommon yet life-threatening disorder. The literature is reviewed and includes suggested aids to raise clinical suspicion and improve subsequent management.

Keywords
Intravenous drug user, septic pulmonary embolism, management, self discharge

Case Report
A thirty five year old intravenous drug user (IVDU) repeatedly attended acute medical services over a two month period. He claimed to administer £200 worth of heroin per day by femoral vein injection, with occasional crack cocaine use.

He initially presented with a short history of productive cough and green phlegm, fever and severe pleuritic chest pain. Initial clinical signs included evidence of dehydration, pyrexia at 38.8°C, hypoxia on 15litres (PaO_2 12kPa) but no hypotension. There was a systolic murmur but no peripheral stigmata of endocarditis. Air entry was reduced at the right lung base. There were no signs of peripheral deep venous thrombosis (DVT). Investigations results (summarised Table 1 – Admission 1) included negative blood cultures. Chest x-ray (CXR) revealed extensive right lower lobe consolidation with associated pleural effusion (see Figure 1).

The patient was prescribed intravenous (IV) Co-Amoxiclav 1.2g three times daily (TDS) and Clarithromycin 500mg twice daily (BD). Ultrasound guided aspiration to dryness of two loculated fluid pockets provided an exudative pleural fluid, containing polymorphs and Streptococcus milleri on culture, consistent with empyema and sensitive to the prescribed antibiotics. Unfortunately, the patient self discharged on day two without a prescription for further treatment.

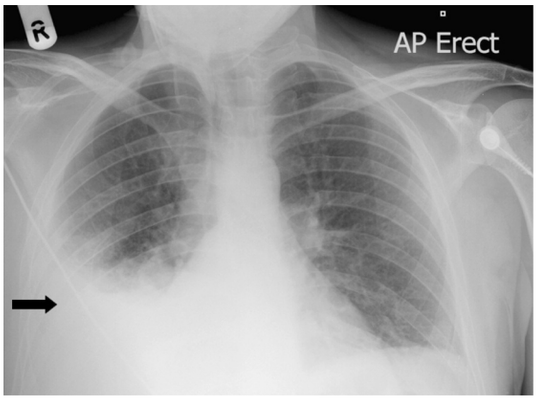

Figure 1. Chest xray showing right lower lobe consolidation and pleural effusion (arrow).

The patient was readmitted thirteen days later directly to the High Dependency Unit (HDU) with profound sepsis and vomiting with hypotension (80/60mmHg), tachycardia (165 beats/min), pyrexia at 40°C and respiratory compromise with respiratory rate at 30/min and oxygen saturation 94% on air. He was commenced on IV Tazocin 4.5g TDS and Clarithromycin 500mg BD due to positive *mycoplasma* serology (other blood results are summarised in Table 1, Admission 2). Fluid resuscitation was guided by central venous pressure (CVP) monitoring and circulatory compromise improved without inotropic support. Examination of groin sites revealed a right inguinal chronic sinus and recent use of the left femoral vein for intravenous injection. Further CXR showed considerable improvement in the right basal consolidation, but a pleurally based density was

Sarah Hoye
Speciality Registrar in Acute Medicine
St James's University Hospital, Beckett Street, Leeds LS9 7TF

Damian Tolan
Consultant Radiologist, Department of Clinical Radiology, Leeds General Infirmary, Leeds, LS1 3EX

Aleck Brownjohn
Consultant Physician in Renal and General Medicine
Leeds General Infirmary, Leeds, LS1 3EX

Correspondence:
Sarah Hoye
18 Coldwells Hill, Stainland, Halifax, HX4 9PG
Email: sarahhoye@hotmail .com

© 2010 Rila Publications Ltd.

Acute Med V9 N1:Acute Med V9 N1.qxd 22/02/2010 18:09 Page 16

Septic Pulmonary Embolism in an Intravenous Drug User

	Admission (duration)		
	1 (2 days)	2 (3 days)	3 (14 days)
Hb (g/dL) [MCV, fL]	13.1 [87]	**7.3** [81]	**5.5 [79]**
Platelets (x109/L)	500	419	**734**
WCC (x109/L)	**22.8** (91% neutrophils)	19.9	14
Na (mmol/L)	**132**	140	124
Other U&E	Normal	Normal	Normal
LFT: Bili & ALT	Normal	Normal	Normal
Alk P (iu/L)	205	313	**649**
Albumin (g/dL)	45	30	**22**
CRP (mg/L)	**358**	256	157

Table 1. Investigations.

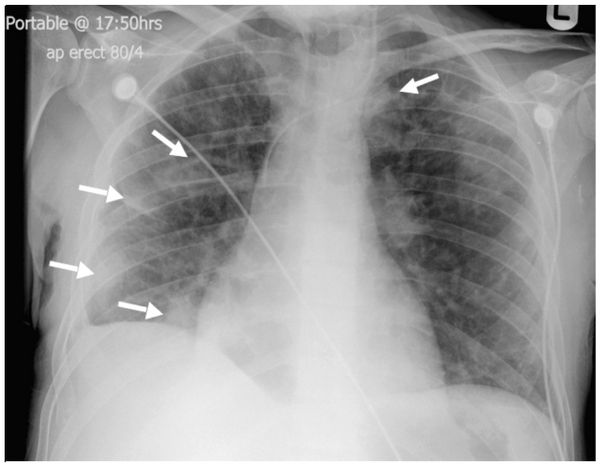

Figure 2. Chest x-ray taking on 3rd admission showing multiple opacities (arrows), reported as 'likely to be infective in origin'.

noted, consistent with encysted pleural effusion or empyema.

Unfortunately he absconded again within 72 hours of admission despite attempts to prevent self discharge, including thorough explanation of his current health problems, Dihydrocodeine prescription to prevent opiate withdrawal and community drug team referral to facilitate future establishment on Methadone.

A fortnight later he was re-admitted to the Acute Medical Unit with deteriorating respiratory symptoms and leg swelling and was profoundly hypoxic (Arterial Blood Gas on air: PaO2 6.75kPa, PaCO2 4.34kPa, pH 7.519, HCO3 26.9). Multiple bilateral small opacities were noted on CXR (see Figure 2), reported as "likely to be infective in origin."

Blood results were consistent with severe chronic sepsis (Table 1 Admission 3) with the development of profound anaemia since his last admission. Cefuroxime 1.5g TDS IV was commenced along with low dose thromboprophylactic subcutaneous low molecular weight heparin (LMWH - Enoxaparin 40mg) in view of anaemia, and pending imaging confirmation of thromboembolism. Following a five unit packed red cell transfusion, he developed pulmonary oedema, and was transferred to HDU for CVP monitoring and IV diuretics. A, further six units of blood were required over the next ten days to maintain his haemoglobin level.

Bedside echocardiography provided limited views of the heart valves due to tachycardia and patient non-compliance, but showed preserved left ventricular systolic function and no vegetations. Pulmonary artery pressure could not be estimated. Transoesphageal Echocardiography (TOE) was not performed.

Emerging microbiology results (days two to four) revealed *Actinomyces, Streptococcus mitis* and *Prevotella* species in blood cultures from the central line, and IV Metronidazole 500mg TDS was added. On day seven, a second Actinomyces species grew suggesting deep seated infection. As clinical improvement was slow microbiology advised introduction of Benzyl penicillin. Groin swabs, line tips, HIV, Hepatitis B and C screening were all negative.

Doppler ultrasound diagnosed bilateral femoral DVT extending to iliac veins on day four (delayed by public holidays), with small collections in both groins at the injection sites. LMWH was increased from prophylactic to therapeutic dose. The latest CXR showed increasing patchy nodular consolidation throughout both lungs, compatible with septic emboli. CT Pulmonary Angiogram (CTPA) was performed, including the abdomen and pelvis, given concerns for possible occult abdominal sepsis in light of blood culture results (see Figure 3).

Multifocal areas of consolidation were present throughout the lungs including areas of cavitation as well as filling defects in pulmonary artery branches consistent with multiple pulmonary emboli (not shown). Although there were no intra-abdominal collections, bilateral femoral DVTs were present extending into the inferior vena cava to the level of the renal veins, containing air bubbles within it, consistent with septic emboli from infected thrombosis.

After stabilisation he was transferred from HDU to a medical ward where he received continued input from microbiology and the critical care outreach team. On day fourteen after admission the patient self discharged again, against medical advice following assessment of capacity by a junior member of the medical team.

© 2010 Rila Publications Ltd.

Acute Med V9 N1:Acute Med V9 N1.qxd 22/02/2010 18:09 Page 17

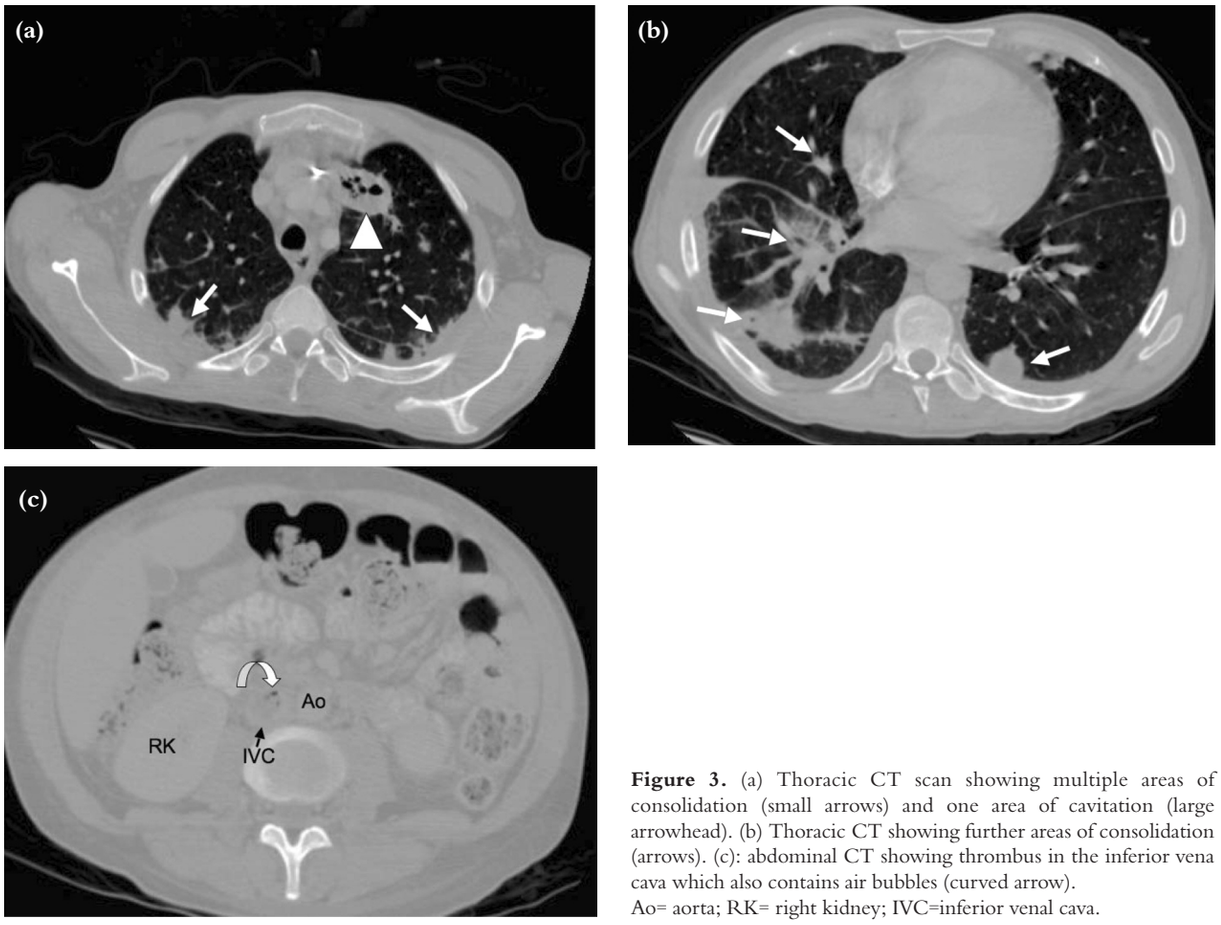

Figure 3. (a) Thoracic CT scan showing multiple areas of consolidation (small arrows) and one area of cavitation (large arrowhead). (b) Thoracic CT showing further areas of consolidation (arrows). (c): abdominal CT showing thrombus in the inferior vena cava which also contains air bubbles (curved arrow).
Ao= aorta; RK= right kidney; IVC=inferior venal cava.

The patient has not attended acute medical services in the hospital trust since this episode and his whereabouts are unknown. We can only speculate regarding his current state of health. Given the persistent undertreated deep seated infection and lack of anticoagulation he is at significant risk of sudden death or chronic, ongoing ill health.

Discussion

This case demonstrates the presentation of septic pulmonary embolism in an IVDU, a complication requiring high clinical suspicion to allow prompt diagnosis. It highlights areas where the optimal medical intervention was not received. Firstly, significant hindrances to diagnosis (see Box 1) and possible lack of doctor awareness may have contributed to investigation delays.

Infective endocarditis was not specifically documented as a differential, and although transthoracic echo was normal cardiology referral was not made and TOE was not performed, which is most sensitive to exclude valvular vegetations. Thromboembolism was initially considered a possible cause for ongoing tachycardia but disregarded early in admission three as attributed to opiate withdrawal. The potential implications of misdiagnosis were evident by subsequent initial prescribing of low dose rather than anticoagulation dose LMWH, and CT pulmonary angiography was not considered until day seven of the third admission. Secondly, as imaging for thromboembolic disease (Doppler ultrasound and CTPA) is usually performed 'in hours', there were delays in radiological investigation due to intervening public holidays and weekends, exacerbated by additional delays due to a temporarily broken CT scanner.

Furthermore, recurrent self-discharge rendered continuity of care impossible. With each admission episode, morbidity increased, with septic shock, multiple blood transfusions, repeated requirements for central line insertion (and associated risks) and potential exposure to nocosomial infection. The healthcare resources utilised were significant. It is unclear whether the likelihood of absconding was increased by possible under treatment of opiate withdrawal, leading to patient irritability and restlessness. Addiction services could have been consulted to aid prescription of appropriate Dihydrocodeine doses and instigation of Methadone. The assessment of mental capacity prior to self

Lack of clinical suspicion
Non-specific radiographic findings
Blood cultures may be initially negative
Heart murmur undetectable (right sided)
Echocardiography may be technically limited
Very small vegetations missed

Box 1. Possible causes for delay in SPE diagnosis.[5]

© 2010 Rila Publications Ltd.

Acute Med V9 N1:Acute Med V9 N1.qxd 22/02/2010 18:09 Page 18

discharge could perhaps have been made at a more senior level, as it may have been appropriate to treat under Common Law if he was deemed lack capacity due to delirium. Community antibiotic therapy and anticoagulation might have been offered at discharge to prevent further readmission, but ongoing issues with compliance and attendance are likely to have remained problematic, and would not have guaranteed a successful outcome.

Septic Pulmonary Embolism

Pathophysiology

Septic pulmonary embolism begins in chronic intravenous drug use, where superficial and peripheral veins are obliterated, forcing utilisation of proximal and more central veins for injection. Mechanical and toxic complications may occur, such as: haematoma and haemorrhage; traumatic arteriovenous fistula; intra-arterial drug injection; mycotic aneurysm; soft tissue abscesses and venous thrombosis, these last two predisposing to life-threatening septic DVT.[1] Bacterial embolisation from micro abscesses within the thrombosed vein may lead to severe systemic disease, including right sided endocarditis. The embolic clot that produces infarction in the pulmonary vasculature also contains microorganisms that incite focal abscess formation, so called, septic pulmonary embolism (SPE).

Diagnosis

SPE is an uncommon disorder with insidious onset and is difficult to diagnose. No definite criteria exist to aid diagnosis, but a combination of evolving pulmonary lesions in the context of persistent bacteraemia, potential embolic source and extra-pulmonary embolic manifestations, should lead to it being considered (see Table 2). Blood cultures should therefore be mandatory in every IVDU presenting with DVT and fever, particularly given the risk of infective endocarditis affecting right heart valves.

O'Donnell *et al* (1995) observed the pulmonary complications in IVDU. The risk of community acquired pneumonia was found to be tenfold normal incidence, with increased frequency of tuberculosis. Only one of the 105 cases had SPE, presumed to be due to greater awareness of needle hygiene and rare occurrence.[5]

Chest radiographs are helpful in assessment (see Table 2) but contrast enhanced thoracic CT scanning may yield more clues suggestive of SPE, such as the feeding vessel sign (a connection between a pulmonary artery and infected pulmonary nodule).[6] Iwasaki and colleagues (2001) found only 32% of lesions detected by CT were also seen on CXR.[7] In this case the combination of cavitating consolidation, pulmonary emboli and presence of gas within the IVC thrombus made SPE highly likely.

Treatment and Prognosis

With accurate early diagnosis, prompt antimicrobial therapy with □-lactamase-resistant penicillin[1] and appropriate anti-coagulation, the prognosis is favourable.

Presenting symptoms[2]	Fever (93%) Dyspnoea (36%) Pleuritic chest pain (29%)	Cough (14%) Haemoptysis (7%) Fatigue (29%)
Potential embolic sources of SPE[2]	IVDU with septic DVT Other focal extra pulmonary infection: Pelvic thrombophlebitis Suppurative processes in head & neck (dental abscesses) Indwelling foreign bodies - central venous catheters - pacemakers - prosthetic heart valves	
Microbiology – the bacteraemias[3]	Most common pathogen in blood cultures: *Staphylococcal* species (particularly *S. aureus*)	*Other isolates:* *Streptococcus A and C* *Streptococcus pyogenes* *Streptococcus milleri* *Peptostreptococcus* *S. epidermidis* *Prevotella* *Bacteroides*
CXR abnormalities[4]	Patchy infiltrates and/or multiple nodules - Often bilateral - Predominantly peripheral - Tendency for cavitation Pleural effusions unilateral or bilateral	

Table 2. What we know about Septic Pulmonary Embolism from the literature.

© 2010 Rila Publications Ltd.

Acute Med V9 N1:Acute Med V9 N1.qxd 22/02/2010 18:09 Page 19

General assessment		
Nutritional status	All febrile patients must have blood cultures	
Evidence of:	Injection sites should be reviewed	
- DVT and PE	Establish HIV and Hepatitis status	
- Cellulitis	Arrange appropriate screening	
- Abscesses	Follow local guidelines for opiate withdrawal	
- Heart murmur	Involve Addiction Services early	
- Lung symptoms or signs	Have a strict ward behaviour code	
Guidelines for Opiate Withdrawal Management[8]		
Withdrawal symptoms peak	32-36 hours after last heroin dose 4-6 days after methadone	
A clinical opiate withdrawal scale (COWS) can be used to assess withdrawal severity		
Symptoms	Sweating	Nausea/vomiting/diarrhoea
	Lacrimation/rhinorrhoea	Dilated pupils
	Yawning	Piloerection/gooseflesh skin
	Abdominal cramps	Tachycardia
	Generalised aches & pains	Hypertension
	Anxiety/restlessness/irritability	Tremor
In hospital use Dihydrocodeine to prevent opiate withdrawal		
Doses may need to be adjusted according to symptoms:		
History unreliable:	60mg QDS + 30mg PRN	
If patient uses £20-30/day heroin:	120mg QDS + 30mg PRN	
If patient uses £30+/day heroin	150mg QDS + 30mg PRN	
In severe cases, Dihydrocodeine may not be enough, methadone may be required		
Start at 10mg Methadone 1mg/ml oral solution PRN (4 hourly) to a maximum 40mg/24 hours, then calculate daily requirement.		
Liaise with Addiction Services for advice		

Table 3. Suggested policy for an IVDU admission.

Unfortunately, the referenced literature contains relatively few cases of intravenous drug users, reflecting difficulty in follow up of this population cohort.[2] In the majority of cases there is an extra-pulmonary focus of infection as the embolic source. It is likely that morbidity and mortality are significantly higher in an IVDU population with chaotic lifestyles, tendency to self-discharge, non compliance with medication and avoidance of medical intervention. Delays in diagnosis and incomplete treatment increase the likelihood of potential complications (see Box 2).

The median duration of symptoms prior to diagnosis of SPE is typically 18 days (range 5-180 days) and mean hospitalization for 72 hours.[2]

Endocarditis with heart valve replacement
Thoracostomy/surgical drainage and decortication for empyema/pleural effusion
Massive haemoptysis from septic infarctions requiring temporary mechanical ventilation
Overwhelming sepsis

Box 2. Sequelae of SPE.[4]

Medical staff must be aware of the possible extensive pathologies that IVDUs may hide particularly in the diagnosis of septic pulmonary embolism. It is therefore essential to have hospital policy specific to intravenous drug users, with suggested components as in Table 3.

1. Fah, F *et al*. Septic deep venous thrombosis in intravenous drug users Swiss *Med Wkly* 2002; **132**: 386–392.
2. Cook, RJ *et al*. Septic Pulmonary Embolism Presenting Features and Clinical Course of 14 Patients *Chest* 2005; **128**: 162–166.
3. Summanen *et al*. Comparison of the microbiology of soft tissue infections in IVDU and non-IVDU (160 abscesses sampled) Wound Microbiology and Associated Approaches to Wound Management 1995; 226 cmr.asm.org/cgi/content/full/14/2/244/T3.
4. Macmillan JC, Milstein SH, Samson PC. Clinical spectrum of septic pulmonary embolism and infarction. *J Thorac Cardiovasc Surg* 1978; **75**: 670–679.
5. O'Donnell, AE *et al*. Pulmonary complications associated with illicit drug use: an update. *Chest* 1995; **108**: 460–463.
6. Kuhlman, JE, Fishman EK, Teigan C. Pumonary Septic Emboli: *Diagnosis with CT Radiology* 1990; **174**: 211–213.
7. Iwasaki , Y *et al*. Spiral CT findings in septic pulmonary emboli. *European Journal of Radiology* 2001 Mar; **37(3)**: 190–4.
8. Available at: http://www.leedsteachinghospitals.com Symptomatic Management of Opiate Withdrawal Guidelines

© 2010 Rila Publications Ltd.