Case Report

Addison's Disease Presenting with Abdominal Pain

T Desai & T Richardson

Abstract

Primary Adrenal Insufficiency is due to bilateral destruction of the adrenal cortex and has a prevalence of approximately 40-60 per million adults.[1] The commonest cause is autoimmune.[1] Prompt treatment not only restores quality of life but also a normal life expectancy.[2] Here we present an unusual case of primary adrenal insufficiency, which illustrates how such an important disease often provides a diagnostic conundrum.

Keyword

Addison's Disease, hyponatraemia, gastro-intestinal symptoms

Teaching Points

- Addison's Disease can present with non-specific symptoms.
- Patients with Addison's disease may present to a variety of different specialities.
- Consider Addison's in patients presenting with weight loss, abdominal pain, nausea and vomiting, especially when combined with biochemical abnormalities.
- Early consideration of the diagnosis and appropriate investigation is crucial.
- Appropriate replacement therapy will usually result in rapid resolution of symptoms.

Case Report

A 22-year-old man presented to the emergency department with a five day history of right iliac fossa pain and shortness of breath. The pain was described as dull and of gradual onset, having increased in intensity over the previous 12 hours. On direct questioning he also described feeling dizzy on standing. There was no significant past medical history and the patient denied foreign travel or recent change in diet.

On examination, the patient was noted to have slurred speech with pinpoint pupils. The patient admitted to previous recreational drug use. Examination of the abdomen revealed rebound tenderness and guarding in the right iliac fossa with quiet bowel sounds. Examination of the cardiovascular, respiratory and neurological systems was normal, apart from a blood pressure of 95/55mmHg with an associated postural drop to 75/45mmHg.

Table 1 shows the patient's initial blood test results. ECG, chest X-ray and ultrasound of the renal tract were normal. The patient was referred to the surgical team with a diagnosis of suspected appendicitis. The biochemical abnormalities and postural hypotension were attributed to dehydration and recreational drug use.

The patient was resuscitated with intra-venous fluids, but remained non-specifically unwell. The medical team was consulted for a second opinion. The possibility of Addison's Disease was considered in view of the electrolyte abnormality. Further examination revealed pigmentation of the buccal mucosa and skin creases of both hands **(see Figure 1 and 2)**. There was no evidence of concomitant autoimmune disease.

Baseline serum cortisol at 9am was low at 35nmol/l (normal range 200-650 nmol/l); subsequent short synacthen test indicated a blunted response consistent with Addison's disease. Anti-adrenal antibodies were strongly positive, and serum ACTH level was raised at 263ng/l (normal range <40mg/l).

The patient was diagnosed with Addison's Disease and was started on hydrocortisone 25mg daily in divided doses and 100mcg daily of fludrocortisone. The patient was counselled on the use of steroids and the sick day rules. He was given a steroid card and a Medic-AlertTM bracelet. Within

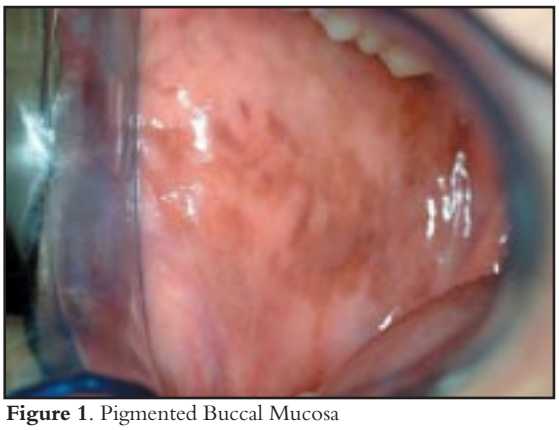

Figure 1. Pigmented Buccal Mucosa

Dr Tejal Desai
BSc MBBS
Senior House Officer,
Royal Bournemouth
Hospital, Dorset

Dr Tristan Richardson
BSc MBBS MRCP
Consultant in Diabetes and
Endocrinology
Royal Bournemouth
Hospital, Dorset

Correspondence:
Dr Tristan Richardson
Consultant in Diabetes and
Endocrinology
Royal Bournemouth
Hospital
Castle Lane East
Bournemouth
Dorset
tristan.richardson@rbch.nhs
.uk

Addison's Disease Presenting with Abdominal Pain



Figure 2. Pigmented Skin Creases

24 hours of starting steroid replacement, his abdominal pain and postural hypotension had resolved. Blood pressure on pre-discharge had increased to 110/75mmHg. The patient was discharged home 48 hours following initiation of steroids, symptom free.

Discussion

Primary Adrenal Insufficiency is due to bilateral destruction of the adrenal cortex and has a prevalence of approximately 40-60 per million adults[1]. The commonest cause is autoimmune adrenalitis[1] (Addison's disease). Prompt treatment of primary adrenal insufficiency rapidly resolves symptoms.[2] The common clinical manifestations are shown in **Table 2**[1].

We have presented an unusual, albeit well recognized, presentation of primary adrenal insufficiency to help illustrate the importance of considering this condition in patients presenting with abdominal pain. This patient was initially referred to the surgical team with symptoms and signs consistent with peritonism. Gastrointestinal symptoms are commonly seen in Addison's disease, but are frequently overlooked.[3]

The non-specific manifestations of the disease can often make it difficult to diagnose. Furthermore, 90% of the gland has to be destroyed before patients become symptomatic.[4] Although hyponatraemia and hyperkalaemia occur in 92% of patients with primary adrenal insufficiency, these abnormalities also commonly occur with other conditions[5], and therefore may be attributed to other pathological processes.

Initial investigation should include measurement of morning serum cortisol followed by a short Synacthen test[6]. These tests should be interpreted with caution in certain cases, for example in patients with co-existent sepsis, where a normal cortisol does not exclude hypoadrenalism.

Treatment involves oral replacement therapy with hydrocortisone and fludrocortisone. A starting daily regimen for hydrocortisone of 10mg morning and lunchtime and 5mg at night is recommended. Monitoring potassium and blood pressure helps to determine the dose of fludrocortisone, usually 50 – 100mcg per day.

		Normal Range
Sodium (mmol/l)	121	132 - 146
Potassium (mmol/l)	5.6	3.2 - 5.0
Urea (mmol/l)	13.2	2.5 – 6.7
Creatinine (µmol/l)	116	45 -110
Glucose (mmol/l)	4.3	<7.1
ALT (iu/l)	104	<35
ALP (iu/l)	70	30 – 100
Bilirubin (µmol/l)	33	<17
Amylase	59	<100
ESR (mm)	26	1 – 12

Table 1. Initial Blood Test Results

Fatigue, anorexia, depression
Postural hypotension
Nausea, abdominal cramps, diarrhoea
Hyponatraemia, hyperkalaemia, normocytic anaemia
Hyperpigmentation

Table 2. Common clinical manifestations of Addison's Disease

References

1. Oelkers, W; Adrenal Insufficiency. *NEJM* 1996; **335** (16): 1206-1212.
2. Smith JC, Siddique H & Corrall RJM; Misinterpretation of serum cortisol in a patient with hyponatraemia. *BMJ* 2004; **328**: 215-216.
3. Tobin MV, Aldridge SA, Morris AI, et al; Gastrointestinal Manifestations of Addison's Disease. *Am J Gastro* 1989; **84 (10):** 1302-1305.
4. Brosnan CM & Gowing NFC; Addison's Disease. *BMJ* 1996; **312**: 1085-1087.
5. Crook MA, Velauthar U, Moran L, et al; Review of investigation and management of severe hyponatraemia in a hospital population. *Ann Clin Biochem* 1999; **36**: 158-162.
6. Grinspoon SK & Biller BMK; Laboratory assessment of adrenal insufficiency. *J Clin Endocrinol Metab* 1994; **79**: 923-931.