Case Reports

An unusual pathogen in ambulatory care: two cases of Scedosporium soft tissue infections presenting as "unresponsive cellulitis"

GP Misselbrook, P Lillie & CP Thomas

Abstract

Soft tissue infections with Scedosporium spp. *are an uncommon but serious and emerging cause of infection in immunocompromised patients. Acute Medical Units (AMUs) in the UK are increasingly managing patients with cellulitis in an outpatient setting, therefore acute physicians should be aware of some of the more uncommon causes of soft tissue infection, particularly in patients not responding to initial antibiotic therapy. We present two cases of Scedosporium presenting to the AMU as cellulitis not responding to initial antibiotic therapy and outline the assessment and management of this important condition.*

Keywords

Cellulitis, Scedosporium, IV OPAT, Opportunistic infections, Voriconazole.

Key Points

- Immunocompromised patients are at higher risk of developing atypical soft tissue infections caused by less common pathogens such as aerobic gram-negative bacilli and fungi that may be resistant to standard cellulitis treatment.
- *Scedosporium spp.* are emerging as a cause of serious fungal infections with high mortality rates in immunocompromised individuals.
- Voriconazole is the first-line treatment for Scedosporiosis but requires prolonged courses of treatment with close monitoring to detect and prevent adverse effects and interactions with other medications.

Gary Peter Misselbrook
MBBS, MRCP(UK), PgDip (Med Tox),
ST4 Acute and General Internal Medicine and Intensive Care Medicine
Hampshire Hospitals NHS Foundation Trust

Patrick Lillie
MB ChB, MRCP, DTM&H, PhD,
Consultant in Acute Medicine and Infectious Diseases,
University Hospitals Southampton NHS Foundation Trust

Claire P Thomas
MRCP, FRCPath, DPhil OXON,
Consultant in Microbiology and Infectious Diseases
Hampshire Hospitals NHS Foundation Trust

Correspondence:
Gary Peter Misselbrook
Hampshire Hospitals NHS Foundation Trust
Email: garymisselbrook@doctors.org.uk

Introduction

In the past few years intravenous outpatient antibiotic therapy (OPAT) for cellulitis has expanded rapidly as a result of the recognition of its significant benefits to local healthcare services and patients.[1] However, OPAT involves less supervision than inpatient care and patients are often managed by acute medicine trainees and nurses without a specialist knowledge of infectious diseases. As IV OPAT services continue to develop, the acute medical doctor should be familiar with potential pathogens that may cause cellulitis in those patients not responding to antibiotics.

In the following article we describe two cases seen in our acute medical unit presenting from primary care with a cellulitis not responding to antibiotic therapy. In both instances an unusual but serious and emerging fungal infection *Scedosporium* was diagnosed from swabs sent for microscopy and culture.

Case 1

An 81-year-old man was referred by his GP to the ambulatory care unit with a two-week history of right arm cellulitis starting after sustaining a deep skin abrasion whilst gardening. Three months prior to the development of cellulitis he had been diagnosed with presumed giant cell arteritis and started on high-dose prednisolone (60mg/day). He had a history of Type 2 Diabetes that was previously well controlled but since starting steroids his control had deteriorated. His GP had been able to wean the steroids to 40mg daily on rheumatology advice and the patient was due to commence insulin therapy at the time of his referral to AMU. Other past history included hypertension, chronic kidney disease stage III, ischaemic heart disease with previous coronary artery bypass grafting and chronic obstructive pulmonary disease (COPD).

On examination there was evidence of a significant right forearm cellulitis with crusting, erythema and pustular nodules worst over the dorsum of the right hand (Figure 1 and 2). The patient was systemically well with no fever or constitutional symptoms. He was given Ceftriaxone 2g IV and swabs were taken from discharging nodules for microscopy and culture. Despite the dramatic appearances of his forearm, he felt systemically well and was keen to return home to care for his wife. He was therefore discharged with oral flucloxacillin 1g QDS and an appointment was

© 2016 Rila Publications Ltd.



Figure 1. Supparative nodules and ulcers on the dorsum of the hand.



Figure 2. Typical lymphangitic pattern of *Scedosporium* soft tissue infection in our patient.

made to review progress in the IV OPAT clinic in seven days.

On review the following week, despite completing the full course of antibiotics, there was still evidence of significant soft tissue infection. The microbiology laboratory contacted the department with the result of swabs identifying the pathogen as *Scedosporium apiospermum*. The patient was started immediately on voriconazole 400mg BD for one day, then 200mg BD thereafter and referred to the infectious disease clinic for ongoing follow up. Unfortunately he was readmitted after two weeks with rising CRP and deteriorating renal disease, attributed to worsening cellulitis. During his inpatient stay he received a transthoracic echocardiogram revealing good biventricular function and a CT scan of his chest, abdomen and pelvis that did not demonstrate any evidence of disseminated disease or thromboembolism. His treatment was unchanged and his condition progressively settled enabling discharge from hospital within 1 week.

Four months on, his fungal disease was greatly improved with only some residual nodularity and further scans confirmed no evidence of bony involvement. Six months of oral antifungal treatment was completed and the patient appeared disease free. Unfortunately further nodularity developed after a month off voriconazole, requiring further antifungal therapy.

Case 2

A 92 year old man was referred by his GP to the Acute Medical Unit with a 2 week history of non-healing, infected wound over the dorsum of his left hand that was sustained after knocking it against a kitchen appliance during a fall. The infected wound had failed to respond to a week course of oral antibiotics and whilst the patient was systemically well on admission, his wound was deteriorating rapidly. The patient had a past medical history of Non-Hodgkin's Lymphoma (currently in remission) and was on dexamethasone 2mg OD for control of metastatic prostate cancer. He was independent and lived in his own house with some support from his family.

The local microbiology team contacted the GP to suggest admission for specialist review of the wound after *Scedosporium* species were isolated from a swab taken in the GP surgery. On examination there was a deep, purulent 5x3cm wound over the dorsum of the left hand with extension to extensor tendons. On further examination the patient had a non-tender nodular swelling to the medial aspect of the left elbow and multiple ecchymoses to the right arm.

The patient was started on Voriconazole 200mg BD orally and IV Piperacillin-Tazobactam was commenced to cover for bacterial co-infection. An X-ray of the hand initially showed no evidence of osteomyelitis and a surgical opinion was sought to assess if tendon or bone involvement was present. Due to significant and deep soft tissue damage the patient was transferred to our regional plastic surgery centre where he underwent extensive local debridement. Samples taken from bone and soft tissues grew *Scedosporium apiospermum*. His admission was complicated by the development of a hospital-acquired pneumonia and CNS toxicity secondary to elevated voriconazole levels. Unfortunately despite treatment with voriconazole and clearance of *Scedosporium* on repeating deep wound swabs, the patient developed disseminated disease and died five weeks after admission to our Acute Medical Unit.

Discussion

BMJ Best Practice guidance states that, in patients not responding to typical IV antibiotic therapy, one should consider infection with resistant

© 2016 Rila Publications Ltd.

strains of organisms, extension to deeper tissues (i.e. necrotising fasciitis), abscess formation or an alternative diagnosis. In the cases described, both patients were immunocompromised secondary to long-term steroid use therefore less common pathogens such as aerobic gram-negative bacilli and fungi were possible causes.[2]

During the last few decades, opportunistic fungal pathogens have become increasingly recognised as a cause of infection in immunosuppressed patients. In our cases the pathogen was identified as a Scedosporium species (specifically *S. apiospermum*). Diseases in humans are caused predominantly by *S. apiospermum* and *S. prolificans*. These species are found ubiquitously in the environment, including within soil and polluted water. Skin infections often result from the direct inoculation of fungal matter through skin puncture and occasionally by haematogenous spread in disseminated infections.[3]

Localised skin infections with *S. apiospermum* may present as solitary ulcers, infiltrative erythematous plaques and nodules, or – in the case of our patients – supparative nodules and ulcers in a lymphangitic pattern. Scedosporium species are also a cause of mycetoma; an implantation mycosis causing a destructive, progressive granulomatous tumour. More commonly seen in the developing world, these appear as nodular painless lesions that spontaneously drain purulent material mixed with yellowish grains resembling fig seeds. Constitutional symptoms are rarely seen unless secondary infection with another organism occurs.[3]

Previous case reports in the literature describe similar modes of inoculation as our cases with trauma from a blackcurrant bush,[4] intravenous cannula infection,[5] and abrasions of skin[5] all described. Diagnosis of *Scedosporium spp.* is confirmed on culture of microbiological samples from deep tissue swabs (Figure 3). To ensure appropriate tests are performed, and to ensure every opportunity is taken to identify fungal pathogens, AMU doctors should be conscious of the importance of giving infection doctors as much information as possible on the clinical requests. Decent microbiological samples also allow for testing in vitro susceptibility to antifungal agents, which is vital due to the resistance of many *Scedosporium spp.* to multiple agents.[6]

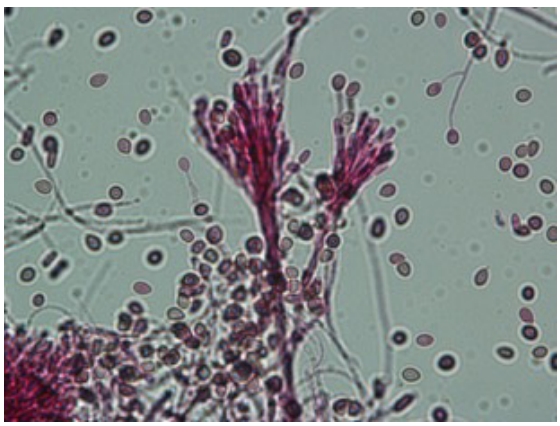

Figure 3. Lactofuchsin stain viewed under x40 objective showing typical elongated annellides and oval conidia with a scar at the base. (Courtesy of Dr Elizabeth M. Johnson, Director PHE Mycology Reference Laboratory).

Choice of antifungal agents should be guided by in vitro susceptibility testing in *Scedosporium* infection due to the intrinsic resistance to amphotericin B and variable resistance to conventional azoles.[7] Extended-spectrum azoles (such as voriconazole) have been found to have the lowest minimum inhibitory concentration (MIC – the minimum concentration required to inhibit growth of the organism) against *S. apiospermum* whilst *S. prolificans* is resistant to the majority of antifungal agents. An experimental triazole – albaconazole – has shown some promise in vitro, but is not currently available for clinical use.[8] Our cases were no exception; the isolates of *S. apiospermum* were sensitive to voriconazole and itraconazole, but only partially sensitive to posaconazole.

The outlook for patients even with only local disease secondary to 'Scedosporiosis' is poor with a high incidence of disseminated disease and mortality rates of between 40-100% are quoted in the literature.[9,10] Disseminated disease secondary to *S. prolificans* is invariably fatal. The largest retrospective review of scedosporium treatment involved 107 patients given voriconazole monotherapy. A successful response was seen in only 57% of patients after a median of 103 days of therapy, with sufferers of malignancy and haemopoetic cell transplant recipients having the worst prognosis.[10] Features found to represent a better chance of disease resolution include immunological recovery of the patient and the ability to debride infected soft tissue.

Often the most challenging aspect of treating Scedosporiosis is the management of voriconazole dosing and its adverse effects. Azoles are potent inhibitors of CYP450 enzymes and close attention should be paid to other medications the patient may be prescribed. Due to genetic polymorphism of CYP2C19, voriconazole concentration is on average 2-4 fold higher in CYP2C19 poor metabolisers (PM) than in extensive metabolisers (EM). This is an especially important consideration in patients with HIV/AIDS who may be taking highly-active anti-retroviral therapy (HAART), where interactions with certain medications may cause a reduction in voriconazole levels in patients who are CYP2C19-EMs, or significant increase in levels if CYP2C19-PMs.[11]

© 2016 Rila Publications Ltd.

As a general rule, patients should be started on Voriconazole 200mg BD orally and serum drug levels (trough-levels) should be taken five to seven days later and then checked once weekly during the initial stages of treatment. There is no official consensus on target trough levels, although it has been suggested to aim for levels of between 1-5.5mcg/mL.[12] In our second case, the patient developed toxicity from voriconazole treatment manifested as acute confusion at which time trough-levels were found to be 8mcg/mL. Neurological adverse effects such as encephalopathy are typical, with visual disturbances – such as blurred vision or increased sensitivity to light – unique to voriconazole therapy. Voriconazole is phototoxic and therefore patients should be advised to avoid prolonged exposure to sunlight whilst on therapy.[13] Hepatitis, cholestasis, and fulminant hepatic failure are reported uncommonly. The risk is increased in patients with a history of haematological malignancy therefore it is vital to monitor liver function before starting treatment, then at least weekly for one month, and then monthly during treatment.[14]

Conclusion

As the prevalence of outpatient clinics managing treatment of cellulitis increases, acute medical doctors should have an awareness of the uncommon but serious pathogens causing soft tissue infection that may not respond to standard antimicrobial therapy. Scedosporiosis is a serious and emerging fungal disease in immunocompromised individuals with poor outcomes and a need for aggressive treatment with antifungal therapy. Close monitoring of treatment and a multidisciplinary approach with infection doctors and surgical colleagues is vital to increase the chances of disease resolution.

Acknowledgements

Many thanks to Dr Elizabeth M. Johnson, Director PHE Mycology Reference Laboratory, Public Health England for images and advice regarding these cases, and Dr Stephen Cotterill, Consultant Microbiologist, Salisbury NHS Foundation Trust for his updates on the progress of our second case.

Conflict of interest

Nothing to declare.

References

1. Chapman ALN, Seaton RA, Cooper MA, *et al.* Good practice recommendations for outpatient parenteral antimicrobial therapy (OPAT) in adults in the UK: a consensus statement. *J Antimicrob Chemother.* 2012; **67(5):** 1053–62
2. British Medical Journal. *Cellulitis – Treatment – Step-by-step.* Available at: http://bestpractice.bmj.com/best-practice/monograph/63/treatment/step-by-step.html (Accessed 23 August 2015)
3. Cortez KJ, Roilides E, Quiroz-Telles F, *et al. Infections Caused by Scedosporium spp. Clin Microbiol Rev.* 2008: **21(1):** 157–197
4. Bower CPR, Oxley JD, Campbell CK, *et al.* Cutaneous *Scedosporium apiospermum* infection in an immunocompromised patient. *J Clin Pathol.* 1999; **52:** 846–48
5. Bosma F, Voss A, van Hamersvelt HW, *et al.* Two cases of subcutaneous *Scedosporium apiospermum* infection treated with voriconazole. *Clin Microbiol Infect.* 2003; **9:** 750–753
6. Castiglioni B, Sutton DA, Rinaldi MG, *et al. Pseudoallescheria boydii* infection in solid organ transplant recipients in a tertiary medical center and review of the literature. *Medicine (Baltimore).* 2002; **81(5):** 333–48
7. Cuenca-Estrella M, Gomez-Lopez A, Mellado E, *et al.* Head-to-head comparison of the activities of currently available antifungal agents against 3,378 Spanish clinical isolates of yeasts and filamentous fungi. *Antimicrob Agents Chemother.* 2006; **50(3):** 917–21
8. Carrillo AJ, Guarro J. In vitro activities of four novel triazoles against *Scedosporium spp. Antimicrob Agents Chemother.* 2001; **45(7):** 2151–3
9. Husain S, Muñoz P, Forrest G, *et al.* Infections due to *Scedosporium apiospermum* and *Scedosporium prolificans* in transplant recipients: clinical characteristics and impact of antifungal agent therapy on outcome. *Clin Infect Dis.* 2005; **40(1):** 89–99
10. Troke P, Aguirrebengoa K, Arteaga C, *et al.* Treatment of scedosporiosis with voriconazole: clinical experience with 107 patients. *Antimicrob Agents Chemother.* 2008; **52(5):** 1743–50
11. Zhu L, Uy J, Bruggemann R, *et al.* CYP2C19 genotype-dependent pharmacokinetic drug interaction between voriconazole and ritonavir boosted atazanavir in healthy subjects. 13th International Workshop on Clinical Pharmacology of HIV Therapy, Barcelona, April 2012, Abstract: O_08
12. Pascual A, Calandra T, Bolay S, *et al.* Voriconazole therapeutic drug monitoring in patients with invasive mycoses improves efficacy and safety outcomes. *Clin Infect Dis.* 2008; **46(2):** 201–11
13. Epaulard O, Saint-Raymond C, Villier C *et al.* Multiple aggressive squamous cell carcinomas associated with prolonged voriconazole therapy in four immunocompromised patients. *Clin Microbiol Infect.* 2010; **16(9):** 1362–1364.
14. BMJ Group and the Royal Pharmaceutical Company of Great Britain. Medicines Complete – Voriconazole. Available at: https://www.medicinescomplete.com/mc/bnf/current/PHP3709-voriconazole.htm (Accessed 27 September 2015)

© 2016 Rila Publications Ltd.